



The Migration of an Intrauterine Device in the Bladder of an Asymptomatic Woman: A Case Report

Seyedeh Azam Pourhoseini, Leili Hafizi, Mona Jafari *

- Department of Obstetrics and Gynecology, Faculty of Medicine, Mashhad University of Medical Sciences, Mashhad, Iran

Abstract

Background: The use of intrauterine devices (IUDs) for contraception has increased in many countries. However, their application has some serious complications such as uterine perforation and injury to adjacent organs. The translocated IUD into the bladder is a very rare occurrence.

Case Presentation: Our case was a 41-year-old woman whose IUD was accidentally discovered in her bladder during a routine ultrasound. The IUD has migrated from its normal position in the uterus to the bladder. The IUD was successfully removed by cystoscopy without any complications.

Conclusion: The mislocation of an IUD in the bladder, while uncommon, is a possibility that should be considered when the IUD string is not visible during examinations.

Keywords: Contraceptive agents, Contraceptive devices, Intrauterine device, IUD migration, Uterine perforation.

To cite this article: Pourhoseini SA, Hafizi L, Jafari M. The Migration of an Intrauterine Device in the Bladder of an Asymptomatic Woman: A Case Report. *J Reprod Infertil.* 2024; 25(3):238-241. <https://doi.org/10.18502/jri.v25i3.17019>.

* Corresponding Author:
Mona Jafari, Department of
Obstetrics and Gynecology,
Faculty of Medicine,
Mashhad University of
Medical Sciences, Mashhad,
Iran
E-mail:
JafariM4001@mums.ac.ir

Received: 12, Feb. 2024

Accepted: 8, Jul. 2024

Introduction

Intrauterine devices (IUDs) are a frequently used reversible form of contraception (1). It was used by approximately 14% of women due to its efficacy, safety, and low cost (2). IUD is usually placed without any significant complication. However, as with any medical foreign object, there are several possible drawbacks. Hemorrhage, infection, device migration, uterine rupture, dislocation, and expulsion are reported as complications of IUD. Of these potential complications, uterine perforation tends to receive the most attention.

Uterine perforation can occur during the initial placement of an IUD. Over time, erosion of the uterine wall can also lead to perforation. This condition is reported to occur in 0.5-1 cases per 1,000 IUD insertions (3).

Following the uterine rupture, an IUD may potentially migrate to the pelvic or intra-abdominal cavity, which causes several problems. There are numerous reports in the literature documenting

cases of IUD migration away from the intended placement site within the uterus.

A literature review covering 18 years until 1999 identified 165 reported cases of IUD migration, indicating that migration to the bladder is relatively uncommon and has only been reported in 31 cases (4). In this study, a patient who was referred to our hospital with a migrated IUD in the bladder was reported.

Case Presentation

The patient was a 41-year-old woman who was referred to Imam Reza Hospital for IUD removal in September 2022. The IUD was inserted after the birth of her third child, approximately 12 years ago in 2010. However, the patient became pregnant unintentionally 3 months after inserting the IUD. When examined in the clinic, the IUD string was not visible. Investigations and ultrasounds failed to locate the IUD, leading the patient and physician to believe that it was spontaneously ex-

pelled. The patient delivered her baby without any complications. One year following the birth, the patient tried to use the IUD again as a contraception.

Eight years after the second IUD was placed (October 2022), the patient underwent a pelvic ultrasound following routine tests and the discovery of pyuria in the urine test. The findings of the patient's ultrasound are as follows; the ultrasound revealed an echogenic linear structure measuring 28 mm protruding from the anterior wall of the bladder into the lumen, suggestive of a foreign body or a bladder wall septum secondary to lobulation (Figure 1).

The patient did not complain of dysuria, hematuria, or pelvic pain. Ultrasound findings were also confirmed by computed tomography scans (CT scan) (Figure 2).

Cystoscopy was performed at Imam Reza University Hospital under general anesthesia using the Olympus system with a 2.9 mm lens and a 30 degree angle. The IUD was observed adhering to the bladder wall, with a stone deposit visible on it. The IUD was easily removed with a cystoscope grasper. No evidence of fistula or additional stones was found on the repeat cystoscopy (Figure 3).

In hysteroscopy, a second IUD was observed inside the uterus, which was removed with a grasper, and the uterine cavity appeared normal. Six hours after the operation, the patient was dis-

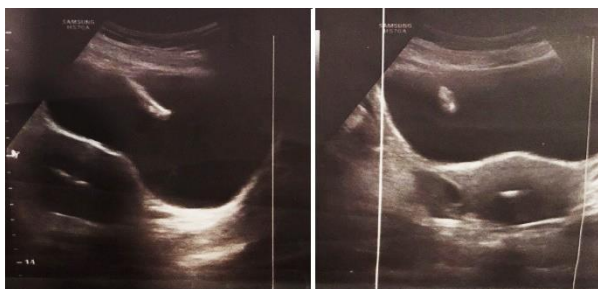

Figure 1. Ultrasound image showing IUD in uterus and bladder

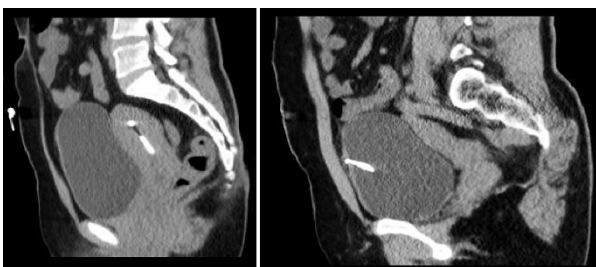


Figure 2. CT scan showing IUD in the bladder and uterus

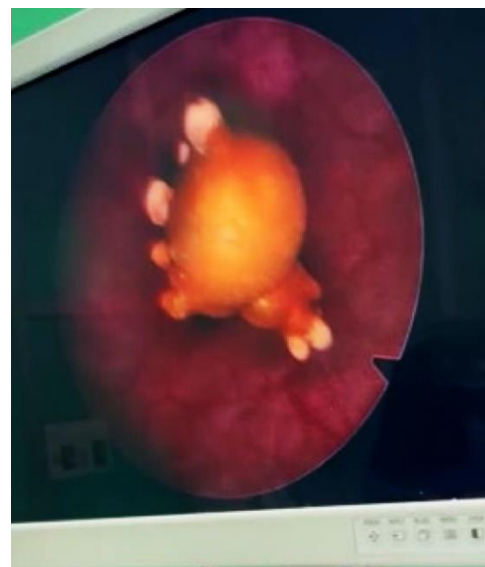

Figure 3. Cystoscopic view of the migrated intrauterine device (IUD)

charged. During the 1-month and 3-month follow-up visits, the patient had no symptoms or complaints.

Discussion

An intrauterine device is a common widely used form of mechanical contraception. More than 150 million women use IUDs, predominately in developing countries (1). Uterine perforation, malignant transition, and migration into neighboring structures are the most serious complications of an IUD insertion (5).

Potential mechanisms behind IUD migration include uterine perforation at the time of insertion, uterus/bladder contractions, gastrointestinal peristalsis, and peritoneal fluid movement. Important risk factors for uterine perforation include insertion by inexperienced persons, uterine size and position, inherent anatomic variation, and recent abortion or pregnancy (6). Uterine perforation by an IUD may basically occur via two mechanisms. First, perforation can happen at the time of placement, primarily due to misplacement, which may present with bleeding, acute pelvic pain, or loss of the IUD's thread. The experience of the IUD insertion provider and placement by specialists are extremely important factors in preventing misplacement, as supported by numerous authors. The second mechanism is gradual and spontaneous perforation of the uterine wall over time after IUD insertion, known as uterine migration. This

can lead to the development of late-onset symptoms or may be entirely asymptomatic (7).

The design and structural characteristics of the IUD, as well as the nature and rigidity or plasticity of the device, are considered IUD-related factors that may contribute to perforation (6). Uterine perforation related to IUD placement can occur shortly after the procedure or as a delayed event. It is widely recommended that IUDs be inserted following proper patient selection and by trained clinicians (5).

Uterine perforation may be asymptomatic or cause pain, abnormal bleeding, bowel or bladder perforation, or fistula formation (13). Possible sites of IUD migration include the bladder (intravesical), peritoneum, omentum, rectosigmoid, appendix, small bowel, colon, adnexa, and iliac vein (8). Intravesical migrated IUDs may result in bladder perforation, stone formation, or malignant transition (9). Uterine examination, a transvaginal ultrasound, abdominal ultrasound, a kidney, ureter, and bladder (KUB) X-ray, and pelvic CT are useful for determining the location of a migrated IUD. In particular, CT is useful for diagnosing whether the IUD is penetrating surrounding organs (10).

The World Health Organization (WHO) recommends removing the migrated device in the a timely manner (11). It is suggested that surgical removal should be considered even in asymptomatic patients once it has migrated out of the uterus. The recommendation is to use minimally invasive methods if possible, including hysteroscopy, cystoscopy, colonoscopy, or laparoscopy, depending on where the IUD is located. If the device is embedded in an organ such as the bladder or bowel, it is not recommended to remove it using minimally invasive methods. Instead, an exploratory laparotomy should be performed (12). In the case of this patient, the use of cystoscopy was sufficient to diagnose and remove the migrated IUD.

Conclusion

Regular follow-up visits and examinations immediately after IUD insertion and periodic check-ups, could help prevent IUD misplacement, migration, and other complications.

If the IUD string is not visible during the pelvic examination, further investigation with imaging methods such as an abdominal x-ray (AP view) and ultrasound is recommended. In such cases, it is advisable for the radiologist to examine the

uterus and explore the adjacent organs such as the bladder, intestine, and pelvis to assess for potential uterine perforation and migration of the IUD to these areas.

Conflict of Interest

The authors declare that they have no conflicts of interest.

References

1. Nouioui MA, Taktak T, Mokadem S, Mediouni H, Khiari R, Ghozzi S. A mislocated intrauterine device migrating to the urinary bladder: an uncommon complication leading to stone formation. *Case Rep Urol.* 2020;2020:2091915.
2. Paré AK, Ouattara A, Yé D, Kabré B, Bako A, Abubakar B, et al. Management of intrauterine device migrated into the bladder: a case report and literature review. *Case Rep Urol.* 2020;2020:8850087.
3. Mona A, Tardif D, Fawzy A, Socolov RV. Management of an intrauterine device migration resulting in a pregnancy—clinical case. *Maedica (Bucur).* 2020;15(4):549-51.
4. Rasekhjahromi A, Chitsazi Z, Khlili A, Babaarabi ZZ. Complications associated with intravesical migration of an intrauterine device. *Obstet Gynecol Sci.* 2020;63(5):675-8.
5. Aydogdu O, Pulat H. Asymptomatic far-migration of an intrauterine device into the abdominal cavity: a rare entity. *Can Urol Assoc J.* 2012;6(3):E134-6.
6. Sano M, Nemoto K, Miura T, Suzuki Y. Endoscopic treatment of intrauterine device migration into the bladder with stone formation. *J Endourol Case Rep.* 2017;3(1):105-7.
7. Azandaryani AR, Ghaderzadeh P, Farsangi LE. Intravesical migration of intrauterine device and calculi formation 12 years post missing: a case report. *Case Rep Clin Med.* 2017;6(1):24-30.
8. Christodoulides AP, Karaolides T. Intravesical migration of an intrauterine device (IUD)-case report. *Urology.* 2020;139:14-7.
9. Zhang P, Wang T, Yang L. Extensive intravesical benign hyperplasia induced by an extravesical migrated intrauterine device: a case report. *Medicine (Baltimore).* 2019;98(20):e15671.
10. Raj A, Xiaolei S, Wenjing X, Renfu C, Yunpeng P. A sandwich technique for the removal of stone embedded intrauterine devices in the urinary bladder. *Urol Case Rep.* 2021;38:101599.
11. Chakir Y, Daghdagh Y, Moataz A, Dakir M, Debbagh A, Aboutaieb R. Intra uterine device

migrating into the bladder with stone formation. *Urol Case Rep.* 2022;40:101918.

12. Cheung ML, Rezai S, Jackman JM, Patel ND, Bernaba BZ, Hakimian O, et al. Retained intra-uterine device (IUD): triple case report and review

of the literature. *Case Rep Obstet Gynecol.* 2018; 2018:9362962.

13. Verstraeten V, Vossaert K, Van den Bosch T. Migration of intra-uterine devices. *Open Access J Contracept.* 2024;15:41-7.