



Assisted Reproductive Technology Outcomes After Ethanol Sclerotherapy in Poor Responder Patients with Endometriomas: A Before-After Clinical Trial

Farah Ghasemi ^{1*}, Ladan Kashani ¹, Ashraf Moini ^{2,3,4}, Maryam Farid Mojtahedi ¹, Roza Shahhosseini ¹, Farzaneh Alemohammad ¹

1- Department of Obstetrics and Gynecology, Arash Women's Hospital, Tehran University of Medical Sciences, Tehran, Iran

2- Department of Obstetrics and Gynecology, Endocrinology and Female Infertility Unit, Arash Women's Hospital, Tehran University of Medical Sciences, Tehran, Iran

3- Department of Endocrinology and Female Infertility, Reproductive Biomedicine Research Center, Royan Institute for Reproductive Biomedicine, ACECR, Tehran, Iran

4- Breast Disease Research Center (BDRC), Tehran University of Medical Sciences, Tehran, Iran

Abstract

Background: The purpose of the present study was to investigate the assisted reproductive technology (ART) outcomes after ethanol sclerotherapy (EST) in poor responder patients with endometriomas.

Methods: In this before-after clinical trial, the outcomes of ART of 31 poor responders with endometriomas were evaluated after EST between July 2023 to March 2024. These patients had undergone ART at least in one cycle before and did not respond well. Recurrence rate, antral follicle count (AFC), anti-Müllerian hormone (AMH), and relief of symptoms including dysmenorrhea and abnormal uterine bleeding (AUB) were evaluated before the procedure. Follow-up assessments were conducted two and six weeks after the procedure for evaluating the complications. Fisher's exact test, chi-square test, and paired sample t-test were used for statistical analysis using SPSS 24.

Results: In this study, the levels of AFC and AMH increased significantly after endometrioma stripping therapy ($p < 0.05$). Additionally, the number of embryos obtained increased significantly, indicating potential improvement in oocyte quality. There was a significant reduction in pelvic pain scores ($p = 0.001$), as well as a notable decrease in dysmenorrhea ($p = 0.02$) and dyspareunia ($p = 0.001$). Moreover, 16.12% of patients reported recovery from intermenstrual bleeding. However, no significant difference was observed in the amount of gonadotropin used ($p = 0.56$).

Conclusion: EST is an appropriate and safe procedure before ART for poor responders who have endometriomas and can be a replacement for surgery among selected patients.

Keywords: ART outcome, Ethanol sclerotherapy, Endometriomas.

To cite this article: Ghasemi F, Kashani L, Moini A, Farid Mojtahedi M, Shahhosseini R, Alemohammad F. Assisted Reproductive Technology Outcomes After Ethanol Sclerotherapy in Poor Responder Patients with Endometriomas: A Before-After Clinical Trial. *J Reprod Infertil.* 2024;25(3):224-230. <https://doi.org/10.18502/jri.v25i3.17017>.

* Corresponding Author:
Farah Ghasemi, Department
of Obstetrics and
Gynecology, Arash
Women's Hospital, Tehran
University of Medical
Sciences, Tehran, Iran
E-mail:
mahsamoshiri00@gmail.
com

Received: 6, Jun. 2024

Accepted: 1, Oct. 2024

Introduction

Endometriosis is a chronic gynecologic disorder predominantly affecting women of reproductive age (1, 2). It is characterized by the presence of endometrial glands and stroma outside the uterus, which commonly occur in the

ovaries, cul-de-sac, intestine, and peritoneum. This condition is often associated with pelvic pain and infertility (2, 3). Endometriosis typically presents in three forms: superficial peritoneal lesions, deep infiltrating endometriosis, and ovarian en-

ometrioma (OMA) (4).

The significance of studying endometriosis lies in its prevalence, as approximately 25%-40% of infertile women are affected, most of whom have ovarian endometriomas. An endometrioma is an ovarian cyst lined with endometrial tissue, filled with fluid that accumulates from menstrual debris (5, 6). The presence of OMAs correlates with advanced stages of endometriosis (stages 3 and 4), according to the American Society for Reproductive Medicine (ASRM) classification (7). Despite ongoing research, the etiology and management of endometriosis remain contentious, although factors such as genetics, immunity, environmental influences, and chronic inflammation are believed to contribute to its pathogenesis (8-10). The tissue surrounding an endometrioma often undergoes destruction, losing its typical follicular structure. Additionally, dysfunctional peritoneal macrophages in patients with endometriosis secrete proteinases that damage ovarian tissue and diminish its reserve (11). Mechanically, OMAs inhibit proper follicular growth and response to hormonal stimulation by reducing blood supply to the follicles. Furthermore, cytokines and inflammatory mediators in the peritoneal cavity contribute to fibrosis, a reduction in cortex-specific stromal cells, vascular defects, and overall loss of ovarian function (12, 13).

Current treatment options for infertile women with endometriomas are limited, as they do not generally benefit from medical therapies (14). Surgical intervention, particularly laparoscopy and excision of endometriotic lesions, is favored over ablation to alleviate pain and restore reproductive anatomy. However, these procedures can inadvertently remove or damage healthy ovarian tissue adjacent to the cystic wall, leading to a decline in ovarian function due to reduced ovarian reserve (15-17). The pseudocapsule surrounding ovarian endometriomas complicates surgical excision, risking injury to both endometrial tissue and normal ovarian tissue (18, 19). Local inflammation and vascular injury, exacerbated by anticoagulant use, may further compromise ovarian reserve (20). Consequently, surgical excision of OMAs as a first-line treatment can significantly impair ovarian reserve and oocyte retrieval in IVF procedure (21).

Given the association between endometriomas and diminished response to ovarian stimulation in IVF cycles, exploring conservative management strategies with fewer complications and lower

costs is imperative for palliative care (22). Leaving OMAs in situ may lead to inadequate response during controlled ovarian hyperstimulation (COH) or incomplete aspiration, resulting in fewer retrieved oocytes. Notably, cystectomy prior to IVF does not enhance fertility outcomes (23). Non-surgical management options for OMAs, such as aspiration or endoscopic sclerotherapy treatment, have gained attention. This approach involves the injection of sclerosing agents like alcohol or methotrexate into the endometrioma, aiming to disrupt the cyst wall epithelium, induce inflammation, and promote fibrosis, ultimately obliterating the cyst cavity (24, 25). This method has proven to be beneficial and cost-effective for reproductive-age women experiencing pain and infertility who are unsuitable candidates for traditional medical or surgical treatments (26).

In this study, ART outcomes were evaluated in poor responder patients with endometriomas following EST, while pelvic pain and recurrence rates before and after the procedure were compared.

Methods

This before-after clinical trial was conducted from July 2023 to March 2024, including endometriosis patients referred to Arash Hospital, affiliated with Tehran University of Medical Sciences (TUMS). The study was approved by the TUMS Institutional Review Board (Approval Code: No 59326) and received ethical clearance (Code: IR.TUMS.MEDICINE.REC.1401.555; IRCTID: IRCT20110731007165N12).

To determine the sample size, the average reduction from 9.1 ± 0.71 in the third month to 8.73 ± 0.78 in the twelfth month was used, based on the study by Alborzi et al. (2). Taking into account a 10% drop in the sample, the required sample size was also calculated based on a correlation coefficient of 55%, resulting in a final sample of 31 individuals. This was determined through the confirmation of endometriomas via transvaginal ultrasound (Philips Affiniti 70 Ultrasound System; Philips, USA) and prior poor response in at least one IVF cycle.

Inclusion criteria included poor responder patients aged under 42 years with an AFC ≤ 5 in both ovaries, and endometriomas measuring between 4 cm and 10 cm, who had undergone at least one IVF cycle. Exclusion criteria included patients with a body mass index (BMI) ≥ 30 kg/m², endometriomas greater than 10 cm, a history of pelvic

infection or abscess post-HSG or SIS, polycystic ovary syndrome (PCOS), severe male factor infertility, or other underlying health issues.

Patients received detailed information regarding the procedure, its advantages, and potential risks. Informed consent was obtained from all participants before the study commenced. Relevant information including age, surgical history, type of infertility (primary or secondary), unilaterality or bilaterality of OMAs, pain intensity, tumor marker levels for malignancy suspicion, as well as AMH and FSH levels were recorded.

Patients were admitted in the morning of the procedure. Under general anesthesia in the lithotomy position, sedation was achieved with intravenous Propofol (Fresenius Kabi, Austria) and Fentanyl (Darou Pakhsh Pharmaceutical Mfg. Co., Iran). The cyst contents were initially drained, and the cyst was then irrigated with a solution of 500 cc normal saline (sodium chloride 0.9%; Darou Pakhsh Pharmaceutical Mfg. Co., Iran), heparin (Alborzdarou Pharmaceutical Company, Iran), and cefazolin (Jaberebne Hayan Pharmaceutical Company, Iran). After ensuring cyst fluid clearance, alcohol (absolute ethyl alcohol 99.6%; Arak Petrochemical Company, Iran) was injected into the cyst, filling approximately 25% of the cyst volume, which was retained for the sclerosing effect.

Patients were monitored for 24 hr and received intravenous antibiotics: ceftriaxone (1 gr/BD) and metronidazole (500 mg TID). Discharge occurred the following morning if no complications, such as fever or pain, were present. Patients were prescribed cefixime (400 mg daily) and metronidazole (500 mg twice daily) for one week. Follow-up evaluations were scheduled for two and six weeks post-procedure to monitor for complications.

To minimize infection risk following EST, the long protocol commenced eight weeks after the procedure. Buserelin acetate, a GnRH agonist (Cinnafact 0.1 mg; CinnaGen Co., Iran), was administered on cycle day 21, followed by follitropin alfa (CinnaGen Co., Iran) at 300-450 IU daily starting on cycle day 2 of the next menstruation. Gonadotropin dosage adjustments were based on age, AMH levels, AFC, and follicular development, with monitoring via transvaginal ultrasound after 6-7 days. Triggering of final oocyte maturation occurred with HCG (Ovitrelle 250 µg/ml/0.5 ml; Merck, Germany) when 2-3 preovulatory follicles reached 17-18 mm.

Three-day or five-day frozen-thawed embryos were transferred two months after stimulation. Luteal phase support with progesterone (100 mg intramuscularly for 3 days) and then cyclogest suppository (400 mg daily) continued until week 10 if pregnancy occurred. Clinical pregnancy was confirmed through the observation of at least one intrauterine gestational sac.

Primary outcomes included the number of M2 oocytes and embryos obtained, while secondary outcomes comprised the amount of gonadotropins used and changes in the visual analog scale (VAS) scores for pelvic pain. Pain evaluation was conducted using the VAS scale at baseline, two weeks, and six weeks after the procedure. Recurrence was defined as the return of symptoms or reappearance of endometriomas on ultrasound during follow-up.

Statistical analyses were performed using SPSS V 24 (IBM, USA), with results expressed as mean±standard deviation (M±SD) for quantitative variables and frequency (percentage) for categorical variables. Fisher's exact test, chi-square test, and paired sample t-tests were employed, with p<0.05 considered statistically significant. The normality of data distribution was assessed using the Shapiro-Wilk test.

Results

The age of patients was 32.6±4.9 years, and BMI was 24.1 (2.4) kg/m². The mean follow-up duration was 6 months. The majority of participants reported primary infertility (67.7%) (Table 1). Among the 31 patients, two (6.5%) achieved spontaneous pregnancies following the procedure, leading to live births. One patient delivered vaginally at 34 weeks after experiencing premature rupture of membranes (PROM) one month post-

Table 1. The participant’s characteristics

Variables	Mean	SD
Age (years)	32.6	4.9
BMI (kg/m ²)	24.1	2.4
Infertility duration	2.9	3.23
Infertility type	Primary	67.7%
	Secondary	32.3%
Recurrence	Present	19.4%
	Absent	80.6%
Fertility rate	Yes	6.5%
	No	93.5%
Ongoing pregnancy	Yes	6.5%
	No	93.5%

Table 2. Mean and standard deviation of variables in patients before and after sclerotherapy

Variables	Before Mean±SD	After Mean±SD	Mean difference	p-value
AFC	4.9±2.1	9.1±3.6	4.2	<0.05
AMH	1.9±1.06	2.15±1.02	0.2	<0.05
OMA	68.03±19.15	36.33±15.04	-31.7	0.01
Gonadotropin	3581.5±3536.4	4105.9±5661.7	524.3	0.80
No of embryos retrieved	1.35±1.6	3.35±1.9	2	<0.05
Pain	4.94±2.47	3.32±2.02	-1.61	<0.05

EST, while the second underwent cesarean section at 38 weeks due to breech presentation after three months of unsuccessful embryo transfer. Additional patient characteristics are summarized in table 1.

Post-intervention, there were significant increases in Antral Follicle Count (AFC), Anti-Müllerian Hormone (AMH) levels, and the number of embryos retrieved, alongside significant decreases in ovarian endometrioma size and pelvic pain ($p \leq 0.05$) (Table 2). Furthermore, dysmenorrhea significantly decreased ($p=0.02$), as did dyspareunia ($p=0.001$) after the procedure. Notably, five patients (16.1%) reported recovery from intermenstrual bleeding. However, no significant difference was observed in the total amount of gonadotropin used during the stimulation cycle, with values before treatment averaging 3581.5 (SD=3536.4) and after treatment averaging 4105.9 (SD=5661.7) (Mean difference=524.3, $p=0.80$) (Figure 1).

Discussion

In the present study, the ART outcomes before and after EST were compared in poor responder patients who had at least one unsuccessful IVF. This approach allowed us to evaluate not only the ART outcomes but also the pain and recurrence of ovarian masses in this patient group. All patients had endometriomas ≥ 4 cm, categorizing them at least in stage 3 of endometriosis based on the ASRM classification. Previous research indicates that cystectomy for endometriomas does not improve IVF outcomes (18) and can lead to greater depletion of ovarian reserve (27); thus, surgical options are not advisable for this cohort. Our findings support this, as the use of ethanol induces cytotoxic damage, cell dehydration, and inflammatory mediator production, leading to anatomical distortion (28, 29).

In a systematic review and meta-analysis, Cohen et al. reported that the number of oocytes retrieved was higher after endometrioma EST compared to laparoscopic methods, although clinical pregnancy rates were similar. They found that the recurrence risk was significantly higher in patients treated with ethanol washing versus ethanol retention. They recommended EST for symptomatic patients who plan to conceive (30). Our study aligns with this recommendation and highlights the potential benefits of EST in preserving ovarian reserve.

Alborzi et al. found no significant differences in total oocyte retrieval, clinical pregnancy, or live birth rates between patients undergoing EST and those undergoing laparoscopic ovarian cystectomy. They suggested that ethanol EST is a viable alternative to surgery; however, the recurrence of the disease in this group is significantly higher

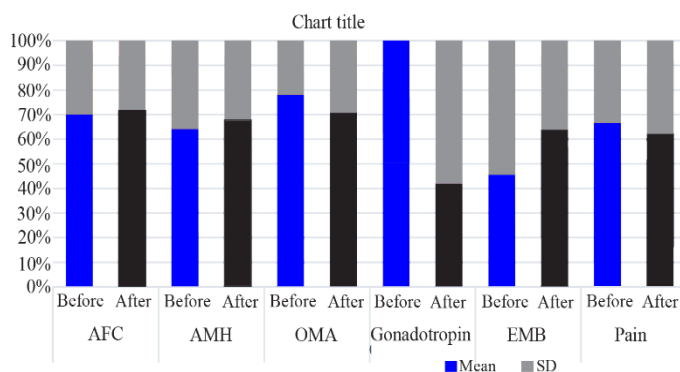


Figure 1. Comparison of the parameters before and after intervention

(31). This observation echoes our findings, particularly regarding the necessity of evaluating both the ART outcomes and the recurrence rates.

In another trial by Alborzi et al., they reported significant increases in AFC and reductions in pelvic pain among patients treated with EST. However, they noted no significant difference in AMH levels post-treatment. This contrasts with our findings of improved AFC and preserved ovarian reserve (32).

García-Tejedor et al. reported a 12% recurrence rate after 17 months of ethanol EST, with no serious complications noted (16). Other researchers indicated recurrence rates of 11.1% and 12.9% under varying conditions of ethanol application, illustrating the effectiveness of EST (33, 34). However, our study recorded a notably higher recurrence rate, potentially attributed to demographic differences and procedural variations. The size of the cysts remains a critical factor influencing recurrence.

Hsieh et al. demonstrated that retaining ethanol in cysts for a longer duration significantly reduced recurrence rates. Their results, which showed increased AFC and decreased pain levels, support our findings that EST effectively treats ovarian endometriosis (28).

Chang et al. reported significant decreases in cyst size and pain levels, along with a 23% recurrence rate (36). The differences in recurrence rates compared to our study may arise from their larger patient population, emphasizing the need for further research with larger sample sizes.

Miquel et al. highlighted the efficacy of EST in improving IVF success rates for women with moderate to severe endometriosis. They noted significant increases in clinical and biochemical pregnancy rates among those treated with EST, reinforcing the potential of this technique in enhancing ART outcomes (37).

In contrast, studies by Huang et al. (25) and Tehrani et al. (38) reported no significant changes in AMH levels following EST, suggesting a less invasive profile compared to laparoscopic interventions. Similarly, Lee et al. in their study reported insignificant decreases in AMH and EMB, which differ from our findings (39). These discrepancies could be attributed to variations in study design, methodology, and the specific EST techniques employed.

While our study presents valuable insights, several limitations must be acknowledged. The small

sample size, lack of a control group, and short follow-up period (9 months) restrict our ability to generalize the findings and draw definitive conclusions about the efficacy of EST. Additionally, the study did not adequately control for confounding variables such as age, duration of infertility, and endometrioma severity. Future research should address these limitations, incorporating larger cohorts and control groups to clarify the impact of EST on ART outcomes.

Conclusion

One of the strengths of our study was its design, which compared patients before and after the intervention, effectively eliminating a large group of confounding variables and leading to more precise results. The findings indicate that ovarian reserve was well-preserved in patients who underwent ethanol sclerotherapy (EST) for endometriomas, which may contribute to improved future fertility outcomes. Notably, there is currently no evidence that surgical treatment enhances the reproductive outcomes of women undergoing assisted reproductive technology.

However, our study had limitations, including a small sample size, lack of a control group, and a relatively short follow-up period of 9 months. These factors may restrict the generalizability of the findings to larger populations. Future studies should include a control group, a larger cohort of patients, and an extended follow-up duration to better assess the impact of EST on ART response rates and overall reproductive outcomes.

Acknowledgement

The present study was approved by the Institutional Review Board of Tehran University of Medical Sciences under the code number 59326, with the ethical approval code IR.TUMS.MEDICINE.REC.1401555 and IRCTID: IRCT20110-731007165N12. The authors would like to thank all those who assisted in performing this study, particularly the esteemed participants.

Conflict of Interest

The authors declare that they have no conflict of interest.

References

1. Jee BC. Efficacy of ablation and sclerotherapy for the management of ovarian Endometrioma: A narrative review. *Clin Exp Reprod Med.* 2022;49(2): 76-86.

2. Tsolakidis D, Pados G, Vavilis D, Athanatos D, Tsalikis T, Giannakou A, et al. The impact on ovarian reserve after laparoscopic ovarian cystectomy versus three-stage management in patients with endometriomas: a prospective randomized study. *Fertil Steril*. 2010;94(1):71-7.
3. Pais AS, Flagothier C, Tebache L, Almeida Santos T, Nisolle M. Impact of surgical management of endometrioma on AMH levels and pregnancy rates: a review of recent literature. *J Clin Med*. 2021;10(3):414.
4. Benaglia L, Somigliana E, Vighi V, Ragni G, Vercellini P, Fedele L. Rate of severe ovarian damage following surgery for endometriomas. *Hum Reprod*. 2010;25(3):678-82.
5. Gao X, Zhang Y, Xu X, Lu S, Yan L. Effects of ovarian endometrioma aspiration on in vitro fertilization-intracytoplasmic sperm injection and embryo transfer outcomes: a systematic review and meta-analysis. *Arch Gynecol Obstet*. 2022;306(1):17-28.
6. Tomassetti C, Adamson D, Arici A, et al. Endo-ART: a prospective randomized controlled trial on endometriomas in assisted reproductive technologies, comparing the effect of no intervention, surgery, and prolonged GnRH downregulation on pregnancy rates. *J Endometr Pelvic Pain Disord*. 2018;10(3):158-73.
7. Soliman M, Sisson B. What is sclerotherapy? What to expect and all else you need to know. Updated December 12, 2021. Available from: [<https://www.sciencedirect.com/science/article/pii/S0972978X2101288>].
8. Martinez-Garcia JM, Candas B, Suarez-Salvador E, Gomez M, Merino E, Castellarnau M, et al. Comparing the effects of alcohol sclerotherapy with those of surgery on anti-mullerian hormone and ovarian reserve after endometrioma treatment: a prospective multicenter pilot cohort study. *Eur J Obstet Gynecol Reprod Biol*. 2021;259:60-6.
9. Chen Y, Pei H, Chang Y, Chen M, Wang H, Xie H, et al. The impact of endometrioma and laparoscopic cystectomy on ovarian reserve and the exploration of related factors assessed by serum anti-Müllerian hormone: a prospective cohort study. *J Ovarian Res*. 2014;7:108.
10. Han MT, Cheng W, Zhu R, Wu HH, Ding J, Zhao NN, et al. The cytokine profiles in follicular fluid and reproductive outcomes in women with endometriosis. *Am J Reprod Immunol*. 2023;89(6):e13633.
11. Muñoz-Hernando L, Muñoz-Gonzalez JL, Marqueta-Marques L, Alvarez-Conejo C, Tejerizo-García Á, Lopez-Gonzalez G, et al. Endometriosis: alternative methods of medical treatment. *Int J Womens Health*. 2015;7:595-603.
12. Kalaitzopoulos DR, Samartzis N, Daniilidis A, Leeners B, Makieva S, Nirgianakis K, et al. Effects of vitamin D supplementation in endometriosis: a systematic review. *Reprod Biol Endocrinol*. 2022;20(1):176.
13. Leibetseder A, Schoeffmann K, Keckstein J, Keckstein S. Endometriosis detection and localization in laparoscopic gynecology. *Multimed Tools Appl*. 2022;81(5):6191-215.
14. Chapron C, Vercellini P, Barakat H, Vieira M, Dubuisson JB. Management of ovarian endometriomas. *Hum Reprod Update*. 2002;8(6):591-7.
15. Park HJ, Kim H, Lee GH, Yoon TK, Lee WS. Could surgical management improve the IVF outcomes in infertile women with endometrioma? *Obstet Gynecol Sci*. 2019;62(1):1-10.
16. García-Tejedor A, Castellarnau M, Ponce J, Eulalia F, Burdio F. Ethanol sclerotherapy of ovarian endometrioma: a safe and effective minimally invasive procedure. *Eur J Obstet Gynecol Reprod Biol*. 2015;18:25-29.
17. Kim GH, Kim PH, Shin JH, Nam IC, Chu HH, Ko HK. Ultrasound-guided sclerotherapy for the treatment of ovarian endometrioma: an updated systematic review and meta-analysis. *Eur Radiol*. 2022;32(3):1726-37.
18. Dunselman GA, Vermeulen N, Becker C, Calhaz-Jorge C, D'Hooghe T, De Bie B, et al. ESHRE guideline: management of women with endometriosis. *Hum Reprod*. 2014;29:400-12.
19. Sánchez AM, Viganò P, Somigliana E, Panina-Bordignon P, Vercellini P, Candiani M. The distinguishing cellular and molecular features of the endometriotic ovarian cyst: from pathophysiology to the potential endometrioma-mediated damage to the ovary. *Hum Reprod Update*. 2014;20:17-30.
20. Zhu W, Tan Z, Fu Z, Li X, Chen X, Zhou Y. Repeat transvaginal ultrasound-guided aspiration of ovarian endometrioma in infertile women with endometriosis. *Am J Obstet Gynecol*. 2011;204:61.e1-6.
21. Alborzi S, Ravanbakhsh R, Parsanezhad ME, Alborzi M, Alborzi S, Dehbashi S. A comparison of follicular response of ovaries to ovulation induction after laparoscopic ovarian cystectomy or fenestration and coagulation versus normal ovaries in patients with endometrioma. *Fertil Steril*. 2007;88(2):507-9.
22. Chan LY, So WW, Lao TT. Rapid recurrence of endometrioma after transvaginal ultrasound-guided aspiration. *Eur J Obstet Gynecol Reprod Biol*. 2003;109(2):196-8.
23. Donnez J, Nisolle M, Gillerot S, Anaf V, Clerckx-Braun F, Casanas-Roux F. Ovarian endometrial

- cysts: the role of gonadotropin-releasing hormone agonist and/or drainage. *Fertil Steril.* 1994;62(1):63-6.
24. Gonçalves FC, Andres MP, Passman LJ, Gonçalves MO, Podgaec S. A systematic review of ultrasonography-guided transvaginal aspiration of recurrent ovarian endometrioma. *Int J Gynaecol Obstet.* 2016;134(1):3-7.
 25. Huang L, Chang MY, Shiau CS, Hsieh TT. Changes in anti-Müllerian hormone after ultrasound-guided aspiration and ethanol sclerotherapy of ovarian cyst. *Taiwan J Obstet Gynecol.* 2021;60(3):509-51.
 26. Garcia-Tejedor A, Martinez-Garcia JM, Candas B, Suarez E, Manalich L, Gomez M, et al. Ethanol sclerotherapy versus laparoscopic surgery for endometrioma treatment: a prospective, multicenter, cohort pilot study. *J Minim Invasive Gynecol.* 2020;27(5):1133-40.
 27. Sukanuma N, Wakahara Y, Ishida D, Asano M, Kitagawa T, Katsumata Y, et al. Pretreatment for ovarian endometrial cyst before in vitro fertilization. *Gynecol Obstet Invest.* 2002;54 Suppl 1:36-40; discussion 41-2.
 28. Hsieh CL, Shiau CS, Lo LM, Hsieh TT, Chang MY. Effectiveness of ultrasound-guided aspiration and sclerotherapy with 95% ethanol for treatment of recurrent ovarian endometriomas. *Fertil Steril.* 2009;91(6):2709-13.
 29. Alborzi S, Zahiri Sorouri Z, Askari E, Poordast T, Chamanara K. The success of various endometrioma treatments in infertility: a systematic review and meta-analysis of prospective studies. *Reprod Med Biol.* 2019;18(4):312-22.
 30. Cohen A, Almong B, Tulandi T. Sclerotherapy in the management of ovarian endometrioma: systematic review and meta-analysis. *Fertil Steril.* 2017;108(1):117-24.e5.
 31. Alborzi S, Askary E, Keramati P, Alamdarloo SM, Poordast T, Ashraf MA, et al. Assisted reproductive technique outcomes in patients with endometrioma undergoing sclerotherapy vs laparoscopic cystectomy: prospective cross-sectional study. *Reprod Med Biol.* 2021;20(3):313-20.
 32. Alborzi S, Namavar Jahromi B, Ahmadbeigi M. Recovery rate of patients with recurrent ovarian endometriomas using sclerotherapy with 95% ethanol. *J Obstet Gynaecol Cancer Res.* 2018;3(3):105-10.
 33. Ikuta A, Tanaka Y, Mizokami T, Tsutsumi A, Sato M, Tanaka M, et al. Management of transvaginal ultrasound-guided absolute ethanol sclerotherapy for ovarian endometriotic cysts. *J Med Ultrason (2001).* 2006;33(2):99-103.
 34. Yazbeck C, Madelenat P, Ayel JP, Jacquesson L, Bontoux LM, Solal P, et al. Ethanol sclerotherapy: a treatment option for ovarian endometriomas before ovarian stimulation. *Reprod Biomed Online.* 2009;19(1):121-5.
 35. Noma J, Yoshida N. Efficacy of ethanol sclerotherapy for ovarian endometriomas. *Int J Gynaecol Obstet.* 2001;72(1):35-9.
 36. Chang MY, Hsieh CL, Shiau CS, Hsieh TT, Chiang RD, Chan CH. Ultrasound-guided aspiration and ethanol sclerotherapy (EST) for treatment of cyst recurrence in patients after previous endometriosis surgery: analysis of influencing factors using a decision tree. *J Minim Invasive Gynecol.* 2013;20(5):595-603.
 37. Miquel L, Preaubert L, Gnisci A, Resseguier N, Pivano A, Perrin J, et al. Endometrial ethanol sclerotherapy could increase IVF live birth rate in women with moderate-severe endometriosis: retrospective cohort study. *PLoS One.* 2020;15(9):e0239846.
 38. Tehrani HG, Tavakoli R, Hashemi M, Haghghat S. Ethanol sclerotherapy versus laparoscopic surgery in management of ovarian endometrioma; a randomized clinical trial. *Arch Acad Emerg Med.* 2022;10(1).
 39. Lee JK, Ahn SH, Kim HI, Lee YJ, Kim S, Han K, Kim MD, Seo SK. Therapeutic efficacy of catheter-directed ethanol sclerotherapy and its impact on ovarian reserve in patients with ovarian endometrioma at risk of decreased ovarian reserve: a preliminary study. *J Minim Invasive Gynecol.* 2022;29(2):317-23.