



Intravesical Herniation of Tubal Fimbria Through Vesicovaginal Fistula Associated with Ureterovaginal Fistula Mimicking Bladder Mass: A Case Report of Unreported and Undescribed Hernia

Sankapal Prakash, Gite Venkat Arjunrao *, Agrawal Mayank, Maheshwari Mudit, Sharma Shashank

- Department of Urology, Grant Government Medical College & Sir JJ Hospital, Mumbai, India

Abstract

Background: One of the few remaining important issues in urological and gynaecological surgery relates to fistulas between the urinary tract and the vagina. Vesicovaginal fistula (VVF) and ureterovaginal fistulas (UVF) are defined as abnormal connections between the urinary tract, on the one side, and the female genital system, on the other.

Case Presentation: This study is about an unreported and undescribed case of 24 year old female who presented with the complaints of continuous urinary incontinence for 18 months following total abdominal hysterectomy. Preoperative cystoscopy and vaginal/speculum findings revealed a papillary frond like mass protruding intravesically from VVF site which was free from the edges of fistulous opening all around. Also, left ureteric orifice was not visualized. On exploration, there was evidence of intravesical herniation of right tubal fimbria through the common opening of VVF and left UVF near left vaginal vault apex mimicking a bladder mass presenting with continuous incontinence for 18 months. Modified O' Connors VVF repair with left ureteric reimplantation was done. The postoperative period was uneventful with patient having no incontinence.

Conclusion: It seems that surgical resection of ovarian cyst with VVF and UVF repair is the definitive treatment and histopathological examination is essential to exclude malignant transformation.

Keywords: Bladder mass, Fimbria, Incontinence, Ovarian cyst, Ureterovaginal fistula, Vesicovaginal fistula.

To cite this article: Prakash S, Venkat Arjunrao G, Mayank A, Mudit M, Shashank Sh. Intravesical Herniation of Tubal Fimbria Through Vesicovaginal Fistula Associated with Ureterovaginal Fistula Mimicking Bladder Mass: A Case Report of Unreported and Undescribed Hernia. *J Reprod Infertil.* 2023;24(1):63-65. <https://doi.org/10.18502/jri.v24i1.11911>.

Introduction

Vesicovaginal fistula (VVF) and ureterovaginal fistulas (UVF) are the most troublesome complications of obstetric trauma and pelvic surgery. The overall incidence of urinary tract injuries during pelvic surgery is 0.33%. Abdominal hysterectomy is the most common surgery complicating urogynecological injury (1). The most common indication for urogynecological injury is benign leiomyoma. There are few case reports of VVFs caused by vaginal foreign bodies, direct trauma from masturbation or road traffic acci-

dents, bladder calculi, forgotten vaginal pessaries, endometriosis, and infections such as tuberculosis, schistosomiasis, syphilis, lymphogranuloma venereum, and idiopathic congenital diseases (2). Papers on intravesical herniation of small bowel after bladder perforations and ovarian dermoid cyst perforating into the urinary bladder are noted case reports (3). Intravesical herniation of tubal fimbria through vesicovaginal fistula associated with ureterovaginal fistula is unreported and undescribed in literature to date.

* Corresponding Author:
Gite Venkat Arjunrao,
Department of Urology,
Grant Government Medical
College & Sir JJ Hospital,
Mumbai, India
E-mail:
balajigite@yahoo.com

Received: Jan. 12, 2022

Accepted: May 7, 2022

Case Presentation

A 24 year old gravida 2 para 2 female presented to our tertiary referral center (Grant Government Medical College and Sir JJ Group of Hospitals Mumbai, India) for the first time, in the year 2021 with complaints of continuous incontinence for 18 months. She underwent abdominal hysterectomy for benign leiomyoma nearly 18 months ago in a peripheral part of western India. Prior to this, the patient had 2 normal vaginal deliveries 2 and 4 years ago. The patient developed continuous incontinence immediately after removal of foley catheter on the 2nd postoperative day. The patient was discharged on the 8th postoperative day without any wound infection on surgical site.

The patient was referred for the management of VVF which was diagnosed elsewhere. Her physical examination and laboratory investigations were normal. An ultrasonography revealed left mild hydroureteronephrosis with an empty bladder. The contrast enhanced computed tomography (CECT) scan of the abdomen and pelvis revealed contrast extravasation from the left side of the posterior wall of urinary bladder into the vaginal vault of tract (1x2x5 cm) and a right ovarian cyst which was stuck to the sutured vaginal vault (Figure 1).

The examination under anaesthesia with cystoscopy and vaginal/speculum findings revealed a papillary frond like mass protruding intravesically from VVF site which was free from the edges of fistulous opening all around. Left ureteric orifice couldn't be visualized (Figure 2).

Considering the CT scan and cystoscopic findings, the patient was electively planned for modified O'Connors VVF repair with left ureteric re-implantation. On exploratory laparotomy, the right ovarian cyst was densely adhered near the left vaginal vault apex which was located near the VVF site with right fimbrial herniation into the bladder through the VVF tract (Figure 2). This fimbrial herniation was mimicking bladder mass on preoperative cystoscopy. The ovary was enlarged in size with cystic consistency. The tube and peritoneum were normal. The ovary was dissected free from the bladder wall. The ovary seemed to contain only a small volume of normal tissue, so a right salpingo-oophorectomy was done. Left ureteric reimplantation was done over DJ stent. VVF tract was excised with double layer closure done on the bladder and vaginal side using 3/0 vicryl and omentum was interposed between

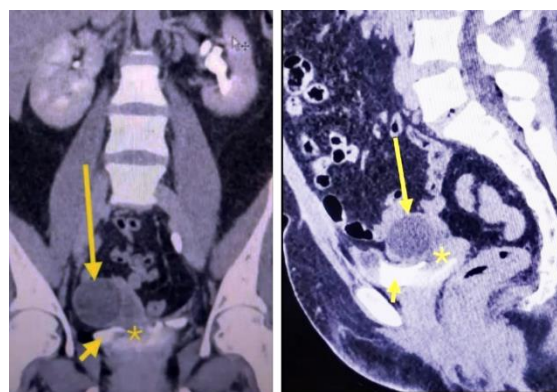


Figure 1. CECT of the abdomen and pelvis showing contrast extravasation from the left side of the posterior wall of urinary bladder (short arrow) into the vaginal vault of tract with intravesical fimbrial herniation (asterisk) and a right ovarian cyst (long arrow), stuck to sutured vaginal vault

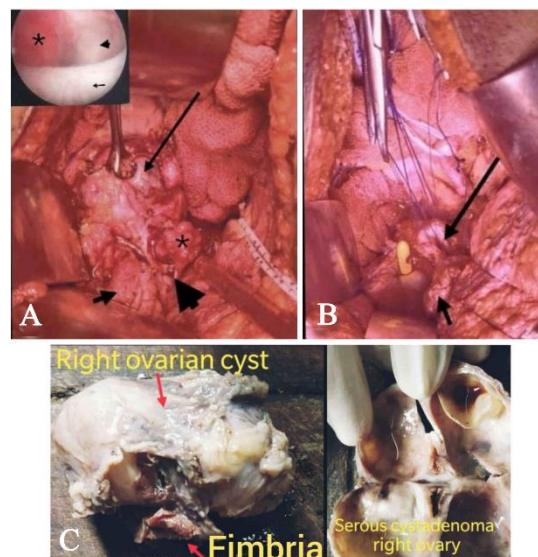


Figure 2. Image showing (A) right ovarian cyst (long arrow) densely adhered near the left vaginal vault apex located near the VVF site (arrow head) with right fimbrial herniation (asterisk) into the bladder (short arrow) through the VVF tract, (B) bladder (short arrow) and vaginal end (long arrow), post right salpingo-oophorectomy [Cystoscopic view showing papillary frond like mass (asterisk) protruding intravesically (arrow) from VVF site (arrow head)], (C) gross specimen of serous cystadenoma of the right ovary with fimbria

the two. The right ureteric orifice was localized and found to be normal.

Histopathological examination showed serous cystadenoma of the right ovary and normal right fimbria. An indwelling catheter was left in situ for 2 weeks. The postoperative period was uneventful. The patient voided with a good stream and

she was clinically asymptomatic at the end of 6 months.

Discussion

In developing countries, the VVF results from obstetric surgeries, whereas in developed countries the gynaecological surgeries (hysterectomy), pelvic radiotherapy, trauma, and malignant disease are the main causes (4). In fact, 12% of the patients with VVFs have associated UVFs (1). The most common operation complicating urogynecological injuries is abdominal hysterectomy and the most common indication is benign leiomyoma (4). Our patient also underwent abdominal hysterectomy for benign leiomyoma of the uterus. After surgery, it might last 2 to 4 weeks for a UVF to become clinically evident. Intermittent or position-related vaginal leakage of urine can be expected with UVF, whereas urine leakage is more constant with pure VVF (4). Our patient developed continuous incontinence immediately after removal of the foley catheter on the 2nd postoperative day. The patient presented to our center after 18 months with the diagnosis of VVF only.

Spontaneous rupture of ovarian dermoid cyst into the adjacent viscera is least common. Gupta et al. have proposed different etiologies for fistula formation in dermoid cysts. Chronic leakage of the seborrhoeic material leading to inflammation and subsequent fistulization are the main factors in fistulization into adjacent viscera. The bladder is the most common site of spontaneous perforation. These patients present with complaints of irritative symptoms of lower urinary tract, pyuria, the passage of seborrhoeic gravels, and the passage of hair (3). Our patient did not have such complaints.

Regarding our case, the patient had serous cystadenoma of the right ovary which may be missed by the primary operating surgeon or the patient may have developed the cyst after the surgery. During the post-hysterectomy period, weight of the ovarian cystadenoma or migration of right ovary with fimbria towards dependent side may be the cause of the attachment of it to the vaginal vault. The patient subsequently developed VVF and UVF from the left half of vaginal vault and as the fimbrial end of the ovary is free, it may get herniated through the fistula into the bladder which looks like bladder mass on cystoscopic evaluation. This has not been described in literature till now as per our knowledge.

For preoperative planning, CT urography and T2-weighted pelvis MRI provide excellent anatomical information regarding the location of the VVF and associated UVF/ureteric obstruction (4). Cystoscopy and examination under anaesthesia on the day of VVF repair are recommended to confirm the site, size, number of fistulas, proximity to the ureteric orifices, and for positioning ureteric catheters through the fistulas and into the ureters (4).

Conclusion

Although rare, missed fimbrial end at the VVF site may end up in resection as transurethral resection of bladder tumor (TURBT) during the cystoscopic examination. To avoid such a problem, preoperative anticipation with supportive cystoscopic and radiological findings and confirmation at laparotomy is the key in the diagnosis and management of fimbrial herniation at VVF site. Surgical resection of ovarian cyst with VVF and UVF repair is the definitive treatment and histopathological examination is essential to exclude malignant transformation.

Conflict of Interest

There is no conflict of interest to declare.

References

1. Goodwin WE, Scardino PT. Vesicovaginal and ureterovaginal fistulas: a summary of 25 years of experience. *J Urol*. 1980;123(3):370-4.
2. Meeks GR, Ghafa MA. Rectovaginal Fistulas. In: Peter von Dadelszen editor. *The global library of women's medicine's*. UK: International federation of gynecology and obstetrics; 2012. DOI 10.3843/GLOWM.10065
3. Gupta SK, Kumar M, Singh M, Kumar V, Tiwari RK, Suman SK, et al. Ovarian dermoid cyst perforating into the urinary bladder. *Uro Today Int J*. 2012;5(4).
4. Seth J, Kiosoglous A, Pakzad M, Hamid R, Shah J, Ockrim J, et al. Incidence, type and management of ureteric injury associated with vesicovaginal fistulas: report of a series from a specialized center. *Int J Urol*. 2019;26(7):717-23.