



The Appropriate Criteria in Patients Selection for Myomectomy in the Era of Minimally Invasive Surgery: A Case Report

Sangam Jha ^{1*}, Sonia ¹, Hemali Sinha ¹, Upasna Sinha ²

1- Department of Obstetrics and Gynecology, AIIMS Patna, Bihar, India

2- Department of Radiodiagnosis, AIIMS Patna, Bihar, India

Abstract

Background: Myoma is the most common benign monoclonal neoplasm of the uterus with increased frequency during reproductive years of women.

Case Presentation: A twenty two year old female presented with abdomen lump, dysmenorrhoea, and heavy menstrual bleeding. Multiple myomas were diagnosed based on clinical and radiological findings. Abdominal myomectomy was performed and 75 myomas were enucleated followed by reconstruction of uterus. The second case was a 28 year old married woman presented with heavy menstrual bleeding and dysmenorrhoea. Ultrasound reported single posterior wall myoma of 8×6.3×5.8 cm in size. Laparoscopic myomectomy was performed. At follow-up visit, both cases were completely free of any symptoms.

Conclusion: Myomectomy is a feasible and safe option and a uterine preserving surgery even in the presence of multiple myomas. Setting appropriate criteria in selecting patients for abdominal myomectomy rather than MIS is essential to avoid conversion and associated morbidity.

Keywords: Heavy menstrual bleeding, Laparoscopy, Myoma, Uterine myomectomy, Uterine preserving surgery.

To cite this article: Jha S, Sonia, Sinha H, Sinha U. The Appropriate Criteria in Patients Selection for Myomectomy in the Era of Minimally Invasive Surgery: A Case Report. *J Reprod Infertil.* 2022;23(4):310-313. <https://doi.org/10.18502/jri.v23i4.10818>.

* Corresponding Author:
Sangam Jha, Associate
Professor, Department of
Obstetrics and Gynecology,
AIIMS Patna, Bihar, India
E-mail:
sangam.jha78@gmail.com

Received: Oct. 10, 2021

Accepted: Mar. 3, 2022

Introduction

Myomas are the most common pelvic tumors in women with estimated incidence of 10 to 20%, yet the prevalence has been reported as high as 70-80% in studies in which histologic or sonographic examination was conducted (1). Myomas are estrogen and progesterone dependent tumors with increased frequency during late reproductive years. Though most of them are sporadic, familial clustering could be seen in 20-30% of cases (2). Most of the women with fibroid are asymptomatic, and symptoms in those who are symptomatic could be influenced by size, location, and associated complication (1). Myomas have been classified using FIGO classification based on their location (3). Diagnosis is usually confirmed on ultrasound; however, MRI may be

needed occasionally for pre-operative mapping or to differentiate it from adenomyosis (4). Treatment depends on symptoms, location, size, the desire for fertility, and available equipment. The feasible treatment options are medical, surgical (myomectomy, radiofrequency ablation, and hysterectomy), and minimally invasive procedures. Despite the availability of novel medical management, surgery remains the cornerstone of myoma management. In this paper, two cases of myomectomies, performed at a tertiary care institute (AIIMS Patna) in 2021, have been reported; in one of the cases, abdominal myomectomy was done whereas laparoscopic myomectomy was performed in the other. This case report highlights the importance of careful patient selection for ei-

ther minimally invasive surgery (MIS) or open myomectomy to avoid conversion and associated morbidity.

Case Presentation

A twenty two year old sexually inactive girl visited our outpatient department (OPD) with complaints of dysmenorrhoea and heavy menstrual bleeding for 5 years and abdominal swelling for 3 years which was gradually increasing. Her previous cycles were normal. Her family history was significant since her sister had multiple myomas and underwent surgical removal in her 20s. Severe pallor was noticed on general examination. Local examination revealed a firm, well defined lobulated mass of 32 weeks gravid uterus size arising from pelvis. Transabdominal ultrasound was done for the clinical diagnosis of fibroid uterus. On ultrasonography, multiple intramural and subserosal myomas were noticed. Since we were planning for myomectomy, MRI was performed which reported multiple ill-defined to relatively well-defined closely abutting heterogeneous masses in the abdominopelvic region measuring $20 \times 12 \times 10$ cm in size (the largest lesion measuring $9.7 \times 8.7 \times 7.8$ cm in lower posterior myometrium). Endometrial lining was seen compressed along the anterior aspect of the lower half of masses with only thin rim of posterior myometrium visualized. Endometrial lining could not be delineated in the upper half of the uterus. Findings were suggestive of multiple myometrial, intramural, and subserosal myomas with cystic degeneration in few of them (Figures 1A and 1B). Based on clinical and radiological findings, diagnosis of multiple myomas was made. As the number of myoma was exceeding 5, open myomectomy was planned. Three units of packed red blood cells

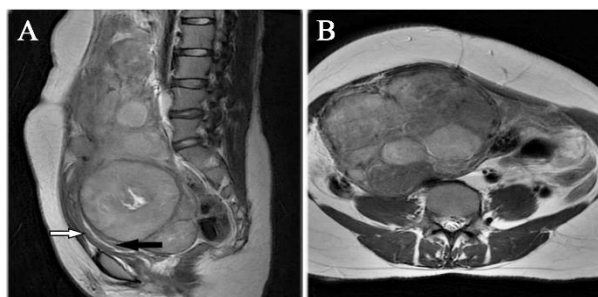


Figure 1. A) Sagittal T2 w image showing multiple fibroids in posterior wall of uterus and cervix with endometrial canal compressed anteriorly (black arrow), and anterior uterine wall (white arrow). B) Axial T2w image showing multiple fibroids in fundal region

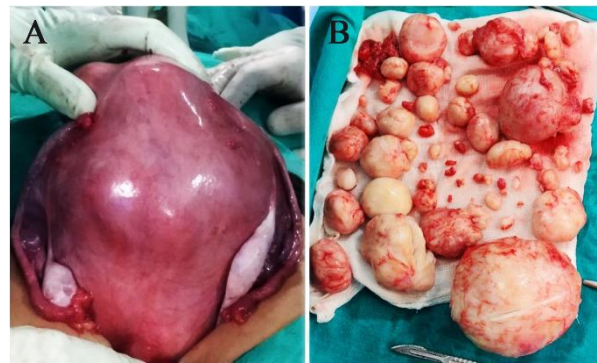


Figure 2. A) Intraoperative image showing grossly enlarged uterus with multiple fibroids. B) Removal of 75 fibroids

(PRBCs) were transfused in preoperative period for correcting anaemia (pre-op Hb -6.4 gr). Abdomen was opened by midline vertical infraumbilical incision. Before the enucleation, vasopressin (20 units in 200 ml of normal saline) was infiltrated into the myometrium to decrease intraoperative blood loss. As myomas were distending the lower uterine segment and cervix, ureter of both side was traced up to bladder by retroperitoneal dissection. The incision was made vertically in the anterior wall of the uterus, ascending to the upper uterine segment and 30 myomas were enucleated through the incision. The second incision was made posteriorly (as approaching through the incision in the anterior wall was not possible) over lower uterine segment and 45 myomas were enucleated (Figures 2A and 2B). Myoma beds were closed meticulously using interrupted mattress sutures with Vicryl 1-0. Uterine incisions were closed using baseball sutures. Total blood loss was approximately one litre and operative time 135 min. Post-operatively, she required 2 units of blood transfusion. The patient made a good recovery and was discharged on day seven. On her second follow-up after 3 months, she was asymptomatic and had normal menses without dysmenorrhoea. She was happily married and pregnant at 6 weeks at the time of writing this paper.

A 28 year old nulliparous woman presented with complaints of dysmenorrhoea and heavy menstrual bleeding for two years. Her previous cycles were regular. Mild pallor was noticed on physical examination. Local examination revealed a uterus with 12 week size and maximum bulge was noted on the left posterior lateral wall. The rest of examination results were normal. Ultrasound reported a large posterior wall myoma of $8 \times 6.3 \times 5.8$ cm in size. MRI reported single, well defined, heteroge-

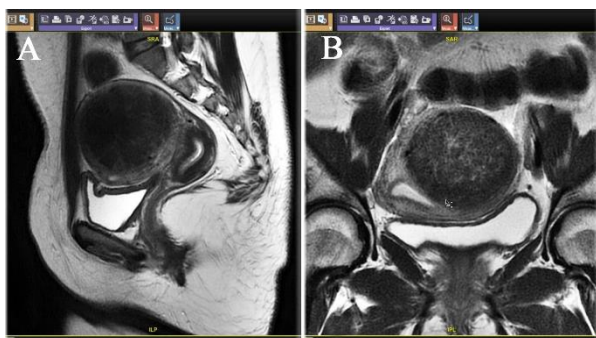


Figure 3. A) Sagittal T2 w image showing a single fibroid in the left posterolateral wall of uterus. B) Axial T2w image showing large fibroids in posterolateral wall

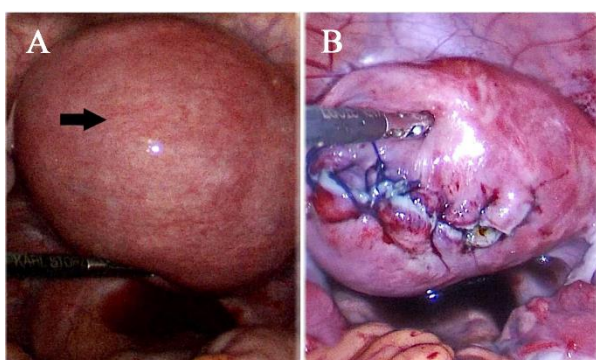


Figure 4. A) Laparoscopic view showing a large fibroid in the left posterolateral wall of uterus (black arrow). B) Laparoscopic view showing stitched uterus following myomectomy

neous intramural mass in the left posterolateral wall of uterus measuring 7×6.3×6.4 cm in size, indenting the endometrial cavity and displacing it towards the right side (Figures 3A and 3B). Laparoscopic myomectomy was performed. Next, 20 units of diluted vasopressin was infiltrated into the myoma. Horizontal incision was made over the most prominent part of myoma, enucleation was performed, and myoma bed was obliterated using 2-0 barbed suture (Figures 4A and 4B). Total operative time was 70 min and blood loss was 80 ml. The patient made good recovery and was discharged on the second day of surgery. During follow-up, she had conceived spontaneously and she was pregnant at 32 weeks at the time of writing this paper.

Discussion

Myomas are benign monoclonal tumors of smooth muscle. Depending on the location and size of the fibroid, patients can present with abnormal uterine bleeding (AUB), pelvic lump,

pressure or infertility. Our patients presented with dysmenorrhoea, heavy menstrual bleeding, and abdominal lump. Though myomas are found sporadically, clustering in the family could be seen; the first patient was such as case whose elder sister had multiple myomas in her 20s. Ultrasound is the first-line imaging used in diagnosing uterine myomas (4). Nevertheless, MRI may be required to confirm size, location, number, and endometrial cavity encroachment. In these cases, preoperative MRI was performed for planning of site and number of uterine incisions. Management is influenced by the presenting symptoms, the desire to preserve fertility, and availability of facilities. The accessible management options are medical, surgical (laparoscopic myomectomy, hysteroscopy, radiofrequency ablation, hysterectomy), and minimally invasive procedures (endometrial ablation, uterine artery embolization, magnetic resonance guided focused ultrasound) having their own indications, benefits, and risks (5). Even with the availability of novel medical options, surgery remains the mainstay of myoma management. Despite clear advantages of MIS, surgeons should cautiously select the patients for endoscopic myomectomy as "one size doesn't fit all". Vargas et al. noticed that at >270 min of operating time, MIS offers questionable benefit over abdominal myomectomy at <90 min and reinforced that conversion increased the composite morbidity (6). Therefore, setting appropriate criteria with a focus on patient selection for route of myomectomy is the foremost priority to avoid conversion and associated morbidity. Few authors suggested a criterion of a single intramural or subserosal fibroid ≤15 cm or ≤3 fibroids of ≤5 cm for laparoscopic myomectomy whereas others suggested an individual choice based on surgeon's specific experience and limitations (7, 8). However, they recognized that operating time increased with greater number or larger size of fibroids. Open myomectomy was selected in case 1 as the patient desired to preserve her fertility; in the first case, myomas were multiple and expected operating time via laparoscopy was longer. In case 2, there was a single large myoma, so laparoscopic route was the best choice. Since myomas have high vascularity, myomectomy causes excessive blood loss. Therefore, it is essential to use intervention for reducing blood loss during myomectomy. Recent Cochrane review on interventions to reduce blood loss during myomectomy showed that vaginal insertion of misoprostol and infiltration of vasopressin into

the uterine muscle were effective in reducing blood loss during myomectomy; however, no strong evidence was found for the rest of the interventions (chemical dissection, dinoprostone, gelatin-thrombin matrix, tranexamic acid, vitamin C, mixture of bupivacaine and epinephrine, a fibrin sealant patch, and the two types of tourniquet) (9). In our case, infiltration of vasopressin into the myometrium was used for reducing the intraoperative blood loss. As myomas were expanding the lower uterine segment in case 1, the course of ureter was delineated by retroperitoneal dissection before embarking on myomectomy. Ureter delineation is the key step for avoiding its injury during pelvic tumor surgery. Meticulous closure of myoma bed is vital for successful outcome. There are only few case reports of myomectomy for multiple myomas. Bekabil reported removal of 36 fibroids from a 26 year old woman (10). However, this would be the highest number of myomas removed through two uterine incisions to the best of our knowledge. This case report highlights the feasibility of uterine preserving surgery, techniques to reduce blood loss, and measures to prevent ureteric injury during myomectomy for grossly enlarged uterus with multiple myomas and simultaneously emphasizes the importance of patient selection for minimally invasive procedures or abdominal myomectomy to offer maximum benefit to the patients.

Conclusion

It seems that myomectomy is a feasible and safe option for the treatment of uterine fibroids. Laparoscopy clearly demonstrates faster recovery rate, less adhesion formation, possibility of using more cosmetic incisions, and reduced blood loss compared to open techniques. However, in multiple myomas, the size more than 10-15 cm and number >5 is associated with longer operative time and the need for multiple uterine incisions, thus blunting the benefits of laparoscopy. Therefore, clinicians should not enthusiastically adopt minimally invasive myomectomy for every case as one size does not fit all. There are indications for the use of abdominal myomectomy even in the era of MIS.

Conflict of Interest

Authors of this article declare that they have no conflict of interest.

Funding: Authors declare that they have not received any fund for this article.

References

1. Grube M, Neis F, Brucker SY, Kommos S, Andress J, Weiss M, et al. Uterine fibroids-current trends and strategies. *Surg Technol Int.* 2019;34: 257-63.
2. Saldana TM, Moshesh M, Baird DD. Self-reported family history of leiomyoma: not a reliable marker of high risk. *Ann Epidemiol.* 2013;23(5):286-90.
3. Munro MG, Critchley HOD, Fraser IS; FIGO menstrual disorders committee. Corrigendum to "The two FIGO systems for normal and abnormal uterine bleeding symptoms and classification of causes of abnormal uterine bleeding in the reproductive years: 2018 revisions" [*Int J Gynecol Obstet* 143(2018) 393-408]. *Int J Gynaecol Obstet.* 2019;144(2):237.
4. Woźniak A, Woźniak S. Ultrasonography of uterine leiomyomas. *Prz Menopauzalny.* 2017;16(4):113-7.
5. Rakotomahenina H, Rajaonarison J, Wong L, Brun JL. Myomectomy: technique and current indications. *Minerva Ginecol.* 2017;69(4):357-69.
6. Vargas MV, Denny Larson K, Sparks A, Margulies SL, Marfori CQ, Moawad G, et al. The association of operative time with outcomes in minimally invasive and abdominal myomectomy. *Fertil Steril.* 2019;111(6):1252-8.e1.
7. Agdi M, Tulandi T. Endoscopic management of uterine fibroids. *Best Pract Res Clin Obstet Gynecol.* 2008;22(4):707-16.
8. Mallick R, Odejinmi F. Pushing the boundaries of laparoscopic myomectomy: a comparative analysis of peri-operative outcomes in 323 women undergoing laparoscopic myomectomy in a tertiary referral centre. *Gynecol Surg.* 2017;14(1):22.
9. Kongnyuy EJ, Wiysonge C. Interventions to reduce haemorrhage during myomectomy for fibroids. *Cochrane Database Syst Rev.* 2014;2014(8): CD005355.
10. Bekabil TT. Successful removal of 36 fibroids from a uterus: case report. *Clin Case Rep Rev.* 2015;1(2):25-6.