



The Considerable Case Reports: Observed *Taenia Saginata* after Consuming Undercooked Beef

Pegah Golafshan; MSc¹ & Seyede Manizhe Heidar Nejadi; PhD*²

¹ Student Research Committee, School of Public Health and Safety, Shahid Beheshti University of Medical Sciences, Tehran, Iran; ² Shoushtar Faculty of Medical Sciences, Shoushtar, Iran.

ARTICLE INFO

CASE REPORT

Article history:

Received: 14 Jun 2023

Revised: 15 Jan 2024

Accepted: 21 Feb 2024

*Corresponding author:

Reyhane_zn@yahoo.com

Shoushtar Faculty of Medical
Sciences, Shoushtar, Iran.

Postal code: 6451630002

Tel: +98 9161500401

Keywords:

Taenia saginata;

pyrvinium; Iran;

Parasites.

ABSTRACT

Taeniasis is a significant parasitic infection and zoonotic disease. This study describes the follow-up of a patient with a history of consuming undercooked beef as a result of his occupation. "A 29-year-old, robust and plump individual with a history of working in barbecue preparation", expelled tapeworm of more than 1 meter in length. Initially, by going to a pharmacy, he purchased pyrvinium pamoate suspension", and began treatment (In February 2022, and again in May 2022). Besides, he showed no other gastrointestinal symptoms or complaints except for expelling the entire worm and feeling slightly fatigued. This condition persisted for approximately 1-2 years, during which he regularly consumed raw or undercooked contaminated meat, as well as heart and liver of cattle and calves while preparing barbecue. He elucidated that he had a strong urge to eat them. Unfortunately, his treatment was discontinued when he was imprisoned for three months, during which he did not receive any medication. As a result, he mentioned that he sometimes expelled worms, some of which were more than six meters long. He also described the intense horror he felt when, at times, proglottids (segments of the parasite) appeared in his feces. As far as the author is aware, this is an important report on taeniasis, following years of healthcare efforts against parasitic diseases in Shushtar City, Khuzestan Province

Introduction

T. saginata (beef tapeworm) is one of the most widespread parasitic infections worldwide. Infection of *T. saginata* affects the intestine of the definitive host (human) and can lead to digestive issues, resulting in significant economic and public health consequences in developing countries, including those in the Middle East and North Africa, which is the focus of this study (Saratsis *et al.*, 2019).

Taeniasis is one of the most important food-borne parasitic diseases, but it is both preventable

and treatable. Clinical signs of taeniasis include abdominal pain, weight loss, anorexia, nausea, and other disorders in the human host (Heyneman, 1996, Okello and Thomas, 2017). Given the importance of parasite distribution in developing countries, particularly in Central and Western Asia (Torgerson *et al.*, 2019), this study was conducted in Shushtar city, Khuzestan province, in southwestern Iran (Kia *et al.*, 2005). Khuzestan is an endemic area for taeniasis, making the findings of this study highly relevant (Kia *et al.*, 2005,

Moazeni *et al.*, 2019). The authors obtained results from patient data after their referral to laboratories. A search of Medline, EMBASE, Scopus, and Web of Science using the keywords *T. saginata*, taeniasis, RA, and T2DM revealed the presence of eggs and gravid proglottids in stool samples. In this study, the authors described the condition of patients with taeniasis.

Case report

A 29-year-old Iranian male from Shoushtar City, who is robust and plump, initially worked as a barbecue vendor but has since changed jobs. He reported that while working, he developed a habit of eating raw meat and animal hearts, consuming them with a very high appetite. Recently, he experienced the sudden appearance of a long worm in his stool for the first time. He described the presence of the worm as persistent, prompting him to visit a drugstore, where he purchased Pyrvinium pamoate suspension for self-treatment.

The patient clarified that he did not originally seek medical attention for gastrointestinal complaints, but was concerned only about the worm and a mild sense of fatigue that had developed recently. He mentioned that he had been dealing with this infection for approximately 2-3 years. The infection likely arose from his habit of consuming undercooked or raw meat, including beef, liver, and heart from cattle and calves, which he stated he particularly enjoyed due to his strong appetite.

After consuming raw, contaminated meat in 2022, the patient referred to a drugstore. Shortly after, he began self-treatment with Pyrvinium pamoate suspension in February 2021. Treatment was resumed in May 2022. However, his treatment

was temporarily discontinued because he was incarcerated for three months, during which he had no access to medication. While in prison, he occasionally observed a full worm, measuring up to 6 meters, which was distressing to him. He also described noticing proglottids (segments of the parasite) in his stool.

After his release from prison, the patient returned to his job in January 2022. At this time, he encountered the full worm again, but without any clinical symptoms. He then sought medical attention from a physician and began treatment with niclosamide. The patient went to the physician's office complaining of abdominal pain, nausea, and the presence of proglottids in his feces.

Upon examination, the physician observed passing segments (proglottids) and eggs in the patient's stool. The patient was seen by the physician twice, and laboratory tests confirmed the presence of taeniid eggs and proglottids in the feces. Based on this evidence, the authors concluded that this case was a report of *Taenia saginata* infection.

The patient occasionally noted segments in his stool, which appeared when the worm had fully matured in his intestines, approximately 14 weeks after ingesting contaminated raw meat. This patient had been dealing with the infection for an average of two years.

The data for this study was collected from the patient and laboratory results. This case of *T. saginata* infection was confirmed through microscopic examination of fecal samples, where segments and eggs were identified based on standard procedures, as shown in **Figure 1.**

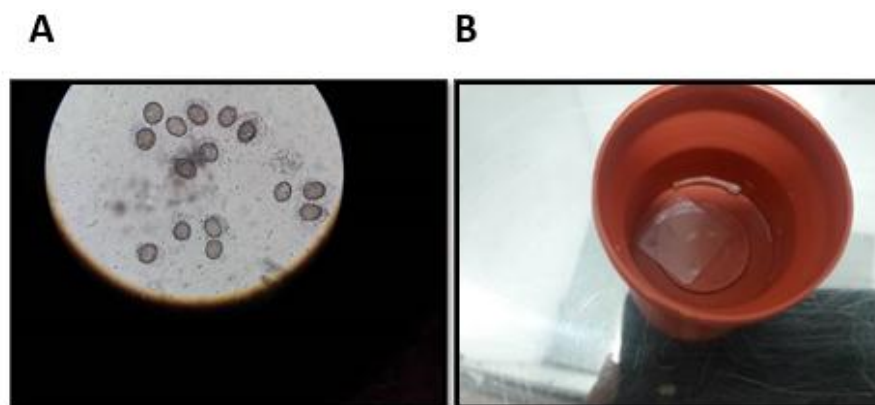


Figure 1. Ova and proglottid found in the patient's feces. **A:** Ova found in the patient's feces. **B:** Proglottid found in the patient's feces.

Discussion

T. saginata is considered one of the World Health Organization (WHO)-neglected parasitic diseases and continues to be a significant public health burden in many developing countries (Braae *et al.*, 2018, Okamoto M, 2013). It is typically transmitted through the consumption of undercooked or raw beef from infected cattle (Ito *et al.*, 2003). Although the overall burden of infection is relatively low, it remains an important concern because many individuals may be unaware that they have a tapeworm infection. Symptoms can range from mild or asymptomatic to severe, such as intestinal obstruction or perforation, particularly in endemic areas (Nematihonar *et al.*, 2023) Furthermore, the condition may lead to personal disorders and cause considerable economic burden, affecting both healthcare systems and national economies (Gebrie and Engdaw, 2015, Heidari *et al.*, 2016). A recent study demonstrated that contamination occurs in individuals who habitually consume raw or undercooked beef. Despite some unknown healthcare practices, the infection has not been effectively managed, leading to the spread of taeniasis to others. This is due to the parasite's life cycle, which includes transmission to animals and the widespread presence of infected muscle tissue in intermediate hosts, which are then consumed by final hosts (i.e., humans). On the other hand,

improper treatment is a concern. While Mebendazole is moderately effective, other drugs such as Benzimidazoles, Albendazole, Fenbendazole, and Nitazoxanide are also effective, with Nitazoxanide being particularly strong in its cestocidal action (Rossignol and Maisonneuve, 1984), Niclosamide, being non-absorbable, is non-toxic and may break the body into segments. Praziquantel is highly effective against *T. saginata* and is considered the best alternative to Niclosamide due to its cost, efficacy, availability, and safety (Vermund *et al.*, 1986). This study aligned with the findings of Heidari *et al.*'s study, emphasizing that taeniasis can cause a significant public health burden, especially in developing countries. Further research is needed, along with increased attention to rural meat inspection systems and the implementation of sustainable education on preventing this infection. This disease has both public health and economic implications, leading to organ condemnation, loss of meat quality, refrigeration costs, human therapy costs, and reduced productivity (Braae *et al.*, 2018, Heidari *et al.*, 2016).

Conclusion

It is essential that slaughterhouses, as sources of meat supply, implement strict inspections to condemn and remove contaminated carcasses. Additionally, it is crucial to address the use of human fertilizers in vegetable farming, especially

given the domestic consumption of vegetables in urban areas and their importance for export. To prevent, control, and possibly eliminate *T. saginata*, efforts should be made to regulate these practices. Furthermore, the application of molecular techniques is necessary to distinguish *T. saginata* from other tapeworm species, such as *T. solium* and *T. asiatica*.

Acknowledgements

No financial report was received for this study.

Authors' contributions

P Golafshan designed the model and analyzed the data. SM Heidar Nejadi wrote the manuscript.

Conflict of Interest

The authors declared no conflict of interests.

Funding

This study is a part of research work funded by Shoushtar Faculty of Medical Sciences, Shoushtar, Iran (grant no. 401000028).

References

- Braae UC, et al.** 2018. Epidemiology of *Taenia saginata* taeniosis/cysticercosis: a systematic review of the distribution in the Americas. *Parasites & vectors*. **11** (1): 1-12.
- Gebrie M & Engdaw TA** 2015. Review on Taeniasis and its zoonotic importance. *European journal of applied sciences*. **7** (14): 182-191.
- Heidari A, et al.** 2016. Case Record of a Teaching Hospital in Karaj; A 35-Year Old Man With *Taenia saginata* Infection Treated With Niclosamide. *International journal of enteric pathogens*. **4** (4): 9-37109.
- Heyneman D** 1996. Cestodes. *Medical Microbiology*. 4th edition.
- Ito A, Nakao M & Wandra T** 2003. Human taeniasis and cysticercosis in Asia. *Lancet*. **362** (9399): 1918-1920.
- Kia E, Masoud J, Yalda A, Mahmoudi M & Farahani H** 2005. Study on human taeniasis by administering anti-taenia drug. *Iranian Journal of Public Health*. **34** (4): 47-50.
- Moazeni M, Khamesipour F, Anyona DN & Dida GO** 2019. Epidemiology of taeniosis, cysticercosis and trichinellosis in Iran: A systematic review. *Zoonoses and public health*. **66** (1): 140-154.
- Nematihonar B, Hosseini SPK & Toutounchi AH** 2023. *Taenia saginata*, the incidental find in case of intestinal perforation after blunt trauma and literature review. *International journal of surgery case reports*. **103**: 107909.
- Okamoto M WY, Raoul F,** 2013. Mini review on chemotherapy of taeniasis and cysticercosis due to *Taeniasolium* in Asia, and a case report with 20 tapeworms in China. *Tropical biomedicine*. **30** (2): 164-174.
- Okello AL & Thomas LF** 2017. Human taeniasis: current insights into prevention and management strategies in endemic countries. *Risk management and healthcare policy*. **10**: 107.
- Rossignol J & Maisonneuve H** 1984. Nitazoxanide in the treatment of *Taenia saginata* and *Hymenolepis nana* infections. *American journal of tropical medicine and hygiene*. **33** (3): 511-512.
- Saratsis A, et al.** 2019. Epidemiology of *Taenia saginata* taeniosis/cysticercosis: a systematic review of the distribution in the Middle East and North Africa. *Parasites & vectors*. **12** (1): 1-15.
- Torgerson PR, et al.** 2019. Epidemiology of *Taenia saginata* taeniosis/cysticercosis: a systematic review of the distribution in central and western Asia and the Caucasus. *Parasites & vectors*. **12** (1): 1-8.
- Vermund SH, MacLeod S & Goldstein RG** 1986. Taeniasis unresponsive to a single dose of niclosamide: case report of persistent infection with *Taenia saginata* and a review of therapy. *Reviews of infectious diseases*. **8** (3): 423-426.