



# Age Estimation Based on Cone-Beam Computed Tomography of the Spheno-Occipital Synchondrosis and Demirjian Method in an Iranian Population

Mahnaz Sheikhi<sup>1</sup>, Pedram Iranmanesh<sup>2</sup> and Naeimeh Nasri<sup>3\*</sup>

1. Torabinejad Dental Research Center, Department of Oral and Maxillofacial Radiology, School of Dentistry, Isfahan University of Medical Sciences, Isfahan, Iran

2. Department of Endodontics, Dental Research Center, Dental Research Institute, School of Dentistry, Isfahan University of Medical Sciences, Isfahan, Iran

3. Department of Oral and Maxillofacial Radiology, School of Dentistry, Isfahan University of Medical Sciences, Isfahan, Iran

## \* Corresponding author

**Naeimeh Nasri, DDS**

Department of Oral and Maxillofacial Radiology, School of Dentistry, Isfahan University of Medical Sciences, Isfahan, Iran

**Tel:** +98 913 2163486

**Fax:** +98 31 3668 7080

**Email:** naeemenasri@yahoo.com

**Received:** Apr 16 2023

**Accepted:** Aug 26 2023

## Citation to this article:

Sheikhi M, Iranmanesh P, Nasri N. Age Estimation Based on Cone-Beam Computed Tomography of the Spheno-Occipital Synchondrosis and Demirjian Method in an Iranian Population. *J Iran Med Counc.* 2024;7(2):328-36.

## Abstract

**Background:** Spheno-occipital synchondrosis is a growth center that is involved in craniofacial development. Since osteogenesis of this synchondrosis occurs relatively later than other synchondroses, it has been taken into account for age estimation in forensics. This study aimed to evaluate spheno-occipital synchondrosis using Cone-Beam Computed Tomography (CBCT) in an Iranian population.

**Methods:** In this cross-sectional study, 148 CBCT images (76 women and 72 men) of patients aged 7-25 years, with a mean age of  $19.92 \pm 6.3$  years, were assessed by two radiologists to analyze the spheno-occipital synchondrosis fusion degree using a four-stage system. In addition, the third molar development degree (Demirjian index) was assessed in panoramic and cross-sectional views of CBCT images. The correlation between spheno-occipital synchondrosis fusion degree and age was obtained. Multiple regression analysis was used for age estimation using spheno-occipital synchondrosis fusion degree and third molar development degree (Demirjian index). Intra-observer and inter-observer coefficients of agreements were also measured. IBM SPSS Statistics 20.0 was used.

**Results:** There was a positive correlation between spheno-occipital synchondrosis fusion degree and age ( $r=0.75$ ,  $p<0.001$ ). The multiple regression model provides a more robust model than when each age marker is utilized individually. The kappa coefficient was 0.53 for inter-observer agreement and 0.77-0.92 for intra-observer agreement.

**Conclusion:** Assessing the four-stage spheno-occipital synchondrosis fusion degree was not a robust method; however, combined with the third molar development (Demirjian index), it could be considered as an appropriate marker for age estimation in 7-25-year-old Iranian population.

**Keywords:** Molar third, Osteogenesis, Radiologists, Regression Analysis, Spiral Cone-Beam Computed Tomography

## Introduction

There are numerous situations and conditions that require the knowledge of a person's real age which is important in forensics and the medical profession (1). The main reasons for age estimation include the identification of unidentified corpses in forensics and cases about which there is no legal document on birthdate (2). From a legal point of view, determining the legal age is important for judicial prosecutions and legal decisions. The age range of 14-21 years is considered legal age in various countries (3). There are various methods and measurements for age estimation. Age estimation based on tooth growth and development is an accepted method (4). Hand and wrist radiography is another method of age estimation (5). Evaluation of sternum, clavicle, and first rib cartilage (6,7), pubic bone analysis (8), magnetic resonance imaging of tibia bone and heel bone (9), sagittal suture analysis (10), assessment of femoral bone mineral density and artificial neural networks (11) and DNA analysis (12) are other methods of age estimation. Another method that has recently been taken into consideration is the analysis of sphenoccipital synchondrosis (1,13,14). Sphenoccipital synchondrosis is a pivotal growth center that is involved in craniofacial development, particularly in the dentofacial region (15). The depth and height of the face are increased with a rise in the growth of sphenoccipital synchondrosis (3). Since osteogenesis of sphenoccipital synchondrosis occurs relatively later than other cranial base synchondroses that go through osteogenesis before birth or in early childhood (16,17), sphenoccipital synchondrosis fusion degree has been considered the center of attention for forensic studies (1). Three methods, including macroscopy, conventional radiography, and computed tomography are used to evaluate sphenoccipital synchondrosis (3). Conventional radiography is an inexpensive and accessible method to diagnose sphenoccipital synchondrosis closure, but it has drawbacks such as low resolution and superimposition (3). Considered a 3D imaging modality with high resolution, Cone-Beam Computed Tomography (CBCT) can eliminate superimpositions (18) and reduce the radiation dose and cost compared with CT scans (19). The major problems of age estimation methods are the presence of racial and developmental differences

among populations and the lack of standardization of these methods for any population (3,20). Studies on sphenoccipital synchondrosis closure among different populations have indicated the effect of racial variations on the closure of this synchondrosis (16,21,22). Considering age estimation in forensics and the effect of racial differences on the anatomy, and that there are few studies on age estimation by sphenoccipital synchondrosis using CBCT, the aim of this study is to assess the sphenoccipital synchondrosis for age estimation in an Iranian population.

## Materials and Methods

In this cross-sectional study, all CBCT images of the maxillofacial region of patients aged 7-25 years at the archive of the Department of Oral and Maxillofacial Radiology, Isfahan School of Dentistry from 2011 to 2017 were studied. Ethical approval of the present study was obtained from the local research ethics committee (IR.MUI.REC.1396.3.880). The exclusion criteria consisted of the absence of patients' demographic information in the archive, poor quality of CBCT images, patients with cranial changes or growth disorders, and abnormal morphology due to trauma and pathologic conditions that potentially affect the sphenoccipital synchondrosis. Patients' information, including age and gender, was extracted from the archive and encoded. CBCT images taken by Galileos Comfort 3D imaging (Sirona Dental System Inc., Bensheim, Germany) with flat panel PST detector and the following parameters were included. The parameters encompass a maximum of 85 kV, 14-35 mAs, 15×15 cm Field of View (FOV), 206° rotation, and isotropic voxel size of 0.288 mm. After calibration, two oral and maxillofacial radiologists scored the sphenoccipital synchondrosis fusion degree. A four-stage system (16) was used to rate sphenoccipital synchondrosis fusion degree (Table 1, Figure 1). To observe the sphenoccipital synchondrosis fusion degree, the images were analyzed in multiplanar view. First, the image indicator in coronal view was set on the sphenoid bone crest and ethmoid bone crista galli to determine the midline. Then, the synchondrosis region was studied in the sagittal view. Further, an oral and maxillofacial radiologist observed the CBCT images and determined the third molar development degree based on the eight-stage

**Table 1.** Definition of four stages of spheno-occipital synchondrosis fusion

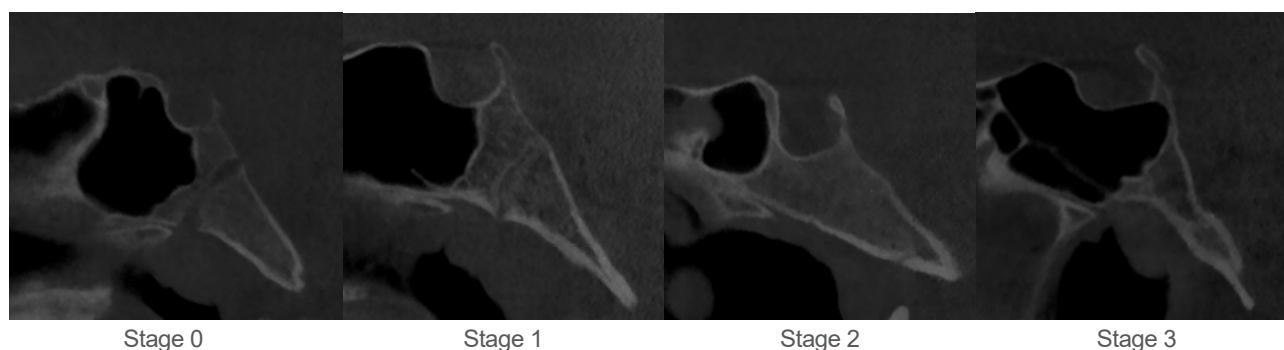
Stage	Definition
Stage 0 (No fusion)	Completely open synchondrosis; no fusion between basilar part of the occipital bone and sphenoid bone, no bone in the gap.
Stage 1 (Intracranial fusion)	Fusion is less than half of the length of synchondrosis as intra- extra-cranial
Stage 2 (Extra-cranial fusion)	Fusion is more than half of the length of synchondrosis without extra-lateral (lower) cranial fusion.
Stage 3 (Complete fusion)	Complete fusion of bones without any abnormality in structure and a fusion scar may be present.

Demirjian index (23) (Table 2). To observe the third molar development (Demirjian index), CBCT images in panoramic and cross-sectional views were used to study the roots more accurately. All the images were observed on a 21-inch EIZO Medical LCD monitor with 1600×1200 resolution under dim light conditions using GALAXIS Viewer version 1.944 (ID2) (SICAT GmbH & Co.KG) software. Statistical analyses were done by IBM SPSS Statistics, Version 20.0. (Armonk, NY: IBM Corp). The descriptive results were expressed as mean, distribution percentage, and standard deviation. The correlation of age with spheno-occipital synchondrosis fusion degree and Demirjian index was analyzed by the Spearman correlation coefficient test. Multiple regression analysis was used to estimate age by spheno-occipital synchondrosis fusion degree and Demirjian index. Inter-observer and intra-rater agreements were checked by Cohen's Kappa test. To obtain the intra-rater coefficient of agreement, 20 CBCT images were randomly selected and studied after two weeks. The agreement rate was as follows: 0.40=poor agreement,

0.40-0.59=moderate agreement, 0.60-0.74=good agreement, and 0.75-100=very good agreement (24).  $p<0.05$  was considered significant for all the tests.

## Results

A total of 148 participants were included in the present study, 76 (51.4%) females and 72 (48.6%) males. The mean age was  $19.92\pm 6.3$ . The maximum and minimum distribution rates of spheno-occipital synchondrosis fusion degree were found for Stage 3 (68.2%) and Stage 0 (8.8%), respectively (Table 3). There were positive correlations between spheno-occipital synchondrosis fusion degree and age ( $r=0.75$ ,  $p<0.001$ ), Demirjian index and age ( $r=0.80$ ,  $p<0.001$ ), as well as Demirjian index and spheno-occipital synchondrosis fusion degree ( $r=0.76$ ,  $p<0.001$ ). In the linear regression model where only spheno-occipital synchondrosis fusion degree was used as an independent variable for age estimation,  $R^2$  was found to be 0.67. Moreover, in the linear regression model where the Demirjian index was used as an independent variable for age estimation,  $R^2$  was equal

**Figure 1.** Radiographic images depicting the fusion process of spheno-occipital synchondrosis in four stages.

**Table 2.** Definition of third molar development degree based on the eight-stage Demirjian index

Stage	Radiographic images	Definition
A		Calcification is initiated at the upper parts of the follicle. There is no bonding between the calcified points.
B		Calcified points are bonded, causing the formation of an occlusal surface.
C		Expansion and convergence of the enamel towards the teeth, start of dentinal deposition.
D		Crown is formed completely up to enamel-cement bonding.
E		Pulp chamber walls are changed into a straight line, and pulp space is generally larger than in the previous stage. The height of the crown exceeds the length of the root.
F		Pulp chamber walls are like an isosceles triangle. The end of the apex is cone-shaped. The length of the root is either equal to or greater than the height of the crown.
G		Root walls are parallel, and the end of the apex is still relatively open.
H		The end of the root apex is completely closed, and a periodontal ligament with equal thickness is seen around the root and apex.

to 0.72 In the multiple regression model, spheno-occipital synchondrosis fusion degree and Demirjian index were considered as independent variables for age estimation. The results of the analysis showed  $R^2$  value was 0.75 (Table 4). In addition, the following

formula was obtained for age estimation:

$$\text{Age} = 3.88 + 1.95 \times \text{fusion degree} + 1.69 \times \text{Demirjian index}$$

Inter-observer Kappa coefficient for spheno-occipital synchondrosis fusion degree was 0.53, which was

**Table 3.** Frequency distribution and the mean age for spheno-occipital synchrondrosis fusion degrees

Stage	Frequency	Percent	Male (%)	Female (%)	Year (Mean±SD)
0	13	8.8	46.2	53.8	8.6±1.9
1	15	10.2	66.7	33.3	11.3±2.7
2	19	12.8	52.6	47.4	16.9±3.0
3	101	68.2	45.5	54.5	23.2±3.9
Total	148	100	48.6	51.4	19.92±6.3

0 no fusion, 1 intracranial fusion, 2 extra-cranial fusion, 3 complete fusion.

**Table 4.** The multiple regression model parameters used for estimating age

Regression model	Spheno-occipital synchrondrosis fusion degree	Demirjian index	Spheno-occipital synchrondrosis fusion degree and Demirjian index
F	302.27*	221.52*	128.64*
R <sup>2</sup>	0.67	0.72	0.75
Adjusted R <sup>2</sup>	0.67	0.71	0.74
SEM	3.63	3.33	3.16
Non-standardized	7.24*Constant 5.27*Fusion	3.97 *Constant 2.41* Demirjian	3.88*Constant 1.95*Fusion 1.69*Demirjian
95% confidence interval	5.69-8.80 Constant 4.67-5.87 Fusion	1.81-6.14 Constant 2.08-2.73 Demirjian	1.82-5.93 Constant 1.95-3.13 Fusion 1.17-2.22 Demirjian

SEM standard error of the mean, F significance of the model, R2 appropriateness of data in the statistical model, \*p<0.05.

in the moderate-good range. Intra-observer Kappa coefficients for spheno-occipital synchrondrosis fusion degree for the first and second observers were 0.92 and 0.77, respectively, which were in the good-very good range.

## Discussion

The importance of age estimation in forensics has increased in recent years. Identification of corpses, prosecution, and identification of asylum seekers without a valid document are important factors involved in age estimation. In addition, the calendar age is significant in most societies with regard to social rights, school attendance, employment, and marriage. It has been known that age analysis is much more accurate among young people since they have more predictable developmental markers in their skeleton (such as tooth development, skeletal

growth, and maturity). Due to fewer developmental indicators in adults, age estimation has been of interest with respect to bone and tooth changes (13). Further, the emergence of new technologies has provided new opportunities in this regard. CBCT has rapidly changed into a gold standard for the analysis of tooth and bone development in forensics (14). The present study investigated the estimation of age through the fusion degree of spheno-occipital synchrondrosis and Demirjian index among a 7-25-year-old Iranian population. In anthropometric analysis, the sample size is an important index since it has to be enough to represent the population and yield acceptable results to be used in legal cases. Extensive variations have been found in the sample size of studies on spheno-occipital synchrondrosis development. Furthermore, the distribution of samples is relatively important because the mean age



of speno-occipital synchondrosis stages is relatively dependent on the age range of the study samples (1). For instance, various results have been obtained regarding the completely open speno-occipital synchondrosis among different populations. Bassed *et al* (25) carried out a study on the 15-25-year-old Australian population and reported only one case of open synchondrosis at age 16. However, Franklin and Flavel (16) reported a mean age of 10.3 and 8.6 years for men and women, respectively, among 5-25-year-old people. In a 10-25-year-old Turkish population, Can *et al* (3) found the mean age of open synchondrosis to be 11.5 in men and 10.7 in women. But Sinanoglu *et al* (1) reported the mean age of 10 years for both genders among 7-25-year-old people. In an Iranian population, Akhlaghi *et al* (26) reported a mean age of 12.3 years for men and 9 years for women for open synchondrosis among 8-26-year-old people. In addition, Akhlaghi *et al* (27) found the mean age of 12.8 years for open suture in 8-26-year-old men. In another study, Akhlaghi *et al* (28) reported this mean age to be 10.8 years among 8-26-year-old women. In a similar population in the present study, the mean age of open synchondrosis for both genders was 8.6 years. This difference might be due to racial differences and different age ranges of the studied samples. Therefore, the results of any population need to be interpreted accurately to prevent error.

There was a positive correlation between speno-occipital synchondrosis fusion degree and age. This positive correlation has also been found in similar studies (1,13,14,26,27,29). A positive correlation has been found between speno-occipital synchondrosis fusion degree and age among an Iranian population in two different studies (25,26). Sinanoglu *et al* (1) reported a positive correlation between Turkish females and males (0.56 and 0.84, respectively). Kocasarac *et al* (13) found a moderate correlation for the male gender (0.59) and a strong correlation for the female gender (0.81) in a Turkish population. Fernández-Pérez *et al* (29) reported the correlation coefficients of 0.73 and 0.65 for the women and men, respectively, in an American population. Bassed *et al* (14) reported a correlation coefficient of 0.46 for men and 0.24 for women in the Australian population. In the present study, there was a positive correlation between Demirjian index and age. This correlation

has also been reported in similar studies (14,29). Fernández-Pérez *et al* (29) found a strong correlation for both genders (0.84 for men and 0.85 for women). Bassed *et al* (14) reported this correlation to be 0.70. In general, it seems there is a positive correlation between speno-occipital synchondrosis fusion degree and age and between Demirjian index and age, and the observed differences can be due to anatomical variations and racial differences. The multiple regression model provides a method for age estimation by using a series of scores obtained from the dental and skeletal development sites. In the age range of 7-25 years, since dentitions and skeleton have mostly matured or are approaching maturity, anatomical development areas are scarce. In the present study, the focus was on the third molar and speno-occipital synchondrosis. Analysis of these markers in previous studies at this age has shown that these markers can be used for age estimation, particularly for the differentiation of children from adults. However, they have shown a low accuracy due to their inherent variation, therefore a wider age range is obtained. It was assumed that the use of multiple regression analysis and the simultaneous use of several development sites could help to achieve a more accurate age range via the overall reduction of variations (14). In the present research, multiple regression analysis achieved a more reliable and accurate model when using both the Demirjian index and speno-occipital synchondrosis fusion degree rather than using the model of each marker alone. The model's high  $R^2$  value of 0.75 suggests that age estimation can be accurately performed by inputting the scores of both indices into the regression model. In addition, by considering confidence levels above and below 95% for beta and fixed coefficients of both variables, with scores of both indices in two separate regression models, the age range of each person at a 95% confidence level can be estimated. Therefore, two calculations are required for the estimation of the age range: one for the maximum level and one for the minimum level. It should be noted that age estimation has been suggested to be done by current population-based standards. It has been shown that population size, distribution of samples, and socioeconomic status can affect speno-occipital synchondrosis fusion degree. Skeletal maturity, in

particular, can be influenced by socioeconomic status because normal growth distribution is associated with nutrition and/or chronic diseases. To ensure unbiased results in studies related to development and growth, it is suggested that the study populations have comparable socioeconomic statuses (1). Given the limitations of the information archive, it was not possible to classify the study sample in the present study according to socioeconomic status. Yet, it seems that most of the individuals referring to the Isfahan School of Dentistry are from Isfahan or the nearby cities, which probably have similarities in their diet and socioeconomic status. The inter-rater Kappa coefficient for spheno-occipital synchronosis fusion degree was at a moderate-good level (0.53), and intra-rater Kappa coefficients for the first and second observers were at a good-very good level (0.92 and 0.77, respectively). Similar studies have shown very good inter-rater and intra-rater Kappa coefficients (1,13,28,29). Sinanoglu *et al* (1) reported inter-rater agreement of 0.79-0.82 and intra-rater agreement of 0.72-0.78. Also, Kocasarac *et al* (13) reported inter-rater and intra-rater agreements of 0.88 and 0.93, respectively. Fernández-Pérez *et al* (29) showed the inter-rater and intra-rater agreements of 0.92, which was very good. Bassed *et al* (25) reported inter-rater and intra-rater agreements of 0.78 and 0.90, respectively. It is noteworthy that in addition to the study population, different CBCT machines as well as the experience of observers can be the

factors associated with different results obtained in the present study compared to other studies. Although the present study used the census method to collect all data for age, the study sample was lower than those of other studies in various countries. Furthermore, considering the diversity of ethnicities in Iran, similar multi-central studies are suggested.

## Conclusion

The four-stage spheno-occipital synchronosis development was not a robust method for age estimation in the 7-25-year-old Iranian population. However, it can be an appropriate marker when complemented with third molar development (Demirjian index).

## Acknowledgements

The Vice Chancellery of Research and Technology at Isfahan University of Medical Sciences in Iran provided financial support for this study (Grant# 396880). Ethical approval of the present study was obtained from the local research ethics committee IR.MUI.REC.1396.3.880).

## Conflict of Interest

The authors state that there are no conflicting financial, professional, or personal interests that could have impacted the execution or delivery of the research outlined in this manuscript.

## References

1. Sinanoglu A, Kocasarac HD, Noujeim M. Age estimation by an analysis of spheno-occipital synchronosis using cone-beam computed tomography. *Leg Med (Tokyo)* 2016;18:13-9.
2. Prasad BK, Kumar P, Tyagi YK. Age determination: In relation to specific demands of forensic practice. *Anil Aggrawal's Internet J Forensic Med Toxicol* 2007;4:2.
3. Can IO, Ekizoglu O, Hocaoglu E, Inci E, Sayin I, Kaya KH. Forensic age estimation by spheno-occipital synchronosis fusion degree: computed tomography analysis. *J Craniofac Surg* 2014;25(4):1212-6.
4. Manjunatha B, Soni NK. Estimation of age from development and eruption of teeth. *J Forensic Dent Sci* 2014;6(2):73.
5. Serinelli S, Panetta V, Pasqualetti P, Marchetti D. Accuracy of three age determination X-ray methods on the left hand-wrist: a systematic review and meta-analysis. *Leg Med (Tokyo)* 2011;13(3):120-33.
6. Milenkovic P, Djuric M, Milovanovic P, Djukic K, Zivkovic V, Nikolic S. The role of CT analyses of the sternal end of

the clavicle and the first costal cartilage in age estimation. *Int J Legal Med* 2014;128(5):825-39.

7. Schulze D, Rother U, Fuhrmann A, Richel S, Faulmann G, Heiland M. Correlation of age and ossification of the medial clavicular epiphysis using computed tomography. *Forensic Sci Int* 2006;158(2):184-9.

8. Savall F, Hérin F, Peyron PA, Rougé D, Baccino E, Saint-Martin P, et al. Age estimation at death using pubic bone analysis of a virtual reference sample. *Int J Legal Med* 2017:1-7.

9. Saint-Martin P, Rérolle C, Dedouit F, Bouilleau L, Rousseau H, Rougé D, et al. Age estimation by magnetic resonance imaging of the distal tibial epiphysis and the calcaneum. *Int J Legal Med* 2013;127(5):1023-30.

10. Chiba F, Makino Y, Motomura A, Inokuchi G, Torimitsu S, Ishii N, et al. Age estimation by multidetector CT images of the sagittal suture. *Int J Legal Med* 2013;127(5):1005-11.

11. Navega D, Coelho JdO, Cunha E, Curate F. DXAGE: a new method for age at death estimation based on femoral bone mineral density and artificial neural networks. *J Forensic Sci* 2018 Mar;63(2):497-503.

12. Alghanim H, Antunes J, Silva DSBS, Alho CS, Balamurugan K, McCord B. Detection and evaluation of DNA methylation markers found at SCGN and KLF14 loci to estimate human age. *Forensic Sci Int Genet* 2017;31:81-8.

13. Kocasarac HD, Sinanoglu A, Noujeim M, Yigit DH, Baydemir C. Radiologic assessment of third molar tooth and spheno-occipital synchondrosis for age estimation: a multiple regression analysis study. *Int J Legal Med* 2016;130(3):799-808.

14. Bassed RB, Briggs C, Drummer OH. Age estimation using CT imaging of the third molar tooth, the medial clavicular epiphysis, and the spheno-occipital synchondrosis: a multifactorial approach. *Forensic Sci Int* 2011;212(1-3):273.e1-5.

15. Lei WY, Wong RW, Rabie A. Factors regulating endochondral ossification in the spheno-occipital synchondrosis. *Angle Orthod* 2008;78(2):215-20.

16. Franklin D, Flavel A. Brief Communication: Timing of spheno-occipital closure in modern Western Australians. *Am J Phys Anthropol* 2014;153(1):132-8.

17. Hayashi I. Morphological relationship between the cranial base and dentofacial complex obtained by reconstructive computer tomographic images. *Eur J Orthod* 2003;25(4):385-91.

18. Loubele M, Bogaerts R, Van Dijck E, Pauwels R, Vanheusden S, Suetens P, et al. Comparison between effective radiation dose of CBCT and MSCT scanners for dentomaxillofacial applications. *Eur J Radiol* 2009;71(3):461-8.

19. De Vos W, Casselman J, Swennen G. Cone-beam computerized tomography (CBCT) imaging of the oral and maxillofacial region: a systematic review of the literature. *Int J Oral Maxillofac Surg* 2009;38(6):609-25.

20. Schmeling A, Grundmann C, Fuhrmann A, Kaatsch H-J, Knell B, Ramsthaler F, et al. Criteria for age estimation in living individuals. *Int J Legal Med* 2008;122(6):457.

21. Shirley NR, Jantz RL. Spheno-occipital synchondrosis fusion in modern Americans. *J Forensic Sci* 2011;56(3):580-5.

22. El-Sheikh M, Ramadan S. Age of closure of the spheno-occipital synchondrosis in the Arabian Gulf region. *Proc Ann Meet Am Acad Forensic Sci* 2002.

23. Demirjian A, Goldstein H, Tanner JM. A new system of dental age assessment. *Hum Biol* 1973:211-27.

24. Landis J, Koch G. The measurement of observer agreement for categorical data. *Biometrics* 1977;33(1):159-74.

25. Bassed RB, Briggs C, Drummer OH. Analysis of time of closure of the spheno-occipital synchondrosis using computed tomography. *Forensic Sci Int* 2010;200(1):161-4.

26. Akhlaghi M, Taghaddosinejad F, Sheikhzadi A, Valizadeh B, Shojaei SMR. Age-at-death estimation based on the macroscopic examination of spheno-occipital sutures. *J Forensic Leg Med* 2010;17(6):304-8.

27. Akhlaghi M, Valizadeh B, Gharedaghi j. Closure time of spheno-occipital suture in the male cadavers referred to



legal medicine organization of Iran. *Acta Medica Iranica* 2008;4.

28. Akhlaghi M, Rezazadeh Shojaie SM, Yaghmaie A, Mehrpor O, Valizadeh B. Closure time of spheno-occipital suture in the female cadavers referred to legal medicine organization of Iran. *Iran J Forensic Med* 2009;14(4):209-14.

29. Fernández-Pérez MJ, Alarcón JA, McNamara Jr JA, Velasco-Torres M, Benavides E, Galindo-Moreno P, et al. Spheno-occipital synchondrosis fusion correlates with cervical vertebrae maturation. *PloS One* 2016;11(8):e0161104.