

Concurrent Lead and Noise Exposure Effects on Testicular Tissue of Rat: An Experimental Study

Batol Masruri; MSc¹, Iraj Alimohammadi; Ph.D.², Mohammad Reza Abyaz; Ph.D.³, Nargess Moghadasi; MSc², Parvaneh Yekzamani; MSc², Baharak Mohammadzadeh Asi; MSc⁴, Nooshin Asadmasjedi; Ph.D.⁵, Azadeh Ashtarinezhad; Ph.D.²

1 Student Research Committee, School of Health, Iran University of Medical Sciences, Tehran, Iran

2 Department of Occupational Health Engineering, School of Health, Iran University of Medical Sciences, Tehran, Iran

3 Department of Pathology, School of Medicine, Dezful University of Medical Sciences, Dezful, Iran

4 Department of Pharmacology and Toxicology, Faculty of Pharmacy, Shahid Beheshti University of Medical Sciences, Tehran, Iran

5 Department of Medical Laboratory Sciences, School of Paramedical Sciences, Dezful University of Medical Sciences, Dezful, Iran

Received November 2021; Revised and accepted April 2022

Abstract

Objective: Environmental stressors such as physical and chemical factors can have a destructive testicular function. The present study aimed to determine the effect of concomitant exposure to lead and noise on testicular tissue in male rats.

Materials and methods: Twenty male Wistar rats (250-300 g, 12-13wk) were divided into four groups (n=5/each): 1) Control group, 2) Lead group treated with 4 mg/kg lead acetate by gavage for 30 days, 3) Noise group exposed to 4 kHz octave band at 105 dBA for eight hrs./ day for 30 days, and 4) the exposed group to lead plus noise concurrently. The testes' weight was measured, and testes abnormalities were assessed after staining with Hematoxylin and Eosin.

Results: The results showed that the weight of testes in experimental groups was significantly decreased compared with the control group ($p < 0.0001$). Also indicated edema, degeneration and necrotic cell debris in the lumen, congestion and atrophy of seminiferous tubule in rat testes tissue due to sub-acute exposure to lead and noise.

Conclusion: Exposure to 105 dB and lead can cause damage to the seminiferous tubules, intubation edema, and testicular weight loss compared to control. We also found that simultaneous exposure to noise and lead could have more detrimental effects on testicular histology and weight than others.

Keywords: Lead Acetate; Noise, Testis; Rat; Infertility

Introduction

Stress is a growing public health issue and seems to

have both health and psychological effects. Exposure to stressors such as physical and chemical factors by affect the axis of the hypothalamus-pituitary-gonad causes infertility disorders and destructive effects on testicular function (1-3).

Noise is one of the most harmful and unavoidable

Correspondence:

Dr. Azadeh Ashtarinezhad

Email: azadeh_ashtarinezhad@yahoo.com



Copyright © 2022 Tehran University of Medical Sciences. Published by Tehran University of Medical Sciences.

This work is licensed under a Creative Commons Attribution-NonCommercial 4.0 International license (<https://creativecommons.org/licenses/by-nc/4.0/>).

Noncommercial uses of the work are permitted, provided the original work is properly cited.

physical factors in the workplace, and according to the Ministry of Health's Center for Health and Workplace, more than 2 million workers in Iran are exposed to harmful occupational noise. Noise stress has adverse effects on the human body, such as cardiovascular disorders, hearing loss, reduced mental efficiency, and can affect the hormonal system (4, 5).

Some studies by evaluating testosterone and spermatogenesis level, Luteinizing hormone (LH) and follicle stimulating hormone (FSH), sperm count, morphology, viability have shown that noise-induced stress could affect the structure of testicular tissue (2, 6, 7). Long-term exposure to noise-induced stress seems to have adverse effects on male fertility based on increased apoptosis due to pathogenesis stress (noise and lead) and suppression of spermatogenesis kinetics (7, 8).

Among toxic chemicals, metals are considered important environmental toxins due to their biodegradability and non-degradability properties and are harmful to environmental systems (9). Lead is one of the most persistent environmental pollutants, and due to its everyday use in various industrial products, it is one of the essential heavy metals and a serious occupational hazard worldwide (10, 11). Humans can be exposed to metal by eating contaminated food, water, or soil (12). Exposure to lead causes a wide range of physiological, biochemical, and behavioral disorders and testicular dysfunction (for example, affects the testes' weight, sperm concentration, morphology, and motility) (13-16). Production of reactive oxygen species (ROS) is a probable mechanism that was considered for the detrimental effect of lead. Lead can accumulate in organs and change their biological activity via oxidative stress. The testis is very sensitive to oxidative stress due to its unsaturated fatty acids (17). Noise and lead appear to cause oxidative stress in various tissues, including the testes, by disturbing the balance of the prooxidant/antioxidant system (18, 19).

Given that so far, few studies conducted to investigate the cumulative effects of noise and lead on testicular tissue, and most studies have examined chronic and sub-chronic effects, this study aimed to investigate the Concurrent effect of sub-acute exposure to noise and lead on testicular tissue in male rats.

Materials and methods

Study design and animals: Twenty healthy male Wistar rats (weight 250-300 gr, 12-13 wk) were used for the experiment and obtained from the

Experimental and Comparative studies center, Iran University of Medical Science, Tehran, Iran. The animals were housed in the temperature and light-controlled room (23 ± 1 °C, and 12-hr dark/ light cycle) and 40-50 % relative humidity with free access to standard food and water and accustomed for one week before the study. Lead acetate powder was purchased from MERCK Co. Germany (CAS: 107375).

Rats were randomly divided into four groups (n=5 in each group) as below:

Group 1: control; the animals received anything.

Group 2: rats were treated with lead acetate (4 mg/kg; lead acetate solution made by distilled water) by gavage for 30 days (20).

Group 3: rats were exposed to a 4 kHz octave band at 105 dBA for eight hrs/ day (occupational exposure) for 30 days.

Group 4: the animals were exposed to lead by gavage (4 mg/kg) plus noise (4 kHz octave band at 105 dBA for eight hrs/ day) for 30 days.

Noise exposure: Noise exposure room was applied in dimensions of 80*80*95, and ten rats could concurrently live inside it comfortably. The chamber temperature was adjusted to 22°C using a temperature control device. Noise 105 ± 1 dB with 4 kHz frequency generated by the signal software and played by cool edit pro V.21 and animals in groups 3 and 4 were exposed to this noise for eight hrs/day, six days/wk, for four next wks (groups 1 and 2 were kept in similar conditions with a difference that the noise did not exceed 60 dB). The noise was amplified and played by two speakers (Venous-SU132) located in the room's ceiling at equal distances four holes, placed on the center of sidewalls to monitor the chamber condition (21). The noise level was measured using a sound level meter model CEL-400 through holes made on every side of the chamber.

Sample preparation: Rats were sacrificed after 30 days. The weight of testes was measured by digital balance (Shimadzu, Japan, LIBROR AEL-200), dissected the left testes tissue, and fixed with 10% formalin. Samples were then provided using a graded ethanol series and embedded in paraffin. Sections (10µm) have been stained with Hematoxylin and Eosin (H & E) (Sigma, USA) stains for histological examination (2). The morphological alterations in tissue such as intertubular edema, atrophy of the seminiferous tubule, degeneration, and necrotic cell were evaluated. Photomicrographs were taken by light microscope (Labomed, Cx L, USA) at a magnification of 40X & 100X.

Ethical consideration: All investigations of animals were carried out with the guidelines of the Ethical Committee of Iran University of Medical Sciences (IR.IUMS.REC.1397.121).

Statistical analysis: All the statistical analyzes were carried out using SPSS (Version 22.0, SPSS Inc., Chicago, IL, USA). Kolmogorov-Smirnov test was used to assay the normal distribution of data. One-way ANOVA and the Tukey test were applied for comparisons among the groups. P-value <0.05 was considered significant. The results were presented as mean± SD.

Results

There were considerable differences in the weight of testes between all experimental groups. The findings of the present study indicated the weight of testes in the noise plus lead group (p-value< 0.0001) was significantly less than in the lead and noise groups (Figure 1).

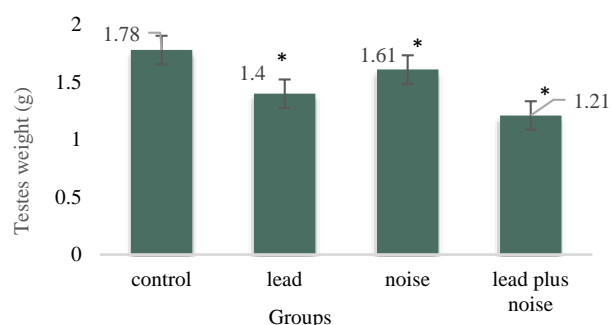


Figure 1: Comparison of the effect of sub-acute lead plus noise exposure on testis weight (N= 5 each group). Data presented as mean±SD. One-way ANOVA and the Tukey test were applied. *p-value < 0.0001

Microscopic Description: Figure 2 reveals the histopathological changes of the testes in experimental groups. The control group is shown to have a well-preserved lobules structure in which each lobule contains four seminiferous tubules embedded in a connective tissue stroma (A). There are mild to moderate congestion, intertubular edema, and a few degenerations and necrotic cell, debris in the lumen (B & C) in the lead, and noise groups. Also, there are extensive damages to testicular tissue, such as moderate or severe congestion, atrophy of seminiferous tubule necrotic cells debris in the lumen, and intertubular edema (D) in the Noise plus Lead group (Table 1).

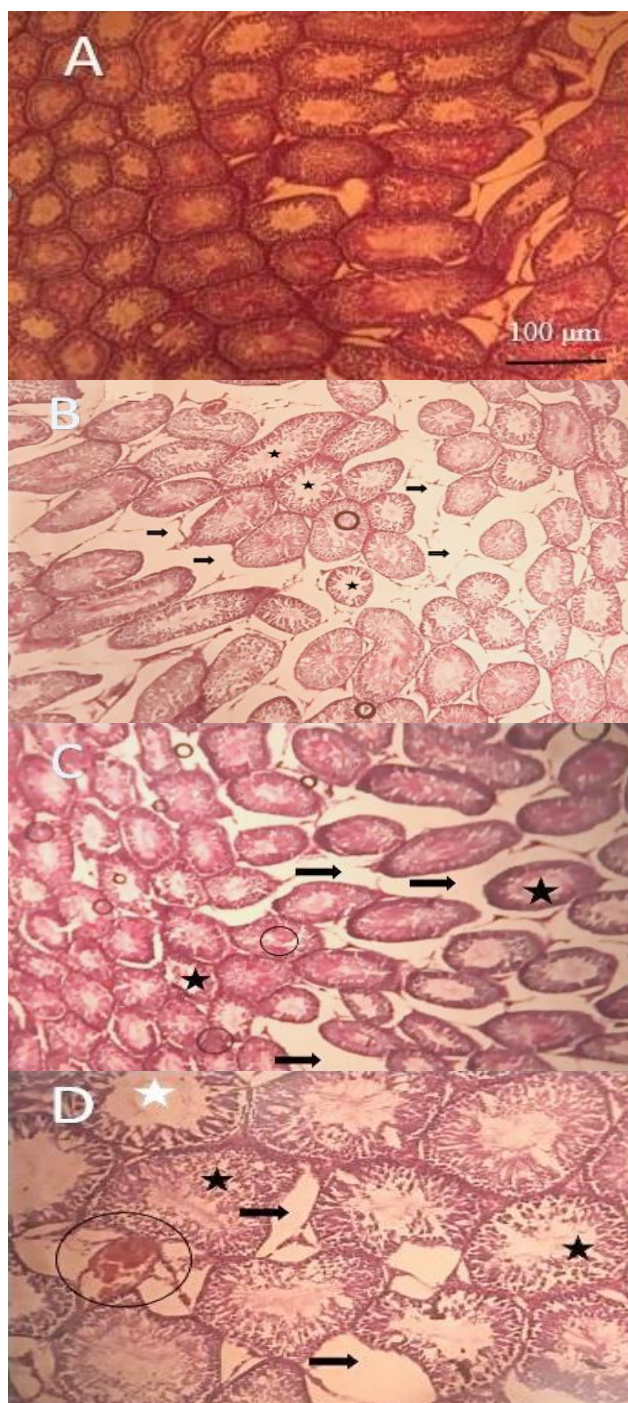


Figure 2: Histopathological changes of Lead and Noise in rats' testis tissue. (A) The Control group reveals normal testicular histology (40X); (B) Lead group shows intertubular edema (Arrows), degeneration (circle), and necrotic cell debris in the lumen (star) (40X); (C) Noise group shows intertubular edema (Arrows), degeneration (circle) and necrotic cell debris in the lumen (star) (40X); (D) In the Noise plus Lead group shows severe congestion (circle), atrophy of seminiferous tubule (white star), necrotic cell debris in the lumen (black star) and intertubular edema (Arrows) (100X).

Table 1: Histological alteration in testis after lead and noise exposure

Groups	Histological changes in testis tissue
Control	Normal
Lead	Edema, degeneration and necrotic cell debris in the lumen
Noise	Edema, degeneration and necrotic cell debris in the lumen
Lead plus noise	Severe congestion, atrophy of seminiferous tubule, necrotic cell debris in lumen and edema

These pathologic changes were diagnosed by hyperemia in blood vessels (congestion), increased distance between tubules (intertubular edema), structural abnormality (degenerations), cells without nuclei (necrotic cell), fragments of a necrotic cell (debris), and thinning of seminiferous tubule walls (atrophy).

Discussion

The testis is a dual organ and the main reproductive organ in men with endocrine function (22, 23). Environmental factors such as physical and chemical agents can have a destructive testicular function (2, 3). Among environmental pollutants, noise is one of the most common natural pollutants and an inevitable factor at home and the workplace (24). Several studies have reported that vocal stress can have structural and functional adverse effects on testicular tissue (25, 26). Due to the industrialization and development of urbanization, there is a growing concern about the adverse effects of metals on the male reproductive system (27).

Lead is an abundant toxic metal in the environment (28), and exposure to it has increased due to its widespread use in industry, cosmetics, and medicine (29). Lead has no recognizable biologically beneficial role, but on the contrary, its destructive effects on humans and animals have been proven by several researchers (30, 31). Even at low levels, exposure to lead can affect male fertility (8). Reports suggest that lead may damage testicular tissue by producing free radicals and thus increasing lipid peroxidation (32). This study investigated the simultaneous effects of noise and lead exposure on the testis tissues.

The present study results showed that testis weight in the noise exposure group was significantly reduced compared to the control group (Figure 1), which is in line with the previous studies (33, 34). It is determined that androgen hormones regulate the weight of genital organs, and it seems noise-induced stress by impaired hormones regulation could cause loss of weight (2, 7).

There are conflicting results about the effects of lead on testicular weight. One study reported a

significant increase in testicular weight (35); on the other hand, the other studies reported a significant decrease (36, 37) or no change in weight (38). This difference may be due to differences in the exposure pathway, lead dose, age, etc. According to the results of this study, exposure to lead acetate caused a significant reduction in testicular weight in the lead exposure group compared to the control group (Figure 1), the results of which are in line with the study by Dorostghoal et al. (39).

Also, in this study, we found that testicular weight in the group exposed to noise plus lead has a significant decrease compared to the other groups (Figure 1). One of the probable reasons for more decreasing testis weight in this group is the additive effect of lead and noise.

Usually, antioxidant defense systems in reproductive tissues prevent oxidative damage in spermatogenesis (38). Studies have shown that noise and lead increase the production of free radicals by reducing or inhibiting the activity of antioxidant enzymes, thereby destroying the layers of sperm-producing cells (4, 40).

Histological examinations of testicular specimens are shown in Figure 2 and Table 1. The control group (A) shows the typical organization of the seminiferous tubules associated with arranged germinal lineage and the spermatids inside the tubes. Spermatogenic cells are characterized by dark nuclei, while serotonin cells are characterized by pale cells.

Connective tissue and interstitial cells are also commonly seen between tubes. Some pathological changes are observed in the experimental groups. Histological assessments show that exposed groups lack natural structure in seminiferous tubules. The thickness of the allogeneic tonic and the diameter of the seminiferous tubules decreased significantly in the study groups. Interstitial connective tissue and the number of Leydig cells are significantly reduced, indicating severe tissue damage (arrows).

In agreement with the present study results, two studies have shown that exposure to lead causes damages to the seminiferous tubules and interstitial connective tissue (36, 41). In addition, a study on

lead-exposed mice showed degeneration of the seminiferous tubules (42). In line with this study, a study also showed that the number of Leydig cells decreased in lead-exposed mice (36). In the other study Damage to the seminiferous tubules was observed in mice exposed to sound, which is in line with the present study (43). Another study also showed damage to the seminiferous tubules and interstitial space in fetuses of mice exposed to vocal stress (7).

Other degenerative effects on sperm tubes include the destruction of the germination layer in the experimental groups (shown with a star). In addition, moderate to severe damage, deficiency, or reduction in spermatid count were observed in some tubes in group D (shown with a circle). Atrophy of the seminiferous tubules is also seen in exposure to noise and lead (D) (white star).

One study showed that exposure to lead for 5 and 10 wk causes irregularity, degeneration, and atrophy in most seminiferous tubules, increases interstitial space and reduces Leydig cells, which agrees with the findings of the present study (37). Also, in line with the results of this study, the other study showed that exposure to 115 dB noise causes damage to the seminiferous tubules, atrophy of the germinal epithelium, and increased connective tissue between the tubes (2). There are some limitations in our study such as failure of the noise generation system, animal death, shortage of examination equipment and financial support, to examine the male hormones, sperm count, and motility.

Conclusion

That said, exposure to 105 dB and lead could cause damage to the seminiferous tubules, intubation edema, and testicular weight loss compared to controls. We also found that simultaneous exposure to noise and lead could have more detrimental effects on testicular histology and weight than other groups. These findings could be helpful for people who are exposed to noise and lead at work. It is recommended to use different sound levels and doses of lead in future studies. Also, examination of tissue changes in the fetus and female reproductive organs, examining the male hormones, sperm count, and motility is suggested.

Conflict of Interests

Authors have no conflict of interests.

Acknowledgments

This study was supported by the student research

committee, Iran University of Medical Sciences (Grant No.32700). The authors would like to thank all the colleagues helping in this project, the Experimental and Comparative Studies Center's assistants, and their technical supports at the Iran University of Medical Sciences.

References

1. Singh A, Sharma R. Effects of stress on epididymis in albino rat. *Int J Med Clin Res* 2011; 2: 20-1.
2. Farzadinia P, Bigdeli M, Akbarzadeh S, Mohammadi M, Daneshi A, Bargahi A. Effect of noise pollution on testicular tissue and hormonal assessment in rat. *Andrologia* 2016; 48: 869-73.
3. Camille Melón L, Maguire J. GABAergic regulation of the HPA and HPG axes and the impact of stress on reproductive function. *J Steroid Biochem Mol Biol* 2016; 160: 196-203.
4. Nadri F, Khavanin A, Mazaheri Z, Khajehnasiri F. The effect of noise stress on adult male rat sperm parameters and the protective effect of hydroalcoholic Cinnamomum verum extract: an experimental study. *IRANIAN RED CRESCENT MEDICAL JOURNAL (IRCMJ)* 2018; 20: e69779.
5. Golmohammadi R, Giahi O, Aliabadi M, Darvishi E. An intervention for noise control of blast furnace in steel industry. *J Res Health Sci* 2014; 14: 287-90.
6. Swami CG, Ramanathan J, Charan Jeganath C. Noise exposure effect on testicular histology, morphology and on male steroidogenic hormone. *Malays J Med Sci* 2007; 14:28-35.
7. Jalali M, Hemadi M, Saki G, Sarkaki A. Study of spermatogenesis fetal testis exposed noise stress during and after natal period in rat. *Pak J Biol Sci* 2013; 16: 1010-5.
8. El-Magd MA, Kahilo KA, Nasr NE, Kamal T, Shukry M, Saleh AA. A potential mechanism associated with lead-induced testicular toxicity in rats. *Andrologia* 2017; 49.
9. Apaydin FG, Kalender S, Bas H, Demir F, Kalender Y. Lead nitrate induced testicular toxicity in diabetic and non-diabetic rats: protective role of sodium selenite. *Brazilian Archives of Biology and Technology* 2015; 58: 68-74.
10. Ahmed YF, Eldebaky HAA, Mahmoud KG, Nawito M. Effects of lead exposure on DNA damage and apoptosis in reproductive and vital organs in female rabbits. *Global veterinaria* 2012; 9: 401-8.
11. Andjelkovic M, Buha Djordjevic A, Antonijevic E, Antonijevic B, Stanic M, Kotur-Stevuljevic J *et al.*

- Toxic effect of acute cadmium and lead exposure in rat blood, liver, and kidney. *Int J Environ Res Public Health* 2019; 16: 274.
12. Ericson B, Landrigan P, Taylor MP, Frostad J, Caravanos J, Keith J, *et al.* The global burden of lead toxicity attributable to informal used lead-acid battery sites. *Ann Glob Health* 2016; 82: 686-99.
 13. Manoj Kumar V, Henley AK, Nelson CJ, Indumati O, Prabhakara Rao Y, Rajanna S, *et al.* Protective effect of *Allium sativum* (garlic) aqueous extract against lead-induced oxidative stress in the rat brain, liver, and kidney. *Environ Sci Pollut Res Int* 2017; 24: 1544-52.
 14. I-Tantawy WH. Antioxidant effects of *Spirulina* supplement against lead acetate-induced hepatic injury in rats. *J Tradit Complement Med* 2015; 6: 327-31.
 15. Alimohammadi I, Ashtarinezhad A, Abolghasemi J, Yekzamani P, Masruri B. The Sub-acute Effect of Lead Exposure on the Auditory Brainstem Response in Male Rats. *Iranian Journal of Toxicology* 2019; 13: 9-13.
 16. Fahim MA, Tariq S, Adeghate E. Vitamin E modifies the ultrastructure of testis and epididymis in mice exposed to lead intoxication. *Ann Anat* 2013; 195: 272-7.
 17. Kumar SR, Devi AS. Lead toxicity on male reproductive system and its mechanism: a review. *Research Journal of Pharmacy and Technology* 2018; 11: 1228-32.
 18. Halliwell B. Free radicals and antioxidants: updating a personal view. *Nutr Rev* 2012; 70: 257-65.
 19. Masruri B, Ashtarinezhad A, Yekzamani P. Data on the effect of lead concomitant noise on oxidative stress in rats. *Data Brief* 2018; 18: 1117-21.
 20. Liu S, Zhang K, Wu S, Ji X, Li N, Liu R, *et al.* Lead-induced hearing loss in rats and the protective effect of copper. *Biological trace element research* 2011; 144: 1112-9.
 21. Haghighat M, Allameh A, Fereidan M, Khavanin A, Ghasemi Z. Effects of concomitant exposure to styrene and intense noise on rats' whole lung tissues. *Biochemical and histopathological studies. Drug Chem Toxicol* 2022; 45: 120-6.
 22. Shaha C, Tripathi R, Mishra DP. Male germ cell apoptosis: regulation and biology. *Philos Trans R Soc Lond B Biol Sci* 2010; 365: 1501-15.
 23. Cao Y, Wang D, Li Q, Deng H, Shen J, Zheng G, *et al.* Rat testis damage caused by lead sulfide nanoparticles after oral exposure. *J Nanosci Nanotechnol* 2016; 16: 2378-83.
 24. World Health Organization. Regional Office for Europe. Burden of disease from environmental noise: quantification of healthy life years lost in Europe. World Health Organization. Regional Office for Europe. 2011
 25. Pramanik P, Biswas S. Traffic noise: a silent killer of male gamete of albino rats. *Al Ameen J Med Sci* 2012; 5: 82-9.
 26. Chen Cárdenas S, Mayer N, Romanini M, Rolando A, Liaudat A, Brun N, *et al.* Reproductive response in offspring male rats exposed to prenatal stress and to early postnatal stimulation. *International Journal of Morphology* 2013; 31: 754-64.
 27. Garu U, Sharma R, Barber I. Effect of lead toxicity on developing testis of mice. *International Journal of Pharmaceutical Sciences and Research* 2011; 2: 2403.
 28. Patra RC, Rautray AK, Swarup D. Oxidative stress in lead and cadmium toxicity and its amelioration. *Vet Med Int* 2011; 2011: 457327.
 29. Kasperczyk A, Dobrakowski M, Czuba ZP, Horak S, Kasperczyk S. Environmental exposure to lead induces oxidative stress and modulates the function of the antioxidant defense system and the immune system in the semen of males with normal semen profile. *Toxicol Appl Pharmacol* 2015; 284: 339-44.
 30. Ruff HA, Markowitz ME, Bijur PE, Rosen JF. Relationships among blood lead levels, iron deficiency, and cognitive development in two-year-old children. *Environ Health Perspect* 1996; 104: 180-5.
 31. Aksu D, Sağlam Y, Yildirim S, Aksu T. Effect of pomegranate (*Punica granatum L.*) juice on kidney, liver, heart and testis histopathological changes, and the tissues lipid peroxidation and antioxidant status in lead acetate-treated rats. *Cell Mol Biol (Noisy-le-grand)* 2017; 63: 33-42.
 32. Mustafa HN. Potential alleviation of *Chlorella vulgaris* and *Zingiber officinale* on lead-induced testicular toxicity: an ultrastructural study. *Folia Biol (Krakow)* 2015; 63: 269-78.
 33. Babisch W. Transportation noise and cardiovascular risk: updated review and synthesis of epidemiological studies indicate that the evidence has increased. *Noise Health* 2006; 8: 1-9.
 34. Chehrie S, Rabzia A, Farhadi-mesterkhani M. Maternal Water Deprivation Affects the Spermatogenesis of the Offspring Rats. *International Journal of Morphology* 2013; 31: 156-61.
 35. Ma L, Liu J, Li N, Wang J, Duan Y, Yan J, *et al.* Oxidative stress in the brain of mice caused by translocated nanoparticulate TiO₂ delivered to the abdominal cavity. *Biomaterials* 2010; 31: 99-105.
 36. Hasanein P, Fazeli F, Parviz M, Roghani M. Ferulic acid prevents lead-induced testicular oxidative stress

- and suppressed spermatogenesis in rats. *Andrologia* 2018; 50: e12798.
37. Ali S, Al-Dervi KH, Al Monsour NAA. Testicular toxic effect of lead acetate on adult male rats and the potential protective role of alcoholic extract of ginseng (histological, histomorphometrical and physiological). *Scientific Journal of Medical Research* 2018; 2: 87-92.
38. Modaresi M, Messripour M, Rajaei RA. Effect of cinnamon extract on the number of spermatocyte and spermatozoa cells in mice. *Iranian Journal of Medicinal and Aromatic Plants* 2010; 26: 83-90.
39. Dorostghoal M, Seyyednejad SM, Jabari A. Protective effects of *Fumaria parviflora* L. on lead-induced testicular toxicity in male rats. *Andrologia* 2014; 46: 437-46.
40. Saxena DK, Srivastava RS, Lal B, Chandra SV. The effect of lead exposure on the testis of growing rats. *Exp Pathol* 1987; 31: 249-52.
41. Moniem AEA, Dkhil MA, Al-Quraishy S. Protective role of flaxseed oil against lead acetate induced oxidative stress in testes of adult rats. *African Journal of Biotechnology* 2010; 9: 7216-23.
42. Graça A, Ramalho-Santos J, de Lourdes Pereira M. Effect of lead chloride on spermatogenesis and sperm parameters in mice. *Asian J Androl* 2004; 6: 237-41.
43. Pirami H, Khavanin A, Mazaheri Z, Nadri F. The protective effect of cinnamon hydroalcoholic extract on testicular tissue changes and fertility capacity in male rats exposed to noise stress. *Journal of Birjand University of Medical Sciences* 2018; 25: 21-30.

Citation: Masruri B, Alimohammadi I, Abyaz MR, Moghadasi N, Yekzamani P, Mohammadzadeh Asl B, et al. **Concurrent Lead and Noise Exposure Effects on Testicular Tissue of Rat: An Experimental Study.** *J Family Reprod Health* 2022; 16(2): 132-8.