

# Challenging Vaginal Discharge, Lactobacillosis and Cytolytic Vaginitis

Gary Ventolini; M.D.<sup>1</sup>, Kushal Gandhi; Ph.D.<sup>1</sup>, Nathan Joshua Manales; B.S.<sup>1</sup>,  
John Garza; Ph.D.<sup>1,2</sup>, Asley Sanchez; B.S.<sup>1</sup>, Brianna Martinez; B.S.<sup>1</sup>

1 Texas Tech University Health Sciences Center at the Permian Basin, Odessa, Texas, USA

2 The University of Texas Permian Basin, Odessa, Texas, USA

Received November 2021; Revised and accepted April 2022

## Abstract

In women's health, clinicians are often faced with diagnosing and administering treatment to patients who present with an increased vaginal discharge without much other information to work with. It's only once a patient's background is reviewed and lab work is completed that two common reasons behind vaginal discharge with similar symptoms, Lactobacillosis and Cytolytic Vaginitis, can be differentiated and a proper diagnosis can be reached.

Now, we understand that Lactobacillosis and Cytolytic Vaginitis are symptomatically confused by patients as well as inexperienced clinicians. Lactobacillosis involves the presence of abnormal, extremely long Lactobacilli, a keystone species for vaginal health, while Cytolytic Vaginitis mainly involves, increased Lactobacilli, pH between 3.5 and 4.5, presence of cytolysis, and a lowered white blood cell count.

Both present with similar discharge, leading to their conflation. A microscopic examination of the discharge using a wet mount with normal saline can provide 80% diagnostic sensitivity until further testing can be completed.

**Keywords:** Lactobacillus; Microbiota; Vaginitis; Vaginal Discharge

## Introduction

Increased vaginal discharge is the most common reason for women to seek health care advice (1). Establishing a correct diagnosis for symptomatic patients complaining about increased vaginal discharge is a challenge when based only on symptoms and without a proper workup. Analysis of increased vaginal discharge may be completed after obtaining a thorough medical history, review of hygiene practices, a problem-focused physical examination, and targeted laboratory testing (2, 3).

The collection, preparation, identification, and culture of vaginal specimens are necessary components for successful diagnosis and treatment. Properly performed vaginal wet mount microscopy can be achieved with 80% diagnostic sensitivity in office settings (3). However, two challenging vaginal discharges that puzzle the clinician: Lactobacillosis and Cytolytic Vaginitis.

### Physiologic Vaginal Environment

The vaginal microbiome of healthy and childbearing age women is approximately 90% composed of *Lactobacillus* species. It is important to recognize that women will normally produce between 1.6 g to 4.8 g of vaginal discharge per day. This discharge includes vaginal epithelial cells that

### Correspondence:

Dr. Gary Ventolini

Email: gary.ventolini@ttuhsc.edu



Copyright © 2022 Tehran University of Medical Sciences. Published by Tehran University of Medical Sciences.


This work is licensed under a Creative Commons Attribution-NonCommercial 4.0 International license (<https://creativecommons.org/licenses/by-nc/4.0/>).

Noncommercial uses of the work are permitted, provided the original work is properly cited.

provide *Lactobacilli* with a physiologic environment to thrive. Vaginal transudate also prevents dryness, helps to protect against infections, and includes cervical mucous (with immune globulins), Skene, and Bartholin Gland secretions required for normal vaginal function during the reproductive years (2-4).

*Lactobacilli* shield the vaginal ecosystem from bacterial pathogens, but also partially from fungi and viruses. *Lactobacilli* achieve these functions through the production of lactic acid, hydrogen peroxide, bacteriocins, bio-surfactants, hydroxyl radicals, organic acids, and arginine deaminases (5). The number of *Lactobacilli* present in the vagina can be estimated utilizing the Spiegel scale: that runs from 0 to 4 (none = 0, rare = 1, few = 2, moderate = 3, many = 4) (2-4).

The specific mechanisms causing dysfunction in the vaginal ecosystem, are complex. Amongst the factors involved in vaginal dysbiosis, pH, and balanced female hormone levels seem to be critical. The vaginal pH is acidic in most women and is strongly dependent on the presence of functionally normal *Lactobacilli* that will maintain a pH between 3.8 and 4.2. The vaginal fluid of women with healthy vaginas normally indicates a prevalence of *Lactobacilli* microflora composed of *L. crispatus*, *L. gasseri*, *L. jensenii*, and *L. iners* (5) (Figure 1).



**Figure 1:** Differentiation of *Lactobacilli*. Black: *L. gasseri*, Red: *L. crispatus*, White: *L. jensenii*, and Blue: *L. iners*

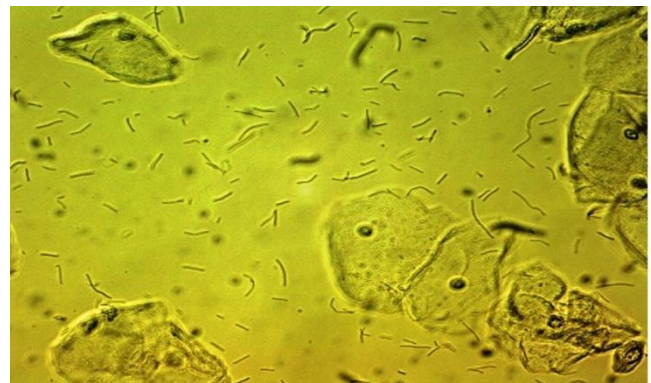### Vaginal Lactobacillosis

Vaginal Lactobacillosis (VL) is a cyclical clinical condition that was first reported by Horowitz *et al.* in 1994. VL presents as an annoying and copious white vaginal discharge leading to an impression by the patient of unremittingly having wet underwear (6). After prospectively studying 30 controls and 37 patients with a clinical condition characterized by profuse and bothersome vaginal discharge, Horowitz *et al.* called the condition VL. Horowitz concluded

that it was associated with extremely long *Lactobacilli* seen in the microscope but reported that the cause of the morphologic transformation observed in the *Lactobacilli* was unknown. Horowitz suggested that the condition could be effectively treated with antibiotics (6). In 1994, Kaufmann *et al.* demonstrated that *Leptothrix* associated with VL are nonbranching, segmented, and gram-positive anaerobic rods that are longer than *Lactobacilli* but shorter than *Candida* filaments (7).

Feo *et al.* had classified them before in the *Lactobacillus* genus based on their biochemical and cultural properties. In vaginal wet mount preparations, the microscope examination of vaginal discharge from patients with VL is characterized by the presence of plentiful, normal, and far longer segmented *Lactobacilli* chains (identified as *Leptothrix*), ranging from 40  $\mu\text{m}$  to 75  $\mu\text{m}$  in length (7).

Normal *Lactobacilli* length is between 5  $\mu\text{m}$  and 15  $\mu\text{m}$  and the total number of *Lactobacilli* observed in a microscope at 400x magnification is between 15 and 25 per image (Figure 2). In patients with VL, there are two to several times more *Lactobacilli* observed per image. Women experiencing VL also exhibit *Lactobacilli* which are up to eight times longer than normal with many presenting bizarre forms (5, 6, 8).



**Figure 2:** Vaginal Lactobacillosis: abundant *Lactobacilli* with bizarre forms

The etiology of VL is still under investigation but it has been linked to other conditions, including anti-fungal topical medications misuse, Diabetes Mellitus, and Vulvodynia. VL is diagnosed in approximately 15% of patients complaining about copious vaginal discharge (9).

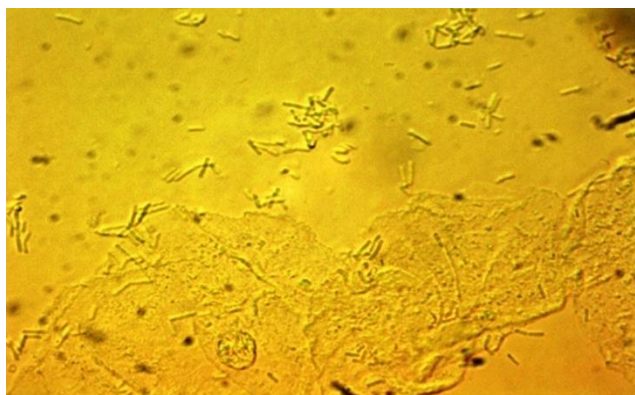
The treatment of VL consists of eliminating the abnormal *Lactobacilli* with oral amoxicillin-clavulanate,

using doxycycline as an alternative (6, 9). The replenishment of normal *Lactobacilli* then could be achieved by taking oral live *Lactobacilli* and acidifying the perineum with mild acidic solutions. *Lactobacilli* have shed some genes to acquired vaginotropism that assists them in vaginal colonization.

### Cytolytic Vaginosis

In 1991, Cibley *et al.* described patients presenting with a condition named “Cytolytic Vaginosis” who complained of a white cheesy vaginal discharge, pruritus, vulvar dysuria, dyspareunia, and a recurring increase in symptoms more noticeable in the luteal phase (10, 11).

Cibley’s diagnostic criteria included the presence of discharge, as well as exclusion of *Trichomonas*, *Gardnerella*, and *Candida* on the wet mount (10). Cibley also observed an increased number of *Lactobacilli*, a scarcity of white blood cells, evidence of cytolysis, and a pH between 3.5 and 4.5 (Figure 3). Cibley suggested a treatment using sodium bicarbonate douches (10). Douching is no longer recommended and current suggested treatments include topical metronidazole and/or topical steroid creams (10).



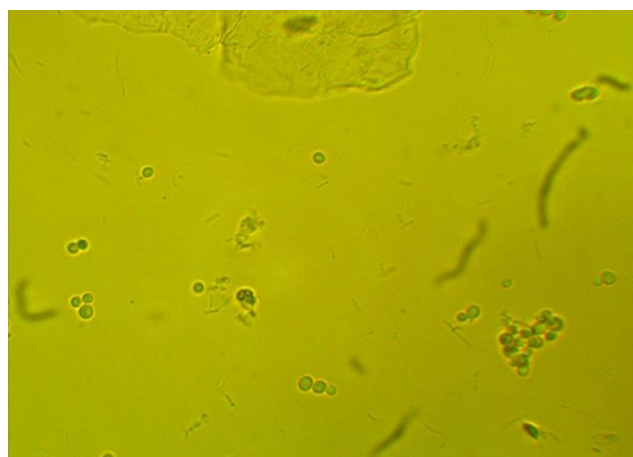
**Figure 3:** Cytolytic Vaginosis: increased normal *Lactobacilli* with abundant cytolysis

### Controversies

We can now understand that Lactobacillosis and Cytologic Vaginosis are often symptomatically confused by patients and inexperienced clinicians. Many women therefore incorrectly self-diagnose or are incorrectly diagnosed with fungal infection or colonization (12). As a result, many women try over-the-counter topical antifungal medications or are prescribed oral antifungals only to get partial or no relief. The microscopic wet mount examination with an 80% sensitivity provides the patient with a more targeted treatment until confirmation testing is

complete (13).

Evidently, we are in front of two different conditions. Abundant cytolysis is characteristic of Cytolytic Vaginosis, while the clear presence of *Leptothrix* is the “sine qua non” of Lactobacillosis. Also, should we refer to Cytolytic Vaginosis as Desquamative Vaginosis or as Cytolytic Vaginosis, considering that these conditions may coexist (Figure 4)?



**Figure 4:** Lactobacillosis and *Candida dubliniensis*

Knowing how to properly recognize the images of these two symptomatically similar conditions, at the wet mount microscopy with normal saline, will certainly assist in successful differentiation during the patient’s visit. This can provide the patient with an 80% diagnostic sensitivity and therefore an improved targeted treatment until confirmation testing is complete.

### Conclusion

The correct diagnosis of symptomatic patients with increased vaginal discharge is challenging. Differentiation may be established using patient history, physical examination, and proper laboratory testing. Correctly performed vaginal wet mount microscopy with normal saline can be achieved with an 80% diagnostic sensitivity in an office setting providing the patient with targeted treatment.

### Conflict of Interests

Authors have no conflict of interests.

### Acknowledgments

We are grateful to the Texas Tech University Health Sciences Center (TTUHSC) at the Permian Basin,

Texas, and Ailena Mulkey, Evangelina Santiago, and Jammie Holland from Clinical Research Institute, Texas for their excellent support and help.

## References

1. Kairys N, Garg M. Bacterial Vaginosis. 2021. In: StatPearls [Internet]. Treasure Island (FL): StatPearls Publishing; 2022.
2. Buchta V. Vaginal microbiome. *Ceska Gynekol* 2018; 83: 371-9.
3. Secor R. Vaginal microscopy: Refining the nurse practitioner's technique. *Clinical Excellence for Nurse Practitioners* 1997; 1: 29-34.
4. Colonna C, Steelman M. Amsel criteria. StatPearls [Internet] 2021.
5. Ventolini G. Progresses in vaginal microflora physiology and implications for bacterial vaginosis and candidiasis. *Womens Health (Lond)* 2016; 12: 283-91.
6. Horowitz BJ, Mardh PA, Nagy E, Rank EL. Vaginal lactobacillosis. *Am J Obstet Gynecol* 1994; 170: 857-61.
7. Kaufman RH. Benign diseases of the vulva and vagina. St Louis: Mosby; 1994: 168–248.
8. Feo LG, Dellellette BR. *Leptotrichia* (*Leptothrix*) *vaginalis*. *Am J Obstet Gynecol* 1952; 64: 382-6.
9. Ventolini G, Schrader C, Mitchell E. Vaginal lactobacillosis. *Journal of Clinical Gynecology and Obstetrics* 2014; 3: 81-4.
10. Cibley LJ, Cibley LJ. Cytolytic vaginosis. *Am J Obstet Gynecol* 1991; 165: 1245-9.
11. Hutti MH, Hoffman C. Cytolytic vaginosis: an overlooked cause of cyclic vaginal itching and burning. *J Am Acad Nurse Pract* 2000; 12: 55-7.
12. Sobel JD, Cook RL, Redondo-Lopez V. *Lactobacilli: a role in controlling the vaginal microflora. Vaginitis and Vaginosis* New York, Wiley-Liss. 1991: 47-53.
13. Foxman B, Muraglia R, Dietz JP, Sobel JD, Wagner J. Prevalence of recurrent vulvovaginal candidiasis in 5 European countries and the United States: results from an internet panel survey. *J Low Genit Tract Dis* 2013; 17: 340-5.

**Citation:** Ventolini G, Gandhi K, Manales NJ, Garza J, Sanchez A, Martinez B. **Challenging Vaginal Discharge, Lactobacillosis and Cytolytic Vaginitis.** *J Family Reprod Health* 2022; 16(2): 102-5.