

Molar Changes With a Normal Viable Fetus: A Case Report

Marjaneh Farazestanian; M.D., Asieh Maleki; M.D., Somayeh Bolandi; M.D., Zohreh Yousefi; M.D., Malihe Hasanzadeh; M.D., Laya Shirinzadeh; M.D., Sara Kamandi; M.D.

Department of Obstetrics and Gynecology, Faculty of Medicine, Mashhad University of Medical Sciences, Mashhad, Iran

Received March 2020; Revised and accepted September 2020

Abstract

Objective: The presence of a normal fetus with normal karyotype accompanied by molar changes in the placenta is a rare condition, which carries a significant risk to the mother and fetus. There is a controversy regarding the proper management of this condition. Here, we present the case of a singleton pregnancy that showed molar changes in the pathological study of the placenta, but ended up with a normal viable neonate.

Case Report: A 23-year-old primigravida woman, with a 3-year history of infertility, presented with vaginal bleeding and spotting. Her β -human chorionic gonadotropin (HCG) at 13th week was 36500 mIU/ml. Serial sonography assessments were suggestive for molar changes and a normal fetus with growth retardation but normal Doppler assessment. The patient underwent elective Cesarean section at 37 weeks gestation and a healthy female neonate with an Apgar score of 9-10, weighing 2270 g was born. Pathological assessment of the placenta confirmed the diagnosis of incomplete hydatidiform mole. After two months, the mother had no complications, her β -HCG level was untraceable, and the infant was in good condition.

Conclusion: Despite being a rare condition, partial moles can be accompanied by delivery of a normal fetus. The management of this condition still remains challenging and should be done under close monitoring with extreme caution.

Keywords: Incomplete Hydatidiform Mole; Normal Fetus; Fetal karyotype

Introduction

Hydatidiform mole is part of a group of genetically abnormal conceptions named gestational trophoblastic diseases. The condition is normally benign, with a variable potential risk of becoming malignant. According to the histopathology and macroscopic features of the placenta, moles are classified into complete and partial (1). Complete moles are paternal pathologies resulting from fertilization of either two sperms with a chromosome-free ovum or one sperm with a chromosome-free

ovum and subsequent mitosis of the sperm chromosome, yielding a diploid cell. In contrast, a partial mole is composed of coincident conception of two sperms with a normal ovum resulting in a triploid cell with a paternal origin (2). In macroscopic assessment, complete moles are composed of a totally hydropic and dilated placenta without any normal fetus. Partial mole is also composed of hydropic villi and abnormal fetal parts (3).

The coincidence of molar changes with a normal fetus is extremely rare, with a reported incidence rate of 0.005-0.01 % in all pregnancies (4). This condition poses several risks to the mother and the fetus. There is a controversy regarding whether it is better to terminate the pregnancy or follow the mother until a

Correspondence:

Dr. Sara Kamandi

Email: kamandis961@mums.ac.ir

normal delivery. Due to the life-threatening complications of this condition, including massive bleeding, hyperthyroidism, preeclampsia and trophoblastic diseases, termination of pregnancy is usually preferred (5). Here, we present the case of a singleton pregnancy that showed molar changes in pathological study of placenta, but ended up with a normal viable neonate.

Case report

A 23-year-old primigravida woman, referred to Gynecology department of Ghaem hospital, Mashhad, Iran, with vaginal bleeding and spotting. She was at 19 weeks gestation and had a three-year history of infertility prior to this spontaneous pregnancy.

On general examination, the patient was not pale and had stable vital signs. Speculum examination revealed spotting. Her primary hemoglobin level was 13.6 g/dl and her hematocrit was 39.8%. Her blood group was O and her Rh (D) was positive. The initial β -human chorionic gonadotropin (HCG) of the patient at 13th week was 36500 mIU/ml.

Primary ultrasound exam had revealed a viable fetus at 13 weeks gestation with normal amniotic fluid (AF), anterior placental attachment, and a nuchal translucency (NT) of 1.3 mm, as well as an evident molar change in the distal segment of placenta. Furthermore, a nearly extensive hematoma with a size of 66×22 millimeters was evident in the posterior part of the placenta. The first trimester screening had yielded normal results. Besides, amniocentesis had revealed a 46, XX karyotype with normal genotype.

The patient had undergone anomaly ultrasound scan at 18 weeks of gestation that showed normal findings. Anterior placenta had been evident without any hematoma and AF index (AFI) was 7.5 cm.

As soon as the patient referred to our department, she initially underwent chest-X-Ray (CXR) due to the presence of molar changes, which yielded normal results. Therefore, given the normal results of amniocentesis and CXR, the patient was counselled about the complications of continuing a pregnancy with molar changes. After all, since the patient decided to continue the pregnancy and accepted the potential risks, she underwent close observation and regular monitoring until her delivery.

Ultrasound scan at 21st weeks of pregnancy revealed a retardation in fetal growth as the fetus had an abdominal circumference (AC) of 6%, femur length (FL) of 6%, and head circumference (HC) of

4% and a weight of 360 grams. The patient underwent regular serial sonographies every 3-4 weeks, all of which indicated growth retardation along with normal Doppler ultrasound (Figure 1).

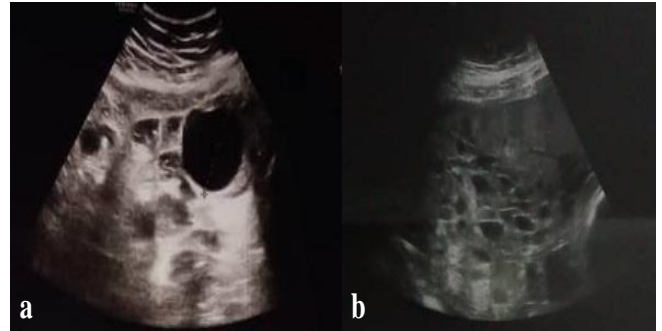


Figure 1: Ultrasound scans of the molar pregnancy at (a) 21st week and (b) 35th week of gestation

The spotting was continued until the 30th week of gestation. Ultrasound assessment at 35th week reported partial mole. The sonography estimated the gestational age to be around 32±2 weeks based on biparietal diameter (BPD), 30±3 weeks based on abdominal circumference (AC), 32±1 weeks based on femoral length (FL), and 32±6 weeks based on head circumference (HC). The reported weight was 1805±250 g, which was under fifth percentile. However, a color Doppler ultrasound showed no intrauterine growth restriction (IUGR).

At the age of 37 weeks according to her last menstrual period (LMP) and 36±4 weeks according to the 13th week ultrasound, the patient underwent elective Cesarean section. A healthy female neonate was born with an Apgar score of 9-10 and a birth weight of 2270 grams.

During her pregnancy, our patient was closely monitored for any complications, e.g. bleeding or hypotension. Fortunately, we detected no adverse events and the patient had her baby delivered with no complications.

The placenta was large and showed 40% of vesicular and hydropic changes. The pathologic assessment of placental specimen confirmed the diagnosis of incomplete hydatidiform mole (Figure 2). After a two-month follow-up, β -HCG became negative (undetectable), the patient had no signs or symptoms, and the infant was in good condition.

The placenta was large with around 40% of it being vesicular and hydropic, and the pathologic assessment of placental specimen confirmed the diagnosis of incomplete hydatidiform mole (Figure

2). After a two-month follow-up, the patient's β -HCG became negative, the patient had no signs or symptoms, and the infant was in good condition.

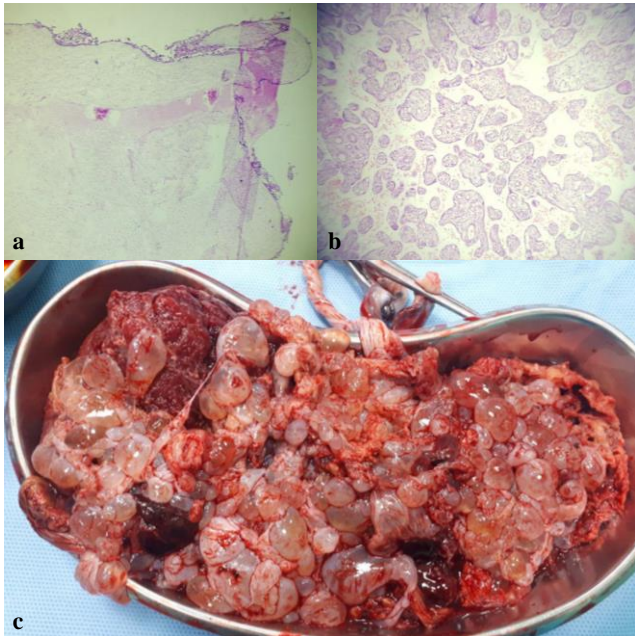


Figure 2: (a) Microscopic view of the placental specimen at 4x; (b) Microscopic view of the placental specimen at 100x; (c) Macroscopic view of the placenta

Discussion

Molar changes can accompany normal pregnancies via three different scenarios: a singleton pregnancy composed of a partial mole and a live fetus, a twin pregnancy composed of one molar and another normal placenta, and the combination of a partial mole and a twin in one sac and a normal twin in the other. Among the described conditions, the rarest is a diploid partial mole along with a co-existent fetus, as seen in our case (7). Herein, we presented the case of woman with partial mole that was recognized at 13 weeks gestation, who gave birth to a normal female neonate. This is a rare condition with a prevalence of 0.005 to 0.01% (4). Mitotic abnormalities in the early post-fertilization period and placental mosaicism can be a potential cause for this event (4).

Both complete and partial moles may bring fetal and maternal complications, causing a clinical dilemma regarding the proper management option. In case of life-threatening complications in such patients, termination of the pregnancy is the treatment of choice (5). However, in presence of a normal karyotype and absence of notable fetal/maternal complications, pregnancy can be continued (8). In our

study, the patient with a three-year history of infertility successfully delivered her child under close monitoring, in spite of her partial mole. She accepted the potential risks and was followed by ultrasound exams throughout her gestation. Our patient developed no major complication, except a negligible spotting, that was ceased at 30th week of gestation.

Deveer et al. (9) also reported a case of partial mole along with a normal fetus in a 35-year-old mother (para 4 gravida 5) at the 14th week of gestation. Their patient was asymptomatic except for a severe hyperemesis gravidarum and a treated hyperthyroidism in the course of pregnancy. They followed the patient with karyotype assessment and serial ultrasound scans, which revealed normal results. Finally, the pregnancy was terminated by Cesarean section at gestational age of 39 weeks and a normal neonate weighing 3100 g was born.

Rahamni et al. also reported a similar case that was diagnosed at the 11th week of gestation. The patient had an uneventful pregnancy until premature rupture of membranes occurred at the 26th week and the pregnancy was terminated by induction of delivery. The neonate was not alive, but the patient had no other complications (10).

Abukaftah (11) also reported a 40-year-old woman (gravida 6 para 4+1) presented at 12th week of pregnancy with abdominal pain and vaginal bleeding. The patient was admitted and managed for threatened abortion but the mother decided to continue her pregnancy. Sonography at the 25th week revealed a partial mole along with a normal fetus. After the cesarean section at 34th week, a normal male fetus and a partial mole was observed.

Another case reported by Tesemma et al. was an 18-year-old primigravida mother with a singleton term pregnancy coincident with a partial mole who presented with signs and symptoms of eclampsia including generalized tonic-clonic seizures and a blood pressure of 170/100 mmHg. The patient underwent emergency Cesarean section and gave birth to a female neonate weighting 1100 g. The neonate was admitted to neonatal intensive care unit (NICU) and deceased after 65 hours due to respiratory failure, possibly because of prematurity (4).

Guyen et al. evaluated 17 cases of partial hydatidiform mole associated with normal fetal karyotype. They concluded that despite the high rate of adverse perinatal outcomes, continuing the pregnancy with close follow-up in a tertiary center is

feasible if amniocentesis or fetal blood sampling reveals a normal karyotype (12).

Conclusion

According to the results of this and other mentioned studies, it can be stated that pregnancies affected by hydatidiform moles can also come to term. Thus, providing appropriate counselling to pregnant mother regarding the decision to continue pregnancy, and close monitoring of the fetus and its condition is substantial.

In spite of all possible risks, delivery of a normal neonate can be achieved in patients with partial mole and normal coexisting fetus. Nevertheless, the risk of complications such as premature delivery or trophoblastic cancers should not be overlooked. Serial sonographic assessments and close monitoring of the pregnancy should be considered.

Conflict of Interests

Authors have no conflict of interests.

Acknowledgments

None.

References

1. Lawler SD, Fisher RA, Pickthall VJ, Povey S, Evans MW. Genetic studies on hydatidiform moles. I. The origin of partial moles. *Cancer Genet Cytogenet* 1982; 5: 309-20.
2. Eagles N, Sebire NJ, Short D, Savage PM, Seckl MJ, Fisher RA. Risk of recurrent molar pregnancies following complete and partial hydatidiform moles. *Hum Reprod* 2015; 30: 2055-63.
3. Lurain JR. Hydatidiform mole: Recognition and management. *Contemporary OB/GYN* 2019; 64: 12-7.
4. Tesemma MG. Singleton Partial Molar Pregnancy Delivered in Third Trimester: A Case Report. *Journal of Patient Care* 2019; 5: 1.
5. Sebire NJ, Foskett M, Paradinas FJ, Fisher RA, Francis RJ, Short D, et al. Outcome of twin pregnancies with complete hydatidiform mole and healthy co-twin. *Lancet* 2002; 359: 2165-6.
6. Vejerslev LO, Sunde L, Hansen BF, Larsen JK, Christensen IJ, Larsen G. Hydatidiform mole and fetus with normal karyotype: support of a separate entity. *Obstet Gynecol* 1991; 77: 868-74.
7. Giorgione V, Cavoretto P, Cormio G, Valsecchi L, Vimercati A, De Gennaro A, et al. Prenatal Diagnosis of Twin Pregnancies with Complete Hydatidiform Mole and Coexistent Normal Fetus: A Series of 13 Cases. *Gynecologic and obstetric investigation* 2017; 82: 404-9.
8. Bruchim I, Kidron D, Amiel A, Altaras M, Fejgin M. Complete hydatidiform mole and a coexistent viable fetus: report of two cases and review of the literature. *Gynecologic oncology* 2000; 77: 197-202.
9. Deveer R, Ustun YE, Eryilmaz OG, Akbaba E, Deveer M. Molar Pregnancy with a Co-Existing Viable Fetus. *J Clin Anal Med* 2015; 6: 88-90.
10. Rahamni M, Parviz S. A case report of partial molar pregnancy associated with a normal appearing dizygotic fetus. *Asian Pacific J Reprod* 2016; 5: 171-3.
11. Abukaftah A, Jabeen S, Moawad A, Almetrek M. A Case Report of Partial Molar Pregnancy Associated with A Normal Dizygotic Twin. *The Egyptian Journal of Hospital Medicine*. 2018; 70: 1221-3.
12. Guvendag Guven ES, Ozturk N, Deveci S, Hizli D, Kandemir O, Dilbaz S. Partial molar pregnancy and coexisting fetus with diploid karyotype. *J Matern Fetal Neonatal Med* 2007; 20: 175-81.

Citation: Farazestanian M, Maleki A, Bolandi S, Yousefi Z, Hasanzadeh M, Shirinzadeh L, et al. **Molar Changes With a Normal Viable Fetus: A Case Report.** *J Fam Reprod Health* 2020; 14(3): 205-8.