



Maxillary odontogenic myxoma: A case report

Mohsen Barzegar¹, Hamidreza Ajami², Adele Pouyafard³, Gooya Kabir^{4*}

1. Oral and Maxillofacial Surgeon, School of Dentistry, Shahid Sadoughi University of Medical Sciences, Yazd, Iran.

2. Oral and Maxillofacial Surgeon, Dental School, Ardabil University of Medical Sciences, Ardabil, Iran.

3. Oral and Maxillofacial Medicine, School of Dentistry, Shahid Sadoughi University of Medical Sciences, Yazd, Iran.

4. Oral and Maxillofacial Surgery, Shahid Sadoughi University of Medical Sciences, Yazd, Iran.

ARTICLE INFO

Article Type: Case Report

Received: 2 Mar. 2021

Revised: 2 Apr. 2020

Accepted: 25 Jun. 2021

*Corresponding author:

Gooya Kabir

Oral and Maxillofacial Surgery, Shahid Sadoughi
University of Medical Sciences, Yazd, Iran.

Tel: +98-913-3577013

Fax: +98-21-84902473

Email: Gooyakabir@Yahoo.com

ABSTRACT

Odontogenic myxoma is a benign mesenchymal tumor that appears to be associated with odontogenic ectomesenchyme of the growing teeth. This tumor, which often occurs in the second and third decades of life, is extremely rare and often asymptomatic in children. However, no theoretical consensus exists in the literature over the diagnosis and treatment of this disease. In this study, we investigated the diagnostic and therapeutic methods of a rare case of odontogenic myxoma in a 13-year-old child.

Keywords: Odontogenic myxoma; Maxilla; Children.

Introduction

Odontogenic myxoma is a benign mesenchymal tumor that originates from the papilla, follicle, or periodontal ligament [1,2]. This type of benign tumor is characterized by scattered stellate and twin cells in a myxoid extracellular matrix (which may contain odontogenic epithelium). Histologically, this type of tu-

mor appears to be associated with odontogenic ectomesenchyme of the growing teeth [3]. This neoplasm, which behaves aggressively and invasively, was reported as the third most common odontogenic tumor after odontoma and ameloblastoma by the World Health Organization in 2017 [4].

This invasive tumor accounts for 1 to 17.7% of the odontogenic tumors, grows slowly, and usually occurs among young people in the second and third decades of life [5,6]. Numerous studies that compared the incidence of this tumor between genders reported conflicting results; generally, this tumor seems to be more common among females than [7,8]. This disease is even less common in children compared to adults but tends to have the same pathological and clinical features in all individuals [9]. However, most of these patients are asymptomatic and the disease is only diagnosed through using the existing radiological findings. For example, radiographs usually show a mandibular or maxillary tumor with unilateral trabeculae, which is sometimes associated with tooth displacement and its tomography shows a radiolucent tumor using trabeculae [9].

With all these interpretations, no evidence-based theoretical consensus has been made on the treatment of odontogenic myxoma. A wide range of surgical treatments has been proposed to deal with this tumor, ranging from tumor oncology to invasive resection such as mandibulectomy and maxillectomy. In this case report, we examined a rare case of odontogenic myxoma in a 13-year-old boy and discussed the diagnostic and therapeutic strategies.

Reporting the Case

A 13-year-old boy was referred to the maxillofacial ward in Yazd Shahid Rahnemoun Hospital following a lesion in his right maxilla. The patient mentioned the history of a slow-growing bulge from 2 years ago as well as a history of trauma (falling on the ground at school) 3 months before. As he mentioned, the mass size had increased since a month before he decided to seek treatment. The patient's face was asymmetric (Figure 1) and he did not complain of visual impairment. Physical examination showed a mass of an approximate size of 5 x 5cm in the right cheek that was accompanied by mild tenderness to touch. The consistency of the mass was firm and the skin examination was normal with no erythema. Moreover, no evidence of lymphadenopathy or trismus was observed. The intraoral examination also showed a firm painless protrusion in the buccal cortex extending from the right external incisor to the second molar. The patient's 7 maxillary tooth was loose and decreased vestibular depth with negative aspiration was also reported (Figure 2). Furthermore, the right nasal patency was reduced. The patient's body temperature was normal with no symptoms of fever and infection.

Occlusal radiographs showed a large multinucleated radiolucent lesion with a well-defined sclerotic margin from the right lateral margin of the incisor to the right second molar distal with a 'spider pattern' and a 'tennis racket pattern'. These were in favor of early detection of odontogenic myxoma (Figure 3). In the CT scan, the coronal and axial views showed a lytic lesion with expansion and thinness of the overlying buccal cortex with radiopaque foci throughout the lesion, which caused involvement of the right maxillary antrum (Figure 4).

According to the paraclinical findings and the uncertainty in diagnosis using these findings, the patient underwent a biopsy and odontogenic myxoma was reported. Later, due to the patient's young age (the high importance of function and beauty), conservative treatment was selected with inoculation and curettage. To this end, the patient underwent surgery under general anesthesia and the lesion was enucleated (Figure 5). Macroscopically, the surgical specimen consisted of a part of the maxilla and the right antrum with a gelatinous mass along with a mucous membrane (Figure 6). The pathology report and microscopic examinations showed a tumor consisting of loose spindle cells with helical nuclei in a stroma variable in terms of myxoid and fiber (Figure 7). After the surgery, the recovery rate was significant and the patient was regularly followed up for recurrence of the symptoms and recovery. Furthermore, a treatment program is underway for dental rehabilitation.

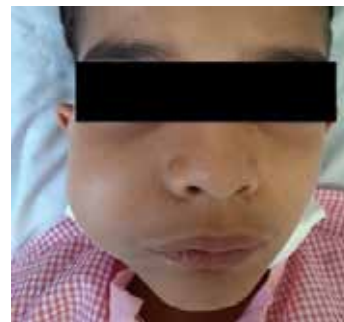

Figure 1. Mild tenderness lesion in the right maxilla.

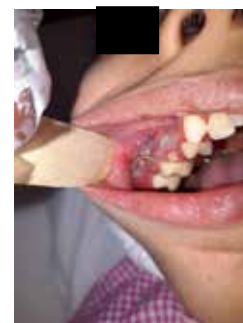

Figure 2. Bone lesion in the buccal cortex extending from the right external incisor to the second molar.

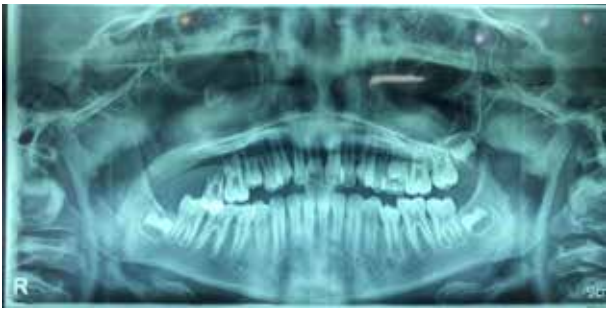


Figure 3. Occlusal radiography with a 'spider pattern'.

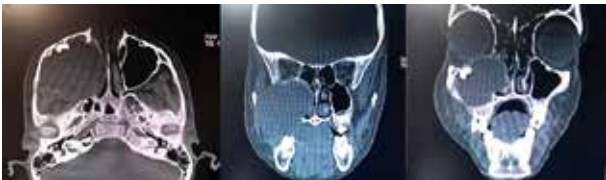

Figure 4. CT-Scan with axial and coronal views showing the lytic lesion with expansion and thinness of the overlying buccal cortex with radiopaque foci throughout the lesion.

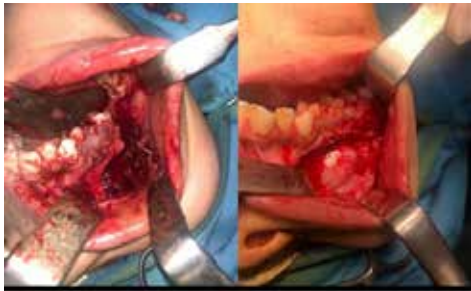

Figure 5. Lesion and its location during the inoculation and curettage surgery.

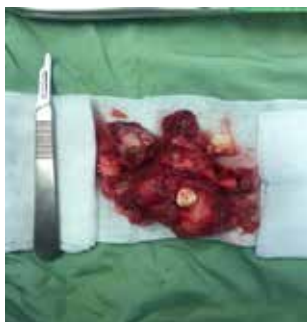

Figure 6. Samples taken from the patient's maxilla with a gelatinous appearance.

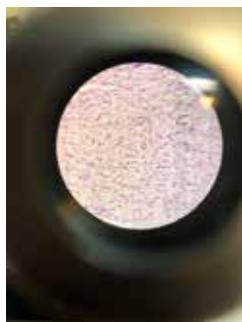


Figure 7. The microscopic lesion consisting of loose spindle cells with helical nuclei in a variable stroma

Discussion

Odontogenic myxoma is an uncommon benign odontogenic tumor that results from embryonic connective tissue associated with tooth formation [10]. According to the World Health Organization, it is a benign but intraosseous neoplasm classified as odontogenic mesenchyme or ectomesenchyme with or without odontogenic epithelium [9]. As a myxoma, the tumor is mainly composed of spindle-shaped cells and scattered collagen fibers distributed within a loose mucous membrane [11]. The odontogenic myxoma is believed to be caused by dental papillae or follicular mesenchyme. Evidence related to the odontogenic origin of this tumor suggests its occurrence in tooth-bearing jaws, and its occasional association with the missing or unusable teeth, and the presence of odontogenic epithelium [12]. Macroscopically, the lesion was a soft yellowish-gray mass with an unencapsulated appearance and a viscous and mucous incision surface. Histologically, the tumor was composed of triangular stellate cells with a mucosal intercellular matrix and a slightly basophilic fine-grained cytoplasm with a distinct nucleus.

This disease was reported in patients within the age range of 2 to 50 years. However, it usually affects adolescents and young adults in their second and third decades of life. In other words, these tumors rarely affect people under 10 or over 50 years of age [13,14]. Due to the slow growth of this tumor, patients usually do not have many symptoms; so, CT and MRI examinations are necessary for surgical planning and differential diagnosis with other lesions that can prevent the unnecessary biopsy [15]. In this case, the patient reported a 2-year history of a growing asymptomatic mass that confirms the usual features of myxoma. However, the patient's diagnosis was finalized using a biopsy and he underwent surgery.

In addition, extensive removal of the mass with a margin of 10 to 15mm is recommended due to the tumor's high recurrence rate. However, no specific guideline is available regarding the surgical procedure in these patients and some researchers point out that inoculation and curettage can be more effective and less invasive methods. Therefore, the same procedure was applied to this patient too and he underwent inoculation [9]. Boffano et al. also preferred a conservative surgery using inoculation and curettage for lesions less than 3cm. They recommended the segmental resection with immediate reconstruction for larger lesions, which is not compatible with our selected method for

treating this case [16]. Kleiber et al. described extensive resection in two surgeries with chemotherapy in a 3-year-old child suffering from mandible and maxilla myxoma. The findings of the four-year follow-up, in this case, showed no recurrence in the patient [17]. M Dalbo Contrera Toro et al. (2016) investigated a two-and-a-half-year-old child with odontogenic myxoma. As they noted, the protective resection in these patients is a better choice among children due to its fewer complications. This method is in the same line with the procedure we applied in this study [9]. Fang et al. also examined 310 cases of odontogenic tumors or tumor-like lesions. They reported four patients with myxoma who underwent invasive surgery with no recurrence [18]. The recurrence rate of myxoma was reported to vary from 5 to 10% in various studies, but no comprehensive information exists in this regard [19].

Conclusion

Odontogenic myxoma is a very rare benign tumor in children, which has been investigated in few studies. In dealing with this lesion, we should always consider other diagnoses. That is to say, we should treat this disease using surgical methods only after rejecting other causes of malignancy using paraclinical tools and biopsy. Although various studies do not provide a comprehensive view over the treatment of this mass, the majority of related studies confirm the application of less invasive methods and protective surgeries using inoculation and curettage. The findings of these studies show appropriate results with regard to the beauty issues and recurrence of the disease. Currently, less invasive methods are preferred in these patients. Although a low recurrence rate was reported for this disease in the literature, long-term follow-up of these patients is essential after treatment.

Conflict of Interest

There is no conflict of interest to declare.

References

- [1] Sivakumar G, Kavitha B, Saraswathi TR, Sivapathasundharam B. Odontogenic myxoma of maxilla. *Indian J Dent Res* 2008; 19(1):62-5.
- [2] Manne RK, Kumar VS, Venkata Sarath P, Anumula L, Mundlapudi S, Tanikonda R. Odontogenic myxoma of the mandible. *Case Rep Dent* 2012; 2012:214704.
- [3] Chrcanovic BR, Gomez RS. Odontogenic myxoma: An updated analysis of 1,692 cases reported in the literature. *Oral Dis* 2019; 25(3):676-683.
- [4] El-Naggar AK, Chan JKC, R. GJ, Takata T, Slootweg PJ. WHO/IARC Classification of Tumours; 2017.
- [5] Kumar S, Mehra P, Ahmad Z, Singh YB. Disfiguring Giant Odontogenic Myxoma of Mandible: A Case Report with Brief Review of Literature. *Indian J Otolaryngol Head Neck Surg* 2019; 71(Suppl 1):55-58.
- [6] Mosqueda-Taylor A, Ledesma-Montes C, Caballero-Sandoval S, Portilla-Robertson J, Ruíz-Godoy Rivera LM, Meneses-García A. Odontogenic tumors in Mexico: a collaborative retrospective study of 349 cases. *Oral Surg Oral Med Oral Pathol Oral Radiol Endod* 1997; 84(6):672-5.
- [7] Kawase-Koga Y, Saijo H, Hoshi K, Takato T, Mori Y. Surgical management of odontogenic myxoma: a case report and review of the literature. *BMC Res Notes* 2014; 7:214.
- [8] Raubenheimer EJ, Noffke CE. Peripheral odontogenic myxoma: a review of the literature and report of two cases. *J Maxillofac Oral Surg* 2012; 11(1):101-4.
- [9] Dalbo Contrera Toro M, Siqueira Barreto I, Amstalden EM, Takahiro Chone C, Nizam Pfeilsticker L. Odontogenic Myxoma in Children: A Case Report and Literature Review. *Case Rep Oncol Med* 2016; 2016:9017421.
- [10] Philip SJ, Eversole LR, Wysocki GP. Contemporary oral and maxillofacial pathology. 2nd ed. St. Louis: Mosby; 2004.
- [11] Cawson RA, Odell EW. Cawson's Essentials of Oral Pathology and Oral Medicine. London: Churchill Livingstone; 2008.
- [12] Sarode TP, Malik NA. Odontogenic myxoma in a child: diagnostic and treatment dilemmas. *J Indian Soc Pedod Prev Dent* 2002; 20(2):68-72.
- [13] Dean JA. McDonald and Avery's Dentistry for the Child and Adolescent. 10th ed. St. Louis: Elsevier Health Sciences; 2015.
- [14] Zimmerman DC, Dahlin DC. Myxomatous tumors of the jaws. *Oral Surg Oral Med Oral Pathol* 1958; 11(10):1069-80.
- [15] Zainine R, Mizouni H, El Korbi A, Beltaief N, Sahtout S, Besbes G. Maxillary bone myxoma.

Eur Ann Otorhinolaryngol Head Neck Dis 2014; 131(4):257-9.

- [16] Boffano P, Gallesio C, Barreca A, Bianchi FA, Garzino-Demo P, Rocca F. Surgical treatment of odontogenic myxoma. J Craniofac Surg 2011; 22(3):982-7.
- [17] Kleiber GM, Skapek SX, Lingen M, Reid RR. Odontogenic myxoma of the face: mimicry of cherubism. J Oral Maxillofac Surg 2014; 72(11):2186-91.
- [18] Fang QG, Shi S, Sun CF. Odontogenic lesions in pediatric patients. J Craniofac Surg 2014; 25(3):e248-51.
- [19] Kansy K, Juergens P, Krol Z, Paulussen M, Baumhoer D, Bruder E, et al. Odontogenic myxoma: diagnostic and therapeutic challenges in paediatric and adult patients--a case series and review of the literature. J Craniomaxillofac Surg 2012; 40(3):271-6.

Please cite this paper as:

Barzegar M, Ajami H, Pouyafard A, Kabir G; Maxillary odontogenic myxoma: A case report. J Craniomax Res 2021; 8(3): 159-163