



Inferior alveolar nerve repositioning with simultaneous iliac bone autogenous graft for treatment of atrophic posterior mandibular ridge

Arash Khojasteh ¹, Shahabaldin Azizi ^{2*}

1. Department of Oral and Maxillofacial Surgery, Head of Dental Research Center, Research Institute of Dental Sciences, Shahid Beheshti University of Medical Sciences, Tehran, Iran.

2. Department of Oral and Maxillofacial Surgery, School of Dentistry, Iran University of Medical Sciences, Tehran, Iran.

ARTICLE INFO

Article Type:
Technical Note

Received: 23 May, 2020

Revised: 2 Aug, 2020

Accepted: 25 Sep, 2020

*Corresponding author:

Shahabaldin Azizi

Department of Oral and Maxillofacial Surgery,
School of Dentistry, Iran University of Medical Sciences, Tehran, Iran.

Tel: +98-912-0350641

Fax: +98-21-84902473

Email: Shahabazizi44@Gmail.com

ABSTRACT

Patients with tooth loss in the posterior mandible, requiring dental implantation, may also require other simultaneous surgical procedures due to severe atrophy, such as nerve lateralization. However, it is difficult to achieve the appropriate width and height in this area in patients with atrophic ridges. In the present case, we performed inferior alveolar nerve (IAN) repositioning and iliac bone grafting simultaneously to achieve satisfactory width and height in an edentulous adult patient with insufficient bone height and width in the posterior mandible. The follow-up did not indicate any nerve damage, and a significant increase was observed in the bone height, which facilitated successful implantation. This study showed the feasibility of IAN repositioning with simultaneous iliac bone autogenous grafting for the treatment of atrophic posterior mandibular ridges. However, further studies are required to confirm the safety and efficacy of this combinational method.

Keywords: Alveolar bone loss; Mandibular nerve; Nerve repositioning; Iliac bone; Autografts.

Introduction

Tooth loss may occur due to different reasons, including infection, and can have negative effects on the patient's oral and general quality of life, as well as orofacial structures [1]. Resorption of the alveolar ridge is one of the important changes during the first 12 months after tooth extraction, which complicates further treatment. The reduction of the ridge dimensions is a natural consequence of the lack of strain stimulus needed to maintain the bone mass [2]. Implant placement, as the

treatment of choice for edentulous patients, requires a sufficient volume of residual bone for its proper retention and stability. Insufficient residual bone may occur due to jaw atrophy, osteomyelitis, cancer ablation surgery, and trauma. These conditions may be also associated with the proximity of anatomical structures, such as the inferior alveolar nerve, maxillary sinus floor, or nasal floor, all of which complicate the treatment [3,4].

Cawood and Howell proposed a classification to differentiate atrophies of the jawbones, based on an analysis of three-dimensional alveolar ridges. According to their classification, classes V and VI are considered jaws with severe atrophy [5]. Although short dental implant (SDI) may be used for the rehabilitation of atrophic alveolar crests, its application may not be possible due to severe bone defects. In such cases, several other techniques have been used to treat bone deficiency, including guided bone regeneration, autogenous bone grafting (ABG), alveolar distraction osteogenesis, and vascularized free flap bone reconstruction [6,7].

Posterior jaws do not often have a sufficient bone height (≥ 10 - 12 mm) for dental implant placement and present the dentist with the dilemma of whether to augment the bone or to use short implants (≤ 8 mm) [8]. The loss of an ideal bone superior to the inferior alveolar nerve (IAN) at the edentulous site, resulting in the short vertical distance of IAN, makes implant placement complicated, especially in the posterior mandible due to the possibility of damage to IAN during implant placement [9]. In these cases, several techniques have been used for vertical augmentation of the posterior mandibles, such as vertical guided bone regeneration (GBR) procedures, alveolar distraction osteogenesis, onlay bone grafting, and interpositional bone grafting [10].

In edentulous patients and those with Cawood and Howell classes V or VI, additional techniques are required to enable the insertion of dental implants without nerve damage. Repositioning of IAN by nerve lateralization and transposition has been suggested for this purpose. Other techniques have also been suggested to preserve the IAN integrity, including the use of bone manipulation techniques, including inlay and onlay grafting, GBR, bone expansion, bone splitting osteotomy, different fixation devices (e.g., bone screws, pins, titanium mesh, augmentation materials, and barrier membranes), and more detailed imaging analysis to allow for positioning of implants alongside rather than into the nerve canal during the procedure [11].

Alling performed the first case of IAN repositioning in 1977. In 1987, Jenson and Nock performed an IAN transposition (IANT) for the placement of dental implants in the posterior mandibular regions [12,13]. The major indication for this technique is to prevent IAN injury during implant placement in atrophic posterior mandibles when short implants are not viable options (e.g., in severely atrophic mandibles when the residual bone above the mandibular canal [MC] ranges between 0.5 and 1.5mm) [14]. During this procedure, the

buccal cortex surrounding the MC is removed, osteotomy of the mental foramen (partially or completely) is performed, and IAN is incorporated into the buccal flap [14]. These methods have several disadvantages, including the non-recovery of the alveolar ridge anatomy, weakening of the mandible resulting in mandibular fracture, risk of osteomyelitis, and implant failure [14-16].

Moreover, the risk of neurosensory disturbances and temporary or permanent dysfunction of the nerves is still an important concern, especially in IANT [14]. Augmentation techniques include the application of autogenous or engineered bone grafts or tissue-guided bone regeneration (GBR). GBR is more applicable for relatively small defects and dehiscence [17]. Autografts are the gold standard for grafting techniques that can be obtained intraorally from edentulous areas, such as maxillary tuberosity, mandibular symphysis, and mandibular ramus or extraorally from the iliac crest, rib, tibia, and calvarium [18]. The iliac bone is suggested as an excellent substrate for the reconstruction of mandibular atrophy due to its cancellous nature, substantial height, and thickness [19].

If neither the bone height nor its width is sufficient, combinations of two surgical techniques, such as iliac bone grafting and IAN lateralization (IANL), can be used to increase the success rate of implants by providing sufficient bone for implant placement [4,20,21]. Use of these procedures simultaneously in one surgical procedure can reduce the cost, treatment time, and risk of nerve damage and provide a better bone height for the implant. Considering the advantages of IANL and iliac bone grafting [14], we simultaneously performed these two methods. Here, we report a case of edentulous patient, who successfully underwent lateral and vertical autogenous grafting of the iliac bone with simultaneous IANL for the treatment of an atrophic posterior mandibular ridge, resulting from long-term tooth loss.

Case Presentation

A 38-year-old fully edentulous female patient was referred to the Department of Oral and Maxillofacial Surgery of Shahid Beheshti University of Medical Sciences, Tehran, Iran. She had lost all other teeth when she was 15 years old due to infection and had been using complete dentures for the past 20 years. Clinical examination revealed maxillary and mandibular ridge atrophy, overclosure of the jaws, deep nasolabial fissure, narrowing of the lips, and intraoral vestibule depth reduction. The radiographic imaging of the lower jaw showed the mandible to be atrophic (Cawood class V)

and that the IAN was superficial (Figure 1).

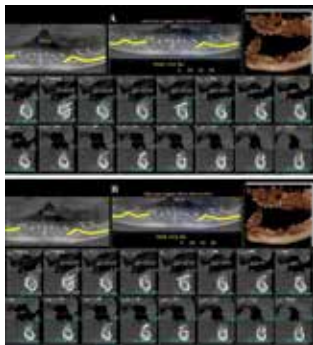


Figure 1. Cone beam computed tomography (CBCT) image of the mandible after six months (left & right).

The mental nerve on the right side had a height of 1.2mm and a width of 3mm, while on the left side, it showed a height of 1.8mm and a width of 1.8mm. The patient's serum hemoglobin level was 14g/dL, whereas other serum parameters were within the normal range. Written informed consent regarding the possibility of paresthesia after surgery was obtained from the patients.

Procedures

The surgery was performed by an experienced surgeon (A.K.). The iliac bone harvesting and ridge reconstruction were performed continuously under general anesthesia. The iliac bone blocks (monocortical blocks, 4×5cm) were harvested by the medial approach. After insertion of the Hemovac drain, it was sutured in three layers with Vicryl 3/0 and Nylon 3/0. Next, crestal incision of the maxilla and bilateral sinus lift were performed. Lateral augmentation of the maxilla was performed with continuous suturing (4-0 Vicryl, Ethicon Inc., Somerville, NJ, USA). Afterward, the crestal incision of the mandible was performed, and following dissection, the four branches of the mental nerve were dissected on both sides. A diamond bur was used to remove the bone above the IAN canal. The nerve was freed and moved away from the canal using a burnisher and secured to the buccal mucosa, using a membrane (Jason Membrane; Botiss Biomaterials GmbH, Berlin, Germany) that was sutured in place (4-0 Vicryl, Ethicon Inc., Somerville, NJ, USA). The cortical surface of the recipient bone was perforated to provide a bleeding bone surface. Any sharp edges on the harvested bone blocks were trimmed and carefully adapted to the recipient site. The bone blocks were then secured using fixation microscrews (7mm, Jeil, Seoul, South Korea). The gaps between the graft blocks and the recipient sites were then filled with 1cc of xenograft bone powder (Cerabone, Botiss Dental GmbH, Germany). Next,

20×30 membranes (Jason Membranes) were placed on the bones on each side and sutured (4-0 Vicryl, Ethicon Inc., Somerville, NJ, USA) (Figure 2).

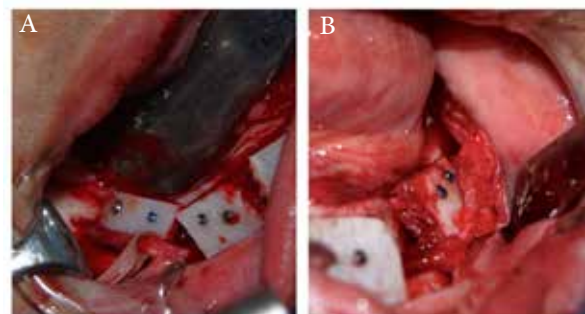


Figure 2. The image of the bone grafts inserted at each side of the mandible: A) right side and B) left side.

Finally, wound closure was achieved by suturing (4-0 Vicryl, Ethicon Inc., Somerville, NJ, USA). The drain was extracted on the second day after the operation. During the patient's hospitalization, she received Keflin and Gentamicin antibiotic therapy and was discharged on the fourth day after surgery. After six months, her oral mucosa was intact, and no neurosensory disturbance was observed. The cone beam computed tomography (CBCT) imaging in the follow-up showed significant improvements and increased width and height of the mandibular bone (Figure 1A and 1B), compared to the preoperative imaging results.

Discussion

Autogenous bone grafting from the iliac bone was successfully performed in our patient, simultaneously with IANL. This method was used as an appropriate bone manipulation technique to compensate for the atrophied mandibular ridge. We selected this combinational technique because the patient had a very narrow bone ridge due to 23 years of edentulism. The follow-up imaging at six months showed the significant improvement of the posterior mandibular bone (width of 5.82mm and height of 13mm on the left side; width of 5.28mm and height of 12.82mm on the right side). Nerve lateralization was performed to reduce the risk of IAN damage, as we observed the shortened vertical distance of the nerve. However, due to the narrow bone ridge, we decided to combine this method with another method to increase the bone volume and improve the success rate of implant. IANL is an important procedure in dental implants with mandibular ridge regeneration, because the decreased mandibular bone height, resulting in the short vertical distance of IAN, increases the risk of nerve damage during dental implantation [9]. This procedure can cause neural distur-

bances immediately after the procedure, with an incidence rate as high as 95.9% [16]. IANL has some other disadvantages if performed alone, as it does not recover the ridge anatomy, it temporarily weakens the mandible due to the removal of cortical bone, and increases the risk of osteomyelitis and implant failure [1]. In this regard, Felice et al. [22], in a study on inlay versus onlay iliac bone grafting of atrophic posterior mandibles, concluded that bone resorption and outcome predictability are higher in inlay bone grafts and that the onlay bone grafts require oversized bone blocks due to higher resorption. This technique can yield a vertical bone gain of 4-8mm if used in the posterior mandible [23]. Inlay bone grafting requires at least four to six bones above the IAN canal to avoid nerve injury and mandibular bone fracture. The required bone height was not available in our case, and therefore, onlay bone grafting was performed [23,24].

Use of iliac onlay bone grafts alone, without nerve lateralization, can provide larger bone blocks to provide the bone height required above IAN. Harvesting larger iliac bone blocks may increase the donor site morbidities, including pain, gait disturbances, scarring, and neurosensory disturbances. Moreover, use of larger blocks increases the vascularization problem, which can lead to higher resorption [25]. Bone grafts have been used in several studies for vertical bone gain and augmentation surgery [4,19-21], and iliac bone grafting is considered the "gold standard" autogenous bone harvesting method in patients with mandibular bone atrophy [26].

In a study by Nguyen et al. (2019), several intra- and extra-oral bone sources were used as the graft sources. It was shown that the iliac bone could provide sufficient bone volume, especially in patients with severe bone atrophy, resulting in 100% success rate of dental implants, inserted 3-5 months after bone grafts [4]. However, they did not perform nerve repositioning, whereas we performed both of these techniques simultaneously. In 2010, Peloet et al. followed-up the surgical data of 19 patients for four years and showed that bilateral two-step osteotomy with iliac bone autogenous grafting is a reliable surgical method to recreate the anatomical morphology of the mandible for the placement of osseointegrated dental implants; persistent neurosensory disturbances were only reported in three cases [20]. These results showed the low complication rate of two-stage bone grafting and implant technique and suggested it as a safe and effective method for increasing the success rate of dental implants in patients with mandibular ridge atrophy.

The grafted bone (from the iliac crest or other sites) undergoes inflammation and healing, becomes integrated in the recipient site, and becomes vascularized and thus osseointegrated [27]. Most studies have used either IAN repositioning [14,16] or bone grafting [4,19-21] before or simultaneously with dental implant. In a study by Khojasteh et al., the overall survival rate of dental implants in patients receiving IAN repositioning or bone grafting was similar to those with unaltered bones, while IAN repositioning resulted in longer and wider implants in the posterior mandible [28]. In the meantime, the risk of nerve damage was higher in IAN than cortical autogenous tenting technique [28]. Other studies have also shown that each of these techniques is associated with specific disadvantages and complications [14,16]. In our case, the long period of tooth loss (23 years edentulous) resulted in significant maxillary and mandibular ridge atrophies, as well as changes in the facial structures.

In conclusion, in the present case, IANL with simultaneous iliac bone grafting in the posterior mandible was successfully performed for a patient with 23 years of tooth loss, who showed significant posterior mandibular ridge atrophy. This technique could increase the success rate of implant and reduce postoperative complications. Further studies are required to confirm the safety and efficacy of this combinational technique in a large sample size.

Conflict of Interest

There is no conflict of interest to declare.

References

- [1] Bortoluzzi MC, Traebert J, Lasta R, Da Rosa TN, Capella DL, Presta AA. Tooth loss, chewing ability and quality of life. *Contemporary clinical dentistry*. 2012; 3(4):393.
- [2] Hansson S, Halldin A. Alveolar ridge resorption after tooth extraction: A consequence of a fundamental principle of bone physiology. *J Dent Biomech*. 2012; 3:1758736012456543.
- [3] Moraschini V, Poubel LA, Ferreira VF, Barboza Edos S. Evaluation of survival and success rates of dental implants reported in longitudinal studies with a follow-up period of at least 10 years: a systematic review. *Int J Oral Maxillofac Surg*. 2015; 44(3):377-88.
- [4] Nguyen TTH, Eo MY, Kuk TS, Myoung H, Kim SM. Rehabilitation of atrophic jaw using iliac on-

- lay bone graft combined with dental implants. *International journal of implant dentistry*. 2019; 5(1):11.
- [5] Cawood JI, Howell RA. A classification of the edentulous jaws. *Int J Oral Maxillofac Surg*. 1988; 17(4):232-6.
- [6] Al-Hashedi AA, Taiyeb Ali TB, Yunus N. Short dental implants: an emerging concept in implant treatment. *Quintessence Int*. 2014; 45(6):499-514.
- [7] Chiapasco M, Zaniboni M, Boisco M. Augmentation procedures for the rehabilitation of deficient edentulous ridges with oral implants. *Clin Oral Implants Res*. 2006; 17 Suppl 2:136-59.
- [8] Renouard F, Nisand D. Impact of implant length and diameter on survival rates. *Clin Oral Implants Res*. 2006; 17 Suppl 2:35-51.
- [9] Juodzbalys G, Wang H-L, Sabalys G. Injury of the inferior alveolar nerve during implant placement: a literature review. *Journal of oral & maxillofacial research*. 2011; 2(1).
- [10] Felice P, Checchi V, Pistilli R, Scarano A, Pellegrino G, Esposito M. Bone augmentation versus 5-mm dental implants in posterior atrophic jaws. Four-month post-loading results from a randomised controlled clinical trial. *Eur J Oral Implantol*. 2009; 2(4):267-81.
- [11] Mittal Y, Jindal G, Garg S. Bone manipulation procedures in dental implants. *Indian journal of dentistry*. 2016; 7(2):86.
- [12] Alling CC. Lateral repositioning of inferior alveolar neurovascular bundle. *J Oral Surg*. 1977; 35(5):419.
- [13] Jensen O, Nock D. Inferior alveolar nerve repositioning in conjunction with placement of osseointegrated implants: a case report. *Oral Surg Oral Med Oral Pathol*. 1987; 63(3):263-8.
- [14] Abayev B, Juodzbalys G. Inferior alveolar nerve lateralization and transposition for dental implant placement. Part I: a systematic review of surgical techniques. *Journal of oral & maxillofacial research*. 2015; 6(1).
- [15] Abayev B, Juodzbalys G. Inferior alveolar nerve lateralization and transposition for dental implant placement. Part II: a systematic review of neurosensory complications. *Journal of oral & maxillofacial research*. 2015; 6(1).
- [16] Vetromilla B, Moura L, Sonogo C, Torriani M, Chagas Jr O. Complications associated with inferior alveolar nerve repositioning for dental implant placement: a systematic review. *International journal of oral and maxillofacial surgery*. 2014; 43(11):1360-6.
- [17] Khojasteh A, Hassani A, Motamedian SR, Saadat S, Alikhasi M. Cortical Bone Augmentation Versus Nerve Lateralization for Treatment of Atrophic Posterior Mandible: A Retrospective Study and Review of Literature. *Clin Implant Dent Relat Res*. 2016; 18(2):342-59.
- [18] Ortega-Lopes R, Andrade VC, N6ia CF, Cidade CPV, CHAVES NETTO HDdM, Mazzonetto R. Retrospective four year analysis in 199 bone grafts of the alveolar ridge. *RGO Revista Gaúcha de Odontologia (Online)*. 2012; 60(1):79-83.
- [19] Kumar BP, Venkatesh V, Kumar KJ, Yadav BY, Mohan SR. Mandibular reconstruction: overview. *Journal of maxillofacial and oral surgery*. 2016; 15(4):425-41.
- [20] Pelo S, Boniello R, Moro A, Gasparini G, Amoruso P. Augmentation of the atrophic edentulous mandible by a bilateral two-step osteotomy with autogenous bone graft to place osseointegrated dental implants. *International journal of oral and maxillofacial surgery*. 2010; 39(3):227-34.
- [21] Sakkas A, Wilde F, Heufelder M, Winter K, Schramm A. Autogenous bone grafts in oral implantology is it still a "gold standard"? A consecutive review of 279 patients with 456 clinical procedures. *International journal of implant dentistry*. 2017; 3(1):23.
- [22] Felice P, Pistilli R, Lizio G, Pellegrino G, Nisii A, Marchetti C. Inlay versus onlay iliac bone grafting in atrophic posterior mandible: a prospective controlled clinical trial for the comparison of two techniques. *Clin Implant Dent Relat Res*. 2009; 11 Suppl 1:e69-82.
- [23] Felice P, Piattelli A, Iezzi G, Degidi M, Marchetti C. Reconstruction of an atrophied posterior mandible with the inlay technique and inorganic bovine bone block: a case report. *Int J Periodontics Restorative Dent*. 2010; 30(6):583-91.
- [24] Marchetti C, Trasarti S, Corinaldesi G, Felice P. Interpositional bone grafts in the posterior mandibular region: a report on six patients. *Int J Peri-*

odontics Restorative Dent. 2007; 27(6):547-55.

- [25] Morad G, Khojasteh A. Cortical tenting technique versus onlay layered technique for vertical augmentation of atrophic posterior mandibles: a split-mouth pilot study. *Implant Dent.* 2013; 22(6):566-71.
- [26] Metcalfe D, Cuff AV, Pidgeon TE, Hewitt KJ, Gibbs VN, Rossiter DJ, et al. Surgical techniques for autologous bone harvesting from the iliac crest in adults. *The Cochrane Database of Systematic Reviews.* 2018; 2018(4).
- [27] Liu J, Kerns DG. Suppl 1: Mechanisms of guided bone regeneration: A review. *The open dentistry journal.* 2014; 8:56.
- [28] Khojasteh A, Hassani A, Motamedian SR, Saadat S, Alikhasi M. Cortical bone augmentation versus nerve lateralization for treatment of atrophic posterior mandible: A retrospective study and review of literature. *Clinical implant dentistry and related research.* 2016; 18(2):342-59.

Please cite this paper as:

Khojasteh A, Azizi Sh; Inferior alveolar nerve repositioning with simultaneous iliac bone autogenous graft for treatment of atrophic posterior mandibular ridge. *J Craniomax Res* 2020; 7(4): 222-227