



Airway cephalometric changes following mandibular setback surgery: A review

Amir Hossein Mirhashemi ¹, Rashin Bahrami ¹, Mahdi Niknami ^{2*}

1. Department of Orthodontics, School of Dentistry, Tehran University of Medical Sciences, Tehran, Iran.

2. Department of Oral and Maxillofacial Radiology, School of Dentistry, Tehran University of Medical Sciences, Tehran, Iran.

ARTICLE INFO

Article Type: Review Article

Received: 3 Apr. 2020

Revised: 2 May. 2020

Accepted: 18 Jul. 2020

*Corresponding author:

Mahdi Niknami

Department of Oral and Maxillofacial Radiology,
School of Dentistry, Tehran University of Medical
Sciences, Tehran, Iran.

Tel: +98-21-84902473

Fax: +98-21-84902473

Email: niknami81@Yahoo.com

ABSTRACT

Background and Aim: Mandibular setback surgery is one of the common treatments in patients with mandibular prognathism. In this surgery, the mandible is placed backward from its original position, and as a result, the soft tissue, tongue, and hyoid bone are slightly displaced, all of which can affect the dimensions of the airway. Given that these changes in the dimensions of the airway can lead to obstructive sleep apnea, it is important to examine these changes and their stability. In this regard, cephalometric radiography can be used, which has low cost and dose in comparison to 3D radiographs, to examine changes in airway dimensions. The aim of this study was to evaluate the short-term and long-term changes in airway dimensions following mandibular setback surgery with the help of cephalometric radiography.

Materials and Methods: The study was conducted by review method. Using the keywords 'orthognathic surgery,' 'mandibular setback,' 'Malocclusion angle class III,' 'prognathism,' 'airway,' 'posterior airway space,' 'PAS,' 'pharyngeal space,' 'hypopharynx,' a review of articles in PubMed and Embase databases, Google Scholar, and Cochrane databases was performed. The range of article searches was from 2000 to 2020.

Conclusion: The results of studies showed that in the first 6 months after surgery, the dimensions of the airway decrease, but over time, due to the adaptation of the surrounding tissues and relapse after surgery, there is an improvement in the dimensions of the airway; Also, the study of index-related breathing disorders during sleep disorders during sleep showed that this surgery does not necessarily lead to obstructive sleep apnea.

Keywords: Orthognathic surgery; Mandibular setback; Malocclusion angle class III; Prognathism; Airway; Posterior airway space; PAS; Pharyngeal space; Hypopharynx.

Introduction

Obstructive Sleep Apnea is a very common and familiar disorder that can possibly have various impacts on a patient, including extreme drowsiness during the day, snoring, and a considerable amount of increase on the possible incoming risks and threats such as potential car crashes while driving as well as the frequent

occurrence of cardiovascular diseases amongst these types of patients [1]. Both clinical and paraclinical examinations prove to provide extremely useful tools for diagnosing patients who are at potential risk of this particular disorder, these paraclinical observations and examinations involve radiographic images (for instance lateral cephalometry),

sleeping questionnaires (such as OSA-18), as well as diagnostic tests (polysomnography, which is considered to be the appropriate golden standard for identifying and diagnosing this particular condition), in addition to having indicators such as AHI (which can easily assess the severity of apnea by discovering the precise number of apneas and hypopneas that occur during the patient's sleeping period).

The potential risk factors that may very well cause this particular disorder usually fall into two categories: anatomical and non-anatomical, the psychological type issues are considered as one of the major causes amongst these non-anatomical patients [2-4]. Furthermore, the potential anatomical risk factors can be divided into two separated groups, soft & hard tissues, the hard tissue group is analyzed and evaluated as cephalometric type risk factors [5]. Mandibular Setback surgery is a commonly found treatment done in order to fix the mandibular prognathism [6], however, some researchers suggest that performing such surgeries may very much lead to relative narrowing of the upper airways of the patient and can eventually lead to obstructive sleep apnea [7]. On the other hand, according to some, the better method is considered to be performing a double jaw surgery, for not only the better aesthetic and appearance that it can achieve, but for the fact that it has a much lesser extent in affecting the anatomy of the airways [8,9]. Although, the potential role of this surgery in exacerbating obstructive sleep apnea entirely remains uncertain and debated to this day. In addition, it must be added that a physiological reaction is expected to occur in the aftermath of this particular surgery in order to prevent narrowing of the airways of the patient [10,11]. Finally, the other controversial issue is whether the airway changes resulted from the performed surgery was permanent and if they can also affect skeletal stability in any way whatsoever [12]. The main objective and purpose of this particular study was to review the various effects mandibular setback surgery has on the upper airway dimensions as well as covering obstructive sleep apnea.

Materials and Methods

The present study is a review of the evidence in electronic databases using the keywords 'orthognathic surgery,' 'mandibular setback,' 'Malocclusion angle class III,' 'prognathism,' 'airway,' 'posterior airway space,' 'PAS,' 'pharyngeal space,' 'hypopharynx,' and 'hyoid bone,' and reviewing the articles in PubMed and Embase databases, Google Scholar, and Cochrane. The range of article searches was from 2000 to 2020. After

searching with the mentioned keywords and reviewing each of these articles, 645 articles were found that dealt with the effect of mandibular setback surgery on the dimensions of the upper airway in patients with obstructive sleep apnea, of which 13 articles were in full text and had an entry criterion available. Figure 1 shows how to select articles.

Inclusion and exclusion criteria are presented as follows:

1. Articles that evaluated orthognathic surgery in patients with obstructive sleep apnea.
2. Articles that used lateral cephalometric view to study the dimensions of the airway.
3. Case report studies.
4. Articles that were considered in the period.
5. Articles in English and Persian.
6. The main types of articles and all articles were full text.

Results

Initially, 645 articles (Figure 1) were obtained from databases, of which 531 studies were excluded for reasons such as irrelevance or duplication. However, 101 articles were deleted by two independent reviewers due to lack of inclusion criteria, for example, the use of CBCT to assess the dimensions and morphology of the airway after surgery, surgery on both jaws, or lack of access to the full text of the article. Finally, the last 13 articles included in the study, and a summary of their work results are given in Table 1.

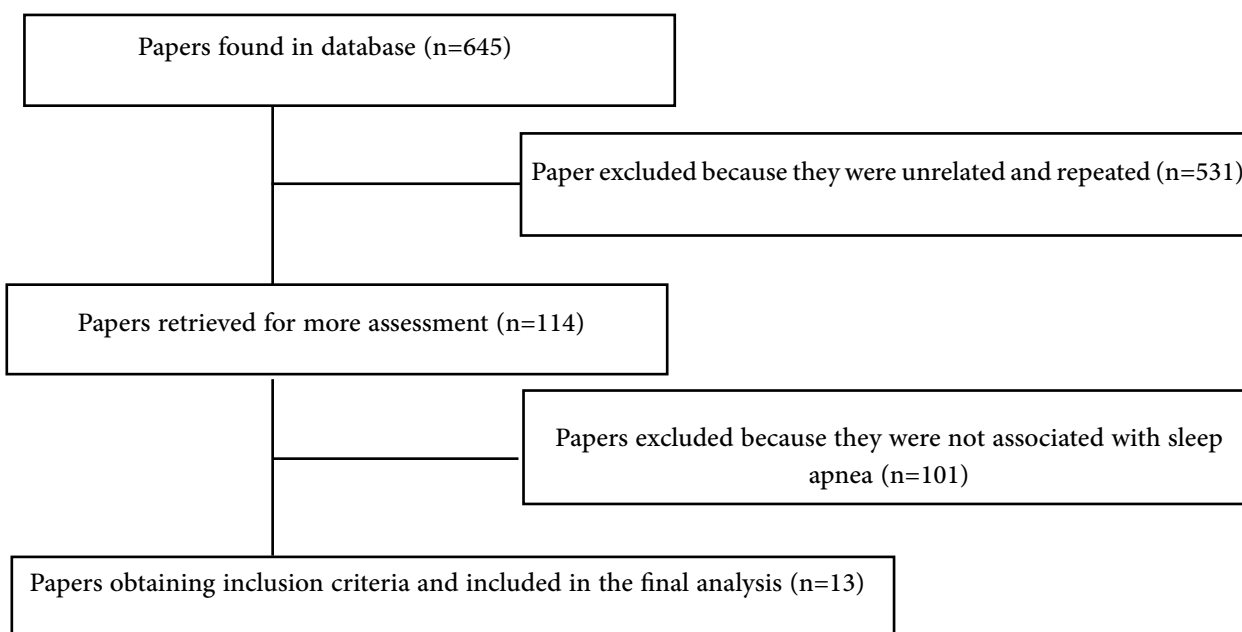


Figure 1. The selection process of papers included in this work.

Publication year	Authors	Objectives	Results
2000	Tselnik ¹³	Assessment of the Pharyngeal Airway Space After Mandibular Setback Surgery	Conducted studies show that patients with high potential risk factors such as overweight, conjunctival neck or large tongue are considered more in danger, and performing mandibular setback surgery on these patients is very likely to cause obstructive sleep apnea and must be avoided.
2000	Achilleos ¹⁴	Surgical mandibular setback and changes in uvula glossopharyngeal morphology and head posture: a short- and long-term cephalometric study in males	Their study results also show that over time, the process of recovery in soft and hard airway tissue occurs, specifically within the lateral cephalometric image of patients who undergo mandibular setback surgery.
2004	Saitoh ¹⁵	Long-term changes in pharyngeal airway morphology after mandibular setback surgery	The result of the conducted study indicates that although, the morphology of the lower segment of the face and the morphology of the pharynx airway both show significant changes after the performance of mandibular setback surgery, however, the morphology of the pharyngeal airway has the ability to gradually and physiologically adapt to its new position.
2005	Eggensperger ¹⁶	Long-term changes of hyoid bone position and pharyngeal airway size following mandibular setback by sagittal split ramus osteotomy	The results of their study showed that the dimensions of the airway initially decreased and also the hyoid bone was lower and backward than its original position, but with the passage of improvement in the dimensions of the airway and the position of the hyoid bone occurs.
2005	Chen ¹⁷	Predicting the Pharyngeal Airway Space After Mandibular Setback Surgery	Conducted study results using lateral cephalometric images showed a reduction in the size of the airway, after the mandibular setback operation taking place.

2005	Kawakami ¹⁸	Changes in tongue and hyoid positions, and posterior airway space following mandibular setback surgery	In addition, the study results also showed that the mandibular setback surgery may possibly cause narrowing of the airway later on, while managing to preserve the original size and dimensions of the airway at the same time, long-term observations must be conducted due to the various changes in the configuration of the pharynx following the possible mandibular disjunction.
2007	Chen ¹⁹	Effects of bimaxillary surgery and mandibular setback surgery on pharyngeal airway measurements in patients with Class III skeletal deformities	Conducted studies also showed that mandibular setback surgery does, in fact, reduce the size and dimensions of the airway by retracting the mandible.
2010	Hwang ²⁰	Changes of hyoid, tongue and pharyngeal airway after mandibular setback surgery by intraoral vertical ramus osteotomy.	Studies indicate that hyoid and tongue both move backwards after the performance of the mandibular setback operation, then tend to return to their previously original position, however, the width of the final pharyngeal airway may remain narrow for a long time, even after years of follow-up checkups.
2010	Demetriades ¹¹	Effects of Mandibular Repositioning, With or Without Maxillary Advancement, on the Oro-Naso-Pharyngeal Airway and Development of Sleep-Related Breathing Disorders	Conducted studies also showed a decrease in sagittal dimensions of the pharyngeal airway (U-MPW) began to appear in the first follow-up analysis and lasted for a long period of time, which, along with the reduction of the remaining oropharynx area, together could cause airway obstruction.
2010	Park ²¹	Volumetric, planar, and linear analyses of pharyngeal airway change on computed tomography and cephalometry after mandibular setback surgery	In addition, we also learnt that due to linear analysis the infrastructure around the jaw moves slightly backwards, after the mandibular setback surgery taking place, besides, a physiological change can be made in order to maintain the airway capacity after sagittal compression.
2011	Hasebe ²²	Changes in oropharyngeal airway and respiratory function during sleep after orthognathic surgery in patients with mandibular prognathism	A large number of mandibular setback surgeries done may interfere with biological adaptations and as a result cause obstructive apnea, furthermore, it may best to possibly consider maxillary advancement or perhaps another available airway technique in order to be able to deal with patients who have high anterior-posterior discrepancies along with skeletal malocclusion class-three, and find a way to treat or prevent it from happening.
2013	Kobayashi ²³	Changes in overnight arterial oxygen saturation after mandibular setback	After approximately six months prior to the mandibular setback surgery taking place, there was no evidence of obstructive apnea at all, because most patients adapted to the new environment for sleep-related respiratory function, however, some patients (especially obese ones) may possibly experience sleep and breathing disorder right after the mandibular setback surgery.
2020	Engboonmeskul ²⁴	Effect of surgical mandibular setback on the occurrence of obstructive sleep apnea	Additionally, the mandibular setback surgery can possibly reduce the dimensions of the airway, although, not every individual will experience obstructive sleep apnea, however, it can predispose a person from obstructive apnea.

Table 1.

Discussion

All the studies conducted so far have indicated a significant reduction in posterior airway space and dimensions caused in the aftermath of the mandibular setback surgery being performed, moreover, Tselnik et al. (2000) discovered the average reduction in the gap between the posterior walls of the pharynx and the tongue of the patient to be approximately (4.7mm from the initial 9.7mm which shows more than 28% reduction rate following the mandibular setback surgery performance), in addition to the average reduction being found in the pharyngeal airway space, which was about 1.52cm that can clearly indicate a 12.8% overall decrease in dimensions. The final results of this particular study suggested the existence of extremely powerful correlations between the mandibular setback surgery and the occurrence of reduction in pharyngeal airway dimensions. Furthermore, the study results obtained by Park et al. (2010) showed that mandibular setback surgery can potentially reduce PAS (posterior airway space from 5 mm to possibly 11mm), (30-75% reduction) [21]. During the process of conducting linear cephalometric analysis on a dozen patients who have all undergone mandibular setback surgery, they managed to observe and discover a significant decrease in pharyngeal depth as well as discovering major posterior movement in the hyoid bone ($P < 0.05$), besides, their study on CT images showed a progressive descending pattern from the initial preoperative period up until six months after the performance of the surgery via C2, C3 and C5. Additionally, the obtained results of cephalometric analysis gathered by Chen et al. (2005) seem to be very consistent with the results that Park et al. had discovered years after [17].

Achilleos et al. (2000), managed to examine the precise position of the hyoid bone using AH \perp S, AH \perp ML and AH \perp FH cephalometric landmarks and their obtained results after the performance of the surgery indicates the occurrence of downward bone displacement during a short period of recovery time (six months after the surgery), however, long-term follow-ups (three years in some cases), showed that the hyoid bone may even move upwards from the initial extent (in other words, the initial placement of the bone before the surgery was done) [14]. Park and his fellow team also stated that the degree of changes in PAS (posterior airway space dimension) can possibly be estimated using various methods and tools including the measurement of the mandibular changes after the performance of the setback surgery along with the regression equation using ANB angle corrections, as well as measuring the

total mandibular length (Co-Gn) and also mandibular plane (SN-GoGn), which can all assist in the process of creating such predictions, specifically taking place six months prior to the performance of the surgery up to eighteen months afterwards, in order to be on point and accurate in our estimations.

Park et al. (2012), managed to indicate that the reduction in airway dimensions may very well last approximately up to eighteen months after the performance of the surgery. Furthermore, the study of long-term effects of the performance of mandibular setback surgery on airway dimensions done by Saitoh et al. (2004), using Wilcoxon examination, show a significant difference in the linear measurements of lower facial morphology (PTV-POG & PTV-L1) (the distance between PTV and Pog on line perpendicular to PTV as well as the distance between PTV and L1 on line perpendicular to PTV), from before the performance of the surgery (T1) up to 3 to 6 months after it was done (T2), in addition, during the follow-up checkups which is done two years from the time the surgery was initially performed (T3), they also mentioned that the difference remains significant, however, the difference in angular measurements such as (SNB, facial axis and facial) are thankfully not that considering after two years. Besides, their study also showed major and significant difference in the linear measurement obtained from (T1) and (T2) along the soft palate of (PRL-PSP, PRL-PTO, PRL-E) (Figure 2,3). Meanwhile, the obtained angular measurements of (PTV/SP) were discovered to be considerably different and unlike the rest. Moreover, linear as well as angular measurements between (T1) and (T3) showed no particular change, while on the other hand, changes discovered in the linear measurements results between (T2) and (T3) seemed significantly different for the length of the soft palate and (PRL-PTO) [15]. Additionally, in the year 2000, Achilleos and his fellow colleagues also examined the changes in soft tissues, using the lateral cephalometric images of the patient, and the results indicated that the length of the soft palate (PM-U) had increased, but due to the long-term follow-up maintenance its condition had remained stable, however, (NL/PM-U) as a result, its position has become slightly more vertical. Finally, during the last conducted follow-up checkups, the length of the tongue (V-T) is discovered to be slightly increased, as well as showing a more upright posture (VT/FH) [14]. Eggenberger et al. (2005), reported the average airway reduction right after the performance of mandibular setback surgery to be approximately 0.30mm, on the other hand [16], Hwang et al. (2010), reported a different average

reduction which was about 0.67mm [20]. Additionally, the average airway space change from the initial time of the surgery up to one to six months afterwards, was first indicated and then reported by Eggenesperger et al. to be approximately 0.70mm, while Huang et al. recorded a 1.63mm being changed. After a year prior to the surgery, Eggenesperger et al. reported an airway reduction rate of 0.10mm, while Haunget al. reached 1.19mm, both of the results of their study show an increase in the airway space over time. Generally, most studies have attributed these changes to the adaptation of the airway morphology to the new current position, and according to Eggenesperger et al. it is due to skeletal relapse happening after the treatment [16,20].

However, despite the occurrence of changes along the airway space dimensions in the aftermath of mandibular setback surgery, respiratory parameters including apnea-hypopnea index did not seem to change in a major way after its performance. Moreover, there is always an existing disagreement about arterial oxygen saturation. On the other hand, according to Hasib et al. (2011), (SpO₂) always tends to increase, however, Kobayashi al. 2013, found out that despite the overall decrease that occurs on the initial day of the surgery, the level degree gradually increases and returns to normal after approximately six months. Furthermore, according to both (Hasebe et al. 2008 and Kobayashi et al. 2013) following the mandibular setback surgery [18,22], SpO₂, ODI and CT90, the final results show no major or significant changes occurring during the six months after the initial operation, additionally, a set of questionnaire is given to the patients in order to indicate whether they were more likely to snore following this particular procedure, besides, it has been confirmed that patients with high potential risk factors such as obesity who are extremely prone to obstructive sleep apnea, must be informed that performing surgeries such as mandibular setback surgery may very possibly cause obstructive sleep apnea for them.

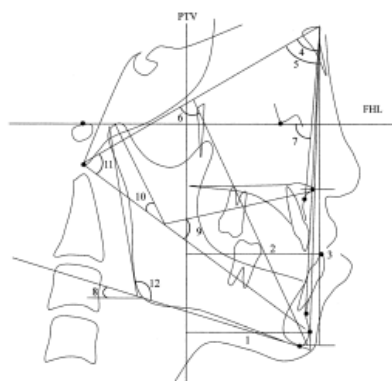


Figure 2. Measurements of lower facial morphology: FHL, Frankfort horizontal line; PTV, line perpendicular to FHL passing through PT point; 1, PTV-Pog, Distance between PTV and Pog on line perpendicular to PTV; 2, PTV-L1, distance between PTV; 3, ANS-Me, distance between ANS and Me on McNamara line; 4, SNA; 5, SNB; 6, facial axis; 7, facial depth; 8, mandibular plan; 9 lower face height; 10, mandible arc; 11, total facial height; 12, gonial angle.

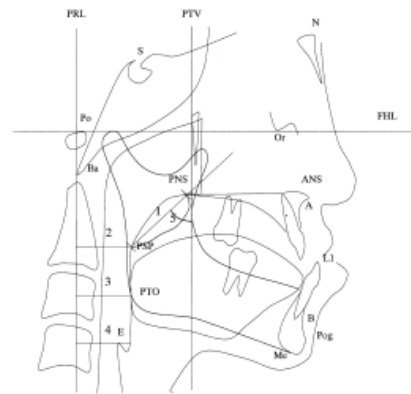


Figure 3. Lateral cephalometric landmarks and measurements of pharyngeal airway morphology: N, nasion; S sella; Or, orbitale; Po, Porion; ANS, anterior spine; PNS, posterior nasal spine; Pog, pogonion; Ba, basion; Me menton; A, Point A; B, Point B; L1, lower incisor; PSP, most posterior point of soft palate; PTO, point crossing mandibular inferior border in posterior area of tongue; E, most superior point of epiglottis; FHL, Frankfort horizontal line; PTV, line perpendicular to FHL passing through PT point; PRL, line perpendicular to FHL passing Po; 1, SP length (PNS-PSP); 2, PRL-PSP (horizontal distance between PRL and PSP); 3, PRL-PTO (horizontal distance between PRL and PTP); 4, PRL-E (horizontal distance between PRL and frontal wall of pharyngeal air way passing E); 5, PTV/SP angle (angle formed by PTV and SP length line).

Conclusion

Based entirely on the discoveries of our conducted studies we conclude that: After only performing mandibular setback surgery alone, a significant reduction in airway dimensions is likely to occur. Postoperative discoveries obtained from arterial oxygen saturation, O₂ saturation index, CT90 and apnea/hypopnea index do not show any major long-term changes whatsoever. Therefore, as a result, there is no available evidence that suggests mandibular setback surgery predisposes an individual to obstructive sleep apnea as the new oral ducts eventually learn to adapt to the new and current situation.

Conflict of Interest

There is no conflict of interest to declare.

References

- [1] Veasey SC, Rosen IM. Obstructive sleep apnea in adults. *New England Journal of Medicine*. 2019 Apr 11; 380(15):1442-9.
- [2] Osman AM, Carter SG, Carberry JC, Eckert DJ. Obstructive sleep apnea: current perspectives. *Nature and science of sleep*. 2018; 10:21.
- [3] Mirhashemi AH, Arab S, Bahrami R. Orthodontics as a therapeutic tool for managing sleep apnea: A review. *Journal of Craniomaxillofacial Research*. 2020 Oct 3:50-61.
- [4] Vitale GJ, Capp K, Ethridge K, Lorenzetti MS, Jeffrey M. Sleep Apnea and the Brain: Neurocognitive and Emotional Considerations. *Journal of Sleep Disorders and Management*. 2016; 2(1):8-12.
- [5] Bayat M, Shariati M, Rakhshan V, Abbasi M, Fateh A, Sobouti F, Davoudmanesh Z. Cephalometric risk factors of obstructive sleep apnea. *CRANIO®*. 2017 Sep 3; 35(5):321-6.
- [6] Kawamata A, Fujishita M, Arijii Y, Arijii E: Three-dimensional computed tomographic evaluation of morphologic airway changes after mandibular setback osteotomy for prognathism. *Oral Surg Oral Med Oral Pathol Oral Radiol Endod* 89:278e287.
- [7] Turnbull NR, Battagel JM: The effects of orthognathic surgery on pharyngeal airway dimensions and quality of sleep. *J Orthod* 27: 235e247.
- [8] Park SB, Kim YI, Son WS, Hwang DS, Cho BH: Cone-beam computed tomography evaluation of short- and long-term airway change and stability after orthognathic surgery in patients with class III skeletal deformities: bimaxillary surgery and mandibular setback surgery. *Int J Oral Maxillofac Surg* 41: 87e93.
- [9] Schulz KF, Altman DG, Moher D, CONSORT Group: CONSORT 2010 Statement: updated guidelines for reporting parallel group randomised trials. *BMC Med* 24(8): 18.
- [10] Park JW, Kim NK, Kim JW, Kim MJ, Chang YI: Volumetric, planar, and linear analysis of pharyngeal airway change on computed tomography and cephalometry after mandibular setback surgery. *Am J Orthod Dentofacial Orthop* 138: 292e299.
- [11] Demetriades N, Chang DJ, Laskarides C, Pappageorge M: Effects of mandibular retropositioning, with or without maxillary advancement, on the oro-nasopharyngeal airway and development of sleep-related breathing disorders. *J Oral Maxillofac Surg* 68: 2431e2436.
- [12] Gonçales ES, Duarte MAH, Palmieri Jr C, Zakhary GM, Ghali GE: Retrospective analysis of the effects of orthognathic surgery on the pharyngeal airway space. *J Oral Maxillofac Surg*.
- [13] Tselnik M, Pogrel MA. Assessment of the pharyngeal airway space after mandibular setback surgery. *Journal of oral and maxillofacial surgery*. 2000 Mar 1; 58(3):282-5.
- [14] Achilleos S, Krogstad O, Lyberg T. Surgical mandibular setback and changes in uvuloglossopharyngeal morphology and head posture: a short- and long-term cephalometric study in males. *The European Journal of Orthodontics*. 2000 Aug 1; 22(4):383-94.
- [15] Saitoh K. Long-term changes in pharyngeal airway morphology after mandibular setback surgery. *American journal of orthodontics and dentofacial orthopedics*. 2004 May 1; 125(5):556-61.
- [16] Eggensperger N, Smolka W, Iizuka T. Long-term changes of hyoid bone position and pharyngeal airway size following mandibular setback by sagittal split ramus osteotomy. *Journal of Cranio-Maxillofacial Surgery*. 2005 Apr 1; 33(2):111-7.
- [17] Chen F, Terada K, Hanada K, Saito I. Predicting the pharyngeal airway space after mandibular setback surgery. *Journal of oral and maxillofacial surgery*. 2005 Oct 1; 63(10):1509-14.
- [18] Kawakami M, Yamamoto K, Fujimoto M, Ohgi K, Inoue M, Kirita T. Changes in tongue and hyoid positions, and posterior airway space following mandibular setback surgery. *Journal of Cranio-Maxillofacial Surgery*. 2005 Apr 1; 33(2):107-10.

- [19] Chen F, Terada K, Hua Y, Saito I. Effects of bimaxillary surgery and mandibular setback surgery on pharyngeal airway measurements in patients with Class III skeletal deformities. *American journal of orthodontics and dentofacial orthopedics*. 2007 Mar 1; 131(3):372-7.
- [20] Hwang S, Chung CJ, Choi YJ, Huh JK, Kim KH. Changes of hyoid, tongue and pharyngeal airway after mandibular setback surgery by intraoral vertical ramus osteotomy. *The Angle orthodontist*. 2010 Mar 1; 80(2):302-8.
- [21] Park JW, Kim NK, Kim JW, Kim MJ, Chang YI. Volumetric, planar, and linear analyses of pharyngeal airway change on computed tomography and cephalometry after mandibular setback surgery. *American journal of orthodontics and dentofacial orthopedics*. 2010 Sep 1; 138(3):292-9.
- [22] Hasebe D, Kobayashi T, Hasegawa M, Iwamoto T, Kato K, Izumi N, Takata Y, Saito C. Changes in oropharyngeal airway and respiratory function during sleep after orthognathic surgery in patients with mandibular prognathism. *International journal of oral and maxillofacial surgery*. 2011 Jun 1; 40(6):584-92.
- [23] Kobayashi T, Funayama A, Hasebe D, Kato Y, Yoshizawa M, Saito C. Changes in overnight arterial oxygen saturation after mandibular setback. *British Journal of Oral and Maxillofacial Surgery*. 2013 Jun 1; 51(4):312-8.
- [24] Engboonmeskul T, Leepong N, Chalidapongse P. Effect of surgical mandibular setback on the occurrence of obstructive sleep apnea. *Journal of Oral Biology and Craniofacial Research*. 2020 Oct 1; 10(4):597-602.

Please cite this paper as:

Mirhashemi AH, Bahrami R, Niknam M; Airway cephalometric changes following mandibular setback surgery: A review. *J Craniomax Res* 2020; 7(4): 178-185