



## Rotation of the maxillomandibular complex in orthognathic surgery: A review

Mahbube Sadat Hasheminasab<sup>1</sup>, Mahsa Mortazavi<sup>2</sup>, Reza Sharifi<sup>1</sup>, Farzaneh Bolandparva<sup>1\*</sup>

1. Department of Oral & Maxillofacial Surgery, Craniofacial Research Center, Shariati Hospital, Tehran University of Medical Sciences, Tehran, Iran.

2. Department of Orthodontics, University of the Pacific, Arthur A. Dugoni School of Dentistry.

### ARTICLE INFO

#### Article Type: Review Article

Received: 2 Jun. 2019

Revised: 8 Aug. 2019

Accepted: 15 Oct. 2019

#### \*Corresponding author:

Farzaneh Bolandparva

Department of Oral & Maxillofacial Surgery,  
Craniofacial Research Center, Shariati  
Hospital, Tehran University of Medical Sciences,  
Tehran, Iran.

Tel: +98-912-7642154

Fax: +98-21-84902473

Email: f.bolandparva@gmail.com

### ABSTRACT

**Introduction:** In orthognathic surgery, maxillomandibular complex (MMC) refers to a three-dimensional dento-osseous structure consisting of the surgically-mobilized part of the maxilla together with the distal segment (i.e., tooth bearing segment) of the mandible (either surgically mobilized or not). In fact, MMC is the skeletal part of the lower face. The size, shape and position of MMC play a major role in soft tissue esthetics of the lower face.

**Materials and Methods:** A comprehensive review of the current data regarding effects of maxillomandibular complex rotation in sagittal plane, on "occlusal plane, TMJ, sleep apnea, paranasal soft tissues, upper lip, chin, cervicomenta soft tissues" was conducted.

**Results:** MMC rotation and translation could take place in any of the three planes of reference including sagittal, coronal, and horizontal. Any kind of changes in the position of MMC could have its own functional and esthetic consequences. In general, patients with convex facial profiles require counter clockwise rotation while patients with concave profiles require clockwise rotation.

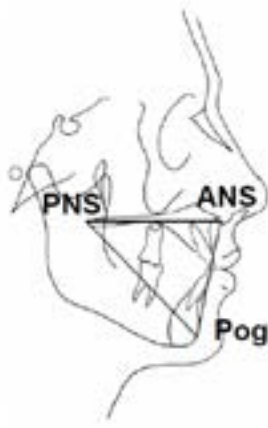
**Conclusion:** MMC not only has great impacts on facial esthetics, but also has significant functional effects, for example in breathing and mastication. Alteration in the position of MMC is possible by orthognathic surgery.

**Keywords:** Maxillomandibular complex (MMC); Orthognathic surgery; Consequences of MMC rotation.

### Introduction

In orthognathic surgery, maxillomandibular complex (MMC) refers to a three-dimensional dento-osseous structure consisting of the surgically-mobilized part of the maxilla together with the distal segment (i.e., tooth bearing segment) of the mandible (either surgically mobilized or not) [Fig. 1] [1]. In fact, MMC is the skeletal part of the lower face. The size, shape and position of MMC play a major role in soft tissue esthetics of the lower face. For example, fullness of the paranasal areas, position and projection of the upper lip, the shape of the mentolabial

fold, the position of the soft tissue pogonion, and even the esthetics of the cervicomenta soft tissues are directly dependent on the size, shape, and position of the underlying MMC. Furthermore, MMC not only has great impacts on facial esthetics, but also has significant functional effects, for example in breathing and mastication.



*Fig 1.* The MMC is represented by a triangle connecting ANS, PNS, and Pog.

To some extent, the shape of MMC could be changed by orthodontics and orthognathic surgery. Changing the inclination of maxillary incisors by orthodontics or changing the inclination of mandibular incisors by anterior segmental osteotomy of the mandible are two examples of shape change in MMC. The size of MMC could also be changed to some extent. For example by surgically-assisted palatal expansion or maxillary down-grafting. Alteration in the position of MMC is possible by orthognathic surgery. A change of MMC position could be achieved by translation, rotation, or a combination of both. MMC rotation and translation could take place in any of the three planes of reference including sagittal, coronal, and horizontal. In theory, alteration in the position of MMC could occur by a pure translation or a pure rotation in only one of the three planes of reference. But, in practice, surgical alteration of the MMC position occurs as a combination of translation and rotation in more than one plane of reference. Any kind of changes in the position of MMC could have its own functional and esthetic consequences. In this paper, only the considerations and consequences of MMC rotation in the sagittal plane is discussed.

### **MMC rotation in the sagittal plane**

MMC rotation in the sagittal plane is a kind of treatment plan in orthognathic surgery, with a variety of different esthetic and functional consequences. This kind of treatment plan is sometimes called “rotation of the occlusal plane”, but this is a less suitable term because rotation of the occlusal plane is only one of the many consequences of MMC rotation [2]. MMC rotation in the sagittal plane necessarily requires surgical mobilization of the maxilla by one of the various types of Le Fort osteotomy. Most often, the distal segment of the

mandible is also surgically mobilized by sagittal split ramus osteotomy or other types of mandibular osteotomy. However, limited amount of MMC rotation in the sagittal plane could take place without mandibular osteotomy, due to the capacity of the distal segment.

To auto-rotate around the temporomandibular joint (TMJ) axis. Auto-rotation is a technical term in orthognathic surgery that refers to rotation of an intact mandible as a whole in the sagittal plane around TMJ axis. Therefore, MMC rotation in the sagittal plane does not necessarily require two-jaw (or bimax) surgery. Functional and esthetic consequences of MMC sagittal rotation depends on three important factors: the position of the axis of rotation, the direction of rotation (i.e., clockwise or counter-clockwise), and the amount of rotation.

Any line perpendicular to the sagittal plane (whether passing through MMC or not) is potentially an axis around which MMC could be rotated surgically. Therefore, from a geometric point of view, there are infinite number of axes of rotation. However, when surgeons are planning a surgical procedure and setting treatment goals, they most often select one of the following lines as the axis of rotation: 1) the edge of the maxillary central incisors; 2) a line passing through point A; 3) a line passing through anterior nasal spine (ANS); 4) a line passing through the cusp tips of maxillary first premolars; 5) a line passing through the cusp tips of maxillary first molars; and 6) a line passing through pogonion, 7) a line passing through zygomatic maxillary buttress.

MMC rotation occurs in either a clockwise [Fig 2, a] or a counter-clockwise [Fig 2, b] direction. Obviously, the direction of rotation is observer-dependent. Whether rotation of an object is clockwise or counter-clockwise depends on the position of the observer with regard to the orientation of the object. As a consensus, to properly describe the direction of rotation, the patient or the representation of MMC (e.g., a pair of study casts, a lateral cephalometric radiograph, or a 3D image) should be oriented so that the anterior teeth are toward the right hand of the observer and posterior teeth are toward the left hand [3].

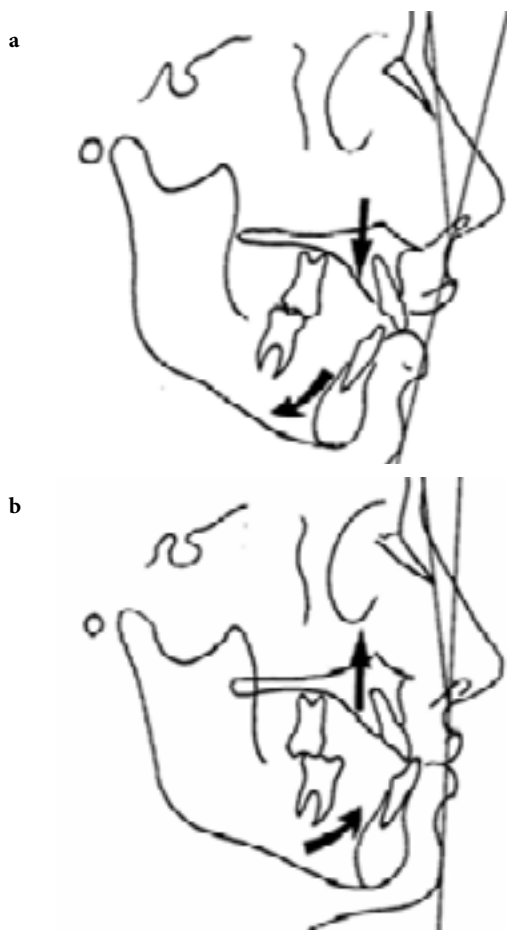


Fig 2. Clockwise rotation (CR) (a) and counter clockwise rotation (CCR) of MMC (b).

### Stability of MMC rotation

Clockwise MMC rotation is a well-accepted treatment plan, while counter-clockwise rotation is less commonly accepted, mainly due to the concerns about stability of the surgical outcomes. However, it has been demonstrated that counter-clockwise rotation is also stable if surgery and presurgical orthodontics are performed properly, and if TMJs are Healthy [4,5]. In fact, the idea that counter-clockwise rotation is unstable and unpredictable belongs to the past. Modifications of surgical techniques and development of rigid fixation have significantly improved long-term outcomes of counter-clockwise rotation. It is commonly believed that stability of clockwise MMC rotation is primarily due to the fact that it does not stretch the pterygomasseteric sling. Likewise, the conjectured instability of counter-clockwise rotation is attributed to its tendency to stretch the masseter and medial pterygoid muscles.

### MMC rotation and the occlusal plane

Occlusal plane angle is the angle between Frankfort horizontal plane and the occlusal plane. But there is not a consensus on the definition of the occlusal plane,

and different definitions are used in different studies. Some authors [4] define occlusal plane angle as a line extending from the cusp tips of the lower premolars to the buccal groove of the second molar. This is not a precise definition because the buccal groove is not an anatomic landmark visible in lateral cephalometric radiographs. Furthermore, buccal groove is not a point; it is a line. Some authors [2,6]. Use the Downs definition, in which the occlusal plane is defined as a line bisecting the overlapping cusps of first molars and the incisal overbite [7].

### Effects of MMC rotation on TMJ

Effects of MMC rotation on TMJ are mainly due to alteration of the occlusal plane angle and occlusion. It has been suggested that as the slope of the occlusal plane increases and begins to approach the slope of TMJ articular eminence, certain functional problems may develop, including loss of canine rise occlusion, loss of incisal guidance, and occurrence of occlusal interferences in posterior teeth [4]. This means that if we accept the concept of “protected occlusion”, we must also accept that increasing the occlusal plane angle in certain patients may put them at increased risk of TMD and dental problems. A large counter-clockwise MMC rotation could produce a small but significant long-term decrease in TMJ space [8].

### MMC rotation and sleep apnea

Counter clockwise MMC rotation increases superior airway space and decreases the incidence of sleep-related breathing disorders [9]. In contrast, clockwise rotation may predispose patients to sleep apnea or hypopnea due to posterior displacement of the tongue base and narrowing of the oropharyngeal airway [4]. However, it seems that the adverse effects of clockwise rotation on the pharyngeal airway space are transitory and significantly subsides 6 months after surgery, probably due to soft tissue adaptation [10]. Nevertheless, it is better to avoid clockwise MMC rotation in patients with sleep-related breathing disorders.

### Effects of MMC rotation on paranasal soft tissues

Paranasal soft tissue changes following the rotation of MMC mainly depends on the center of rotation. In clockwise MMC rotation; if the axis of rotation is higher than the incisal edge (for example, point A or ANS), paranasal and subnasal areas will be less affected. While rotation at lower points (incisor tip and pogonion) will increase paranasal fullness and advance subnasal area [11].

In Counter clockwise rotation of MMC; if the axis of rotation is more anterior (for example, ANS) changes in paranasal and subnasale area will be minimal. Whereas, rotation at posterior point (PNS) will increase paranasal fullness and will advance subnasal area [11].

#### Effects of MMC rotation on the upper lip

In clockwise rotation of MMC; rotation at incisor tip has no effect on upper lip support. If the point of rotation is higher than this point (for example, ANS) upper lip support will decrease. While, rotation below incisor tip (for example, pog) will increase lip support. Despite the point of rotation, counter clockwise rotation of MMC will always increase upper lip support [11].

#### Effects of MMC rotation on the chin

Clockwise rotation decreases chin projection. While, counter clockwise rotation will increase it. The higher the point of rotation above pogonion, the greater changes on chin projection will occur [11].

#### Effects of MMC rotation on cervicomental soft tissues

Clockwise rotation (CR) of MMC decreases chin throat length, unlike counter clockwise rotation. Though, CR is preferred in patients with concave profile and CCR in those with convex profile [11].

#### Orthodontic preparation for MMC rotation

The goals of presurgical orthodontics somewhat depend on whether MMC is intended to be rotated by surgery. Therefore, if the surgeon plans to rotate MMC (particularly if the amount of rotation is relatively large), this should be clearly communicated with orthodontist.

### Conclusion

In general, patients with convex facial profiles require counter clockwise rotation while patients with concave profiles require clockwise rotation [12].

### Conflict of Interest

There is no conflict of interest to declare.

### References

- [1] Reyneke JP. Rotation the maxillomandibular complex: an alternative surgical design in orthognathic surgery [academic dissertation]. Tampere, Finland: University of Tampere, Institute of Regenerative Medicine. 2006. Figure 18, maxillo-mandibular complex; p.35.
- [2] Reyneke JP, Bryant RS, Suuronen R, Becker PJ. Postoperative skeletal stability following clockwise and counter-clockwise rotation of the maxillo-mandibular complex compared to conventional orthognathic treatment. *British Journal of Oral and Maxillofacial Surgery*. 2007 Jan 1; 45(1):56-64.
- [3] Reyneke JP. Rotation the maxillomandibular complex: an alternative surgical design in orthognathic surgery [academic dissertation]. Tampere, Finland: University of Tampere, Institute of Regenerative Medicine. 2006. Figure 15a, b; p.27.
- [4] Wolford LM, Chemello PD, Hilliard F. Occlusal plane alteration in orthognathic surgery—Part I: Effects on function and esthetics. *American Journal of Orthodontics and Dentofacial Orthopedics*. 1994 Sep 1; 106(3):304-16.
- [5] Chemello PD, Wolford LM, Buschang PH. Occlusal plane alteration in orthognathic surgery—part II: long-term stability of results. *American Journal of Orthodontics and Dentofacial Orthopedics*. 1994 Oct 1; 106(4):434-40.
- [6] Lee SW, Cho J, Kim K, Ahn SH. Frontal changes in the lower face after clockwise rotation of the maxillomandibular complex without perisurgical orthodontic treatment in angle class I and skeletal class III women. *Aesthetic plastic surgery*. 2017 Jun 1; 41(3):641-9.
- [7] Downs WB. Analysis of the dento-facial profile. *Angle Orthod* 1956; 26:191-212.
- [8] Cottrell DA, et al. Condylar change after upward and forward rotation of the maxillomandibular complex. *American journal of orthodontics and dentofacial orthopedics*. 1997 Feb 1; 111(2):156-62.
- [9] De Sousa Miranda W, et al. Three-dimensional evaluation of superior airway space after orthognathic surgery with counter clockwise rotation and advancement of the maxillomandibular complex in Class II patients. *Oral surgery, oral medicine, oral pathology and oral radiology*. 2015 Oct 1; 120(4):453-8.
- [10] Choi JW, Park YJ, Lee CY. Posterior pharyngeal airway in clockwise rotation of maxillomandibular complex using surgery-first orthognathic approach. *Plastic and Reconstructive Surgery Global*

Open. 2015 Aug; 3(8).

- [11] Reyneke JP. Rotation the maxillomandibular complex: an alternative surgical design in orthognathic surgery [academic dissertation]. Tampere, Finland: University of Tampere, Institute of Regenerative Medicine. 2006.
- [12] Reyneke, J. P. (2016). Rotation of the Maxillomandibular Complex. In Orthognathic Surgery (Eds F. B. Naini and D. S. Gill). doi:10.1002/9781119004370.ch31.

*Please cite this paper as:*

Hasheminasab M, Mortazavi M, Sharif R, Bolandparva F; Rotation of the maxillomandibular complex in orthognathic surgery: A review. *J Craniomax Res* 2019; 6(4): 138-142