



Two-point osteotomy technique in bilateral sagittal split osteotomy of mandible

Alireza Parhiz, Hamid Mojtahedi *

Department of Oral and Maxillofacial Surgery, Tehran University of Medical Sciences, Tehran, Iran.

ARTICLE INFO

Article Type: Technical Note

Received: 21 Mar. 2019

Revised: 10 May. 2019

Accepted: 15 Jun. 2019

*Corresponding author:

Hamid Mojtahedi

Department of Oral and Maxillofacial Surgery, Tehran University of Medical Sciences, Tehran, Iran.

Tel: +98-21-84902473

Fax: +98-21-84902473

Email: hamid.mojtahedi91@Yahoo.com

ABSTRACT

Today bilateral sagittal split osteotomy technique is one of the main surgical methods used in mandibular deformities surgical correction. Since, the osteotomy design has an important role in decreasing BSSO complications, we developed a technique which restrict the osteotomy points to posterior medial ramus cut and anterior vertical cut in widely used hunsuck modification for decreasing the complications.

Keywords: Sagittal split ramus osteotomy; Orthognathic surgery; Skeletal deformity.

Introduction

Nowadays in orthognathic surgery, bilateral sagittal split osteotomy (BSSO) is a common procedure for treatment of mandibular deformities. The technique was first introduced by Obwegeser and trauner in 1957, which it follows by various modification afterwards [1]. although it's well-designed and valuable technique for any kind of mandibular surgical movements, it's an technical and sensitive procedure that might be associated with several complications [2].

It's reported that osteotomy design has an important role in decreasing BSSO complications and difficulties such as unfavorable bad splits, inferior alveolar nerve (IAN) injury, great vessel injures and prolonged surgery time [2]. Therefor we developed a technique which restrict the osteotomy points to posterior medial ramus cut and

anterior vertical cut in widely used hunsuck modification for decreasing the aforementioned complications. Up to now, this technique had been used by senior author alireza parhiz in over 200 mandibular bilateral sagittal split osteotomies, and has been successful in splitting the mandibular segments without unfavorable fractures and direct IAN injury.

Surgical Technique

Once surgical access of BSSO has been performed, the posterior medial ramus, oblique and anterior vertical bone cuts are made in the traditional manner by reciprocating saw and bures [3].

Afterward we need to make sure that all of the cuts are complete through the cortex and cancellous bone. Although it's suggested that the osteotomies should progress from anterior to posterior conventionally, this report is about starting the osteotomy by straight chisels at medial ramus, the area which hazards condylar and posterior distal segment bad splits (Fig 1, 2). Early posterior disjunction of segments prevents bad splits involving condylar process which is challenging to treat [4]. Unfavorable bad splits needs extra stabilization and more stripping of periosteum, then might be a higher post operation swelling and unfortunate more timing of surgery [5]. As well Comminution of fracture segments interfere with bony union and increase the infection rate [5].

So at first we need to make sure about first point at the highest end of osteotomy site in medial ramus area. The osteotomy is then finished at the anterior second point at vertical buccal cut with chisel, taking care to protect soft tissues with channel retractor (Fig 3, 4). In our over 200 BSSO experience, without manipulation of mid-oblique bone cut with ostetomes at external oblique ridge area, the splitting of mandibular segments is successfully done. The risk of direct IAN injury increases by direct handling of nerve during BSSO procedure [6]. Therefor performing the osteotomy at oblique cut area, where the nerve is crossing through the mandibular body, should be prevented (Fig 5). Theodossy found that timing of surgery more than 3 hours could be a risk factor for infection [7]. Confining the osteotomy into two most significant sits of mandible, who the success of splitting is depends on, could be time saving in BSSO procedure.

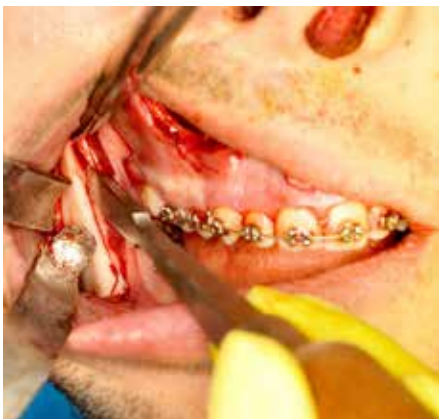

Fig. 1. 12-mm-wide Lexer bone chisel is used to tap along the medial ramus area in most superior and posterior site of osteotomy.

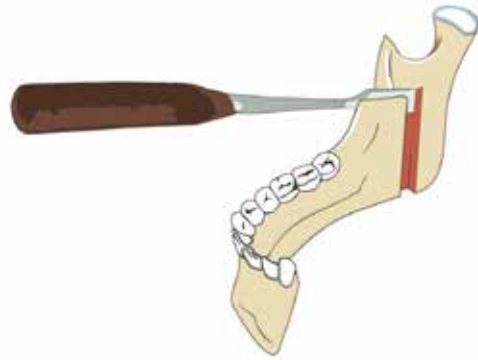


Fig 2. Posterior first point osteotomy was made along medial ramus area by bone chisel.

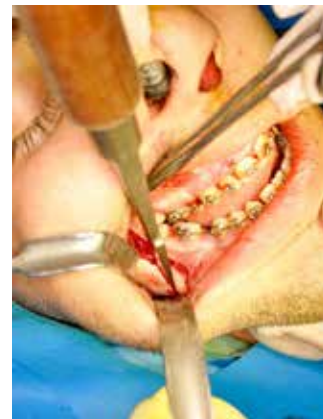

Fig 3. The bone chisel is keeping just inside the buccal cortex, taking care to support the mandible at the inferior border with the channel retractor.

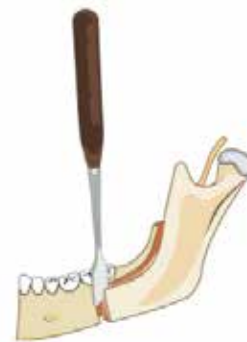

Fig 4. Anterior second point osteotomy was made along buccal cortex area by bone chisel.

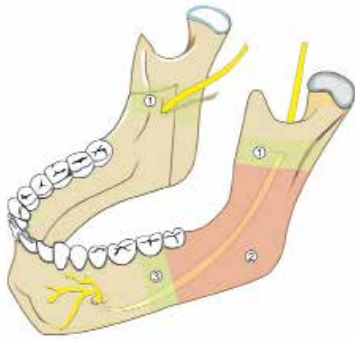


Fig 5. Tapping is restricted to most anterior and posterior sites of osteotomy (zone 1 and 3). The risk of direct nerve injury increased by tapping at mid-oblique site of osteotomy (zone 2).

Conflict of Interest

There has been no conflict of interest in this study.

References

- [1] Obwegeser H. Zur Operationstechnik bei der Progenie und anderer Unterkieferanomalien. Dtsch, Z Mund Kieferheilk. 1955; 23:1-26.
- [2] Verweij JP, Houppermans PN, Gooris P, Mensink G, van Merkesteyn JR. Risk factors for common complications associated with bilateral sagittal split osteotomy: a literature review and meta-analysis. Journal of Cranio-Maxillofacial Surgery. 2016; 44(9):1170-80.
- [3] Hunsuck E. A modified intraoral sagittal splitting technique for correction of mandibular prognathism. J Oral Surg. 1968; 26:249-52.
- [4] Veras R, Kriwalsky M, Hoffmann S, Maurer P, Schubert J. Functional and radiographic long-term results after bad split in orthognathic surgery. International journal of oral and maxillofacial surgery. 2008; 37(7):606-11.
- [5] Chrcanovic BR, Freire-Maia B. Risk factors and prevention of bad splits during sagittal split osteotomy. Oral and maxillofacial surgery. 2012; 16(1):19-27.
- [6] Politis C, Lambrichts I, Sun Y, Vrielinck L, Schepers S, Agbaje JO. Attachment rate of the inferior alveolar nerve to buccal plate during bilateral sagittal split osteotomy influences self-reported sensory impairment. Journal of Craniofacial Surgery. 2014; 25(6):2121-6.
- [7] Theodossy T, Jackson O, Petrie A, Lloyd T. Risk factors contributing to symptomatic plate removal

Please cite this paper as:

Parhiz A, Mojtahedi H; Two-point osteotomy technique in bilateral sagittal split osteotomy of mandible. J Craniomax Res 2019; 6(3): 129-131