



Measurement of buccal cortical plate thickness in the mandible of dentate adults in an Iranian population using cone-beam computed tomography

Zahra Ghoncheh ^{1*}, Behrang Moghaddamzadeh ², Hanieh Kaviani ¹, Golshan Jamali ¹, Maral Feizi ³

1. Department of Oral and Maxillofacial Radiology, Dental School, Tehran University of Medical Sciences International Campus, Tehran, Iran.

2. Department of Oral and Maxillofacial Radiology, Tehran, Iran.

3. Private Practice, Tehran, Iran.

ARTICLE INFO

Article Type:
Original Article

Received: 6 Sep. 2018

Revised: 18 Nov. 2018

Accepted: 19 Jan. 2019

*Corresponding author:

Zahra Ghoncheh

Department of Oral and Maxillofacial Radiology,
Dental School, Tehran University of Medical Sciences International Campus, Tehran, Iran.

Tel: +98-912-3056657

Fax: +98-21-55851141

Email: m_ghoncheh@hotmail.com

ABSTRACT

Objectives: This study aimed to measure the buccal cortical plate thickness in the mandible of dentate adults in an Iranian population using cone-beam computed tomography (CBCT).

Materials and Methods: Eighty CBCT images were evaluated in this study using NNT Viewer 6.0 software. Images had high-resolution and had been taken by NewTom CBCT scanner with 11 x 8cm field of view. Measurements were made using the digital ruler of the software with 0.1mm accuracy. All analyses were performed by two observers: an oral and maxillofacial radiologist and a general dentist. In case of disagreement between the observers, measurements were repeated and the mean value was used for analysis. Data were analyzed by using linear regression.

Results: The results showed that the thickness of buccal cortical plate increased from the canine towards the second molar site. The second molar site had the greatest density and thickness. Gender had a significant effect on the thickness of buccal cortical plate ($P < 0.05$) but the effect of right/left quadrant was not significant ($P > 0.05$). The effect of age on this thickness was insignificant in some ($P > 0.05$) and significant ($P < 0.05$) in some other areas such that by an increase in age of patients, this thickness decreased (i.e. at the apex of canine, second premolar and second molar teeth).

Conclusion: The buccal cortical plate thickness of the mandible increases from the anterior towards the posterior region, and the second molar area has the greatest thickness and density suitable for placement of orthodontic mini-implants or harvesting autogenous grafts.

Keywords: Buccal cortical plate; Mandible; Cone-beam computed tomography; Mini-implant.

Introduction

The thickness of the mandibular buccal cortical plate is the distance from the external cortex of the buccal plate of the mandible to the tooth roots and the mandibular canal [1]. The buccal cortical plate thickness and its density are important factors affecting the prognosis of mandibular fixation procedures with mini-implants, implant treatment, grafting and surgical procedures per-

formed close to the inferior alveolar nerve due to the risk of traumatization of vital structures [2,3]. Mini-implants, also called mini-screws, have been designed for orthodontic anchorage and can be easily placed in different areas due to small length and width [3].

To prevent neurosensory disturbances, accurate measurement of the distance from the superior and buccal border of mandible to the superior and buccal border of the inferior alveolar canal is required prior to placement of mini-implants. Also, it is necessary to have adequate knowledge about the anatomical variations of the inferior alveolar nerve, and such data are often obtained from three-dimensional (3D) images [4]. In general, the thickness of buccal cortical plate of the mandible increases towards the apical and posteriorly. Thus, these areas are suitable for placement of mini-screws and harvesting grafts [5,6]. However, some variations may exist in this respect among different populations, which call for population-specific studies in this respect.

The success of surgical procedures of the mandible depends on thorough preoperative assessment and measurements in critical areas. Fixation of mandibular fractures with mini-implants and mono-cortical screws is among these procedures, and cone-beam computed tomography (CBCT) is the most helpful in this respect [1,7]. The density and thickness of cortical bone are important factors for the stability of mini-implants. Also, the success rate is higher in the posterior regions of the alveolar bone [6,8]. In the past, the success of orthodontic anchorage system highly depended on patient cooperation and compliance; however, in new systems, mini-screws are used, which is an advantage compared to the conventional techniques and is suitable for patients with poor cooperation. Mini-implants have advantages such as small size, easy placement and retrieval, insignificant postoperative complications and quick attachment to bone [9].

Common areas for mini-implant placement include the palatal segment of the maxillary alveolar bone, the retromolar region of the mandible, the buccal cortical bone of the maxilla and the buccal cortical plate of the mandible [10]. The quality and quantity of cortical bone, soft tissue inflammation around mini-implants, the inter-radicular space, the screw design and the path of insertion of mini-implants are among the factors affecting the success of orthodontic treatment. The thickness of cortical plate is the most important factor determining the success rate of treatment [9]. Placement of mini-implants with a larger angle and greater contact with cortical bone increases the success rate in achieving implant stability [7]. Screw loosening and failure of mini-implants are among their major shortcomings [6]. Evidence shows that the failure rate of mini-implants is 11 to 30% [3]. The most important

risk factor for their failure is the diameter of the mandibular cortical plate less than 1mm in the superior region. The primary stability of mini-implants depends on the adequate thickness of cortical bone. In most cases, this thickness in the mandible is greater than that in the maxilla, which shows superiority of the mandible for placement of mini-implants [6]. Accurate measurement of thickness and density of cortical bone prior to surgery and orthodontic treatment enables selection of appropriate size mini-implants for the region [7].

In general, bone grafts are used for regeneration of craniofacial skeletal defects and placement of dental implants. In dental implant placement, adequate thickness of bone is required for osseointegration and achieving adequate implant stability [11]. Autogenous grafts are among the most commonly used grafts to increase the alveolar ridge height [1]. For autogenous graft harvesting from the buccal bone in the posterior mandible, it is recommended to first measure the thickness of the region using CBCT [11]. CBCT is a three-dimensional imaging modality that allows accurate measurements in the coronal, sagittal and axial planes, which are not possible by use of two-dimensional imaging modalities [3,12]. It has been confirmed that CBCT allows accurate measurements on high-resolution scans due to sub-millimeter voxels [5]. Due to the presence of small isotropic voxels measuring 0.07-0.25mm, CBCT enables detailed measurements in the maxillofacial region [12].

CBCT has advantages for head and neck imaging such as lower cost and lower patient radiation dose compared to computed tomography scan, which adds to its popularity. Also, there are several software programs for CBCT with a wide range of applications such as detection of impacted teeth in orthodontics, assessment of the quality of newly formed bone, evaluation of response to orthognathic surgery, determination of growth pattern, 3D analysis of facial deformities, soft tissue, airways and root resorption and cephalometric analysis [12]. CBCT is also useful for preoperative assessments prior to fixation surgeries and graft harvesting in areas close to the inferior alveolar nerve or other anatomical landmarks. It also enables accurate assessment of the position of tooth roots [1]. Adequate information is not available regarding the thickness of buccal cortical plate of the mandible and the distance between its external border and the tooth roots and the inferior alveolar canal in the Iranian population. Thus, this study aimed to measure the thickness of buccal cortical bone of the mandible to assess its distance

from the tooth roots and the inferior alveolar canal and to evaluate its density in dentate adults using CBCT.

Materials and Methods

This study was conducted on CBCT scans of adult patients presenting to a private oral and maxillofacial radiology clinic from 2014 to 2016. The CBCT scans had been requested for preoperative assessments before third molar extraction surgery or implant placement. The inclusion criteria were high-quality images with complete set of teeth in the respective quadrant. The exclusion criteria were diseases and problems that could affect the thickness of the buccal plate of the mandible such as mandibular fracture, cysts and tumors, bone diseases and developmental anomalies. Teeth with root resorption, rotation and buccal and lingual tilts were also excluded. A total of 80 CBCT scans were evaluated. All images had been obtained using NewTom Giano CBCT system (Verona, Italy).

All images were high-resolution and had been taken with 11 x 8cm field of view. All measurements were made using the digital ruler of NNT viewer software with 0.1mm accuracy. The following measurements were made: thickness of buccal cortical bone at the mid-root of canine tooth (mid-root was determined as the mid-point of the anatomic root from the cemento-enamel junction to the apex), thickness of buccal cortical and trabecular bone at the mid-root of canine tooth, thickness of buccal cortical bone at the apex of canine tooth, thickness of buccal cortical and trabecular bone at the apex of canine tooth, thickness of buccal cortical bone at the mid-root of second premolar, thickness of buccal cortical and trabecular bone at the mid-root of second premolar, thickness of buccal cortical bone at the apex of second premolar, thickness of buccal and cortical bone at the apex of second premolar, thickness of buccal cortical bone at the mid-root of second molar, thickness of buccal cortical and trabecular bone at the mid-root of second molar, thickness of buccal cortical bone at the apex of second molar, thickness of buccal cortical and trabecular bone at the apex of second molar, thickness of buccal cortical bone at the central cross-section of inferior alveolar canal in the second molar area, thickness of buccal cortical and trabecular bone at the central cross-section of inferior alveolar canal in the second molar area, bone density of the cortical bone at the site of second molar tooth (Figure 1).

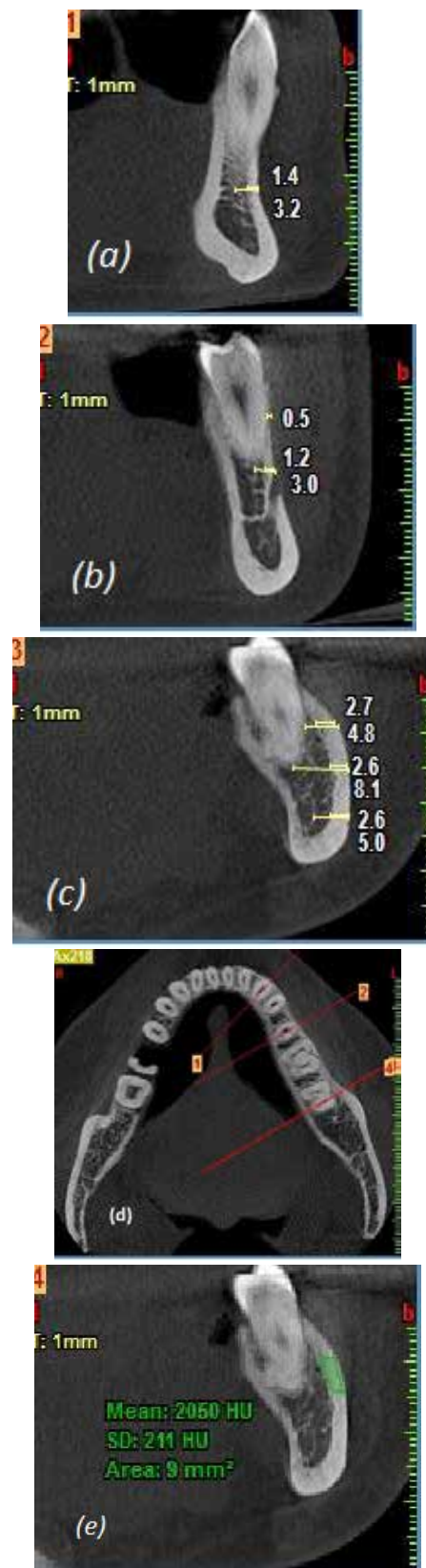


Figure 1. Illustrates the measurements of buccal cortical bone thickness and buccal cortical and trabecular bone thickness in different sites of Canine (a), second premolar (b) and second molar (c). (d) shows the axial view of measurements. (e) shows the mean bone density of the cortical bone at the site of second molar.

A total of 80 CBCT scans of the mandible were evaluated such that in each mandibular quadrant, the thickness of buccal cortical plate and the sum of cortical and trabecular bone thickness were measured at the mid-root and apex of the canine, second premolar and second molar and the location of inferior alveolar canal. Thus, 15 pieces of information per each individual were collected and recorded in datasheets along with their age and sex. All analyses were performed by an oral and maxillofacial radiologist and a general dentist. In case of disagreement, measurements were repeated and the mean value was used for statistical analysis. Data were analyzed by using linear regression.

Results

Table 1 shows the obtained values in males and females. The mean thickness of buccal cortical plate in the mid-root of canine tooth was 0.019 ± 0.056 mm in females and 0.27 ± 0.465 mm in males. Age ($P=0.530$) and right/left quadrant ($P=0.651$) had no significant effect on this thickness but the effect of gender was significant ($P=0.002$). The sum of thickness of buccal cortical and trabecular bone at the mid-root of canine tooth was 0.019 ± 0.056 mm in females and 0.270 ± 0.465 mm in males. Age ($P=0.530$) and right/left quadrant ($P=0.651$) had no significant effect on this thickness but the effect of gender was significant ($P=0.002$).

The mean thickness of buccal cortical plate at the apex of canine tooth was 1.49 ± 0.625 mm in females and 1.94 ± 0.438 mm in males. The effect of age ($P=0.015$) and gender ($P<0.0001$) on this thickness was significant but right/left quadrants had no significant difference ($P=0.311$). By an increase in age of patients, this thickness decreased. The sum of thickness of buccal cortical and trabecular bone at the apex of canine tooth was 3.01 ± 1.399 mm in females and 4.25 ± 1.459 mm in males. The effect of age ($P=0.004$) and gender ($P<0.0004$) on this thickness was significant but right/left quadrants had no significant difference ($P=0.478$). By an increase in age of patients, this thickness decreased. The mean thickness of buccal cortical plate at the mid-root of second premolar tooth was 0.460 ± 0.628 in females and 1.05 ± 0.718 mm in males. Age ($P=0.274$) and right/left quadrant ($P=0.632$) had no significant effect on this thickness but the effect of gender was significant ($P<0.0001$). The sum of thickness of buccal cortical and trabecular bone in the mid-root of second premolar tooth was 0.600 ± 0.936 mm in females and 1.14 ± 0.869 mm in males. Age ($P=0.306$) and right/left quadrant ($P=0.781$) had no significant effect on this thickness but the effect of gender was significant

($P=0.010$). The mean thickness of buccal cortical plate at the apex of second premolar tooth was 1.66 ± 0.716 mm in females and 2.15 ± 0.563 mm in males. The effect of age ($P<0.0001$) and gender ($P<0.0001$) on this thickness was significant and the thickness decreased by an increase in age but right/left quadrants had no significant difference ($P=0.536$). The sum of thickness of buccal cortical and trabecular bone at the apex of second premolar tooth was 2.980 ± 1.308 mm in females and 4.05 ± 1.267 mm in males. The effect of age ($P=0.050$) and right/left quadrants ($P=0.983$) was not significant. But the effect of gender was significant ($P<0.0001$). The mean thickness of buccal cortical plate in the mid-root of second molar tooth was 2.64 ± 1.027 mm in females and 2.50 ± 0.939 mm in males. The effect of age ($P<0.0001$), right/left quadrant ($P=0.459$) and gender ($P=0.408$) was significant on this thickness and by an increase in age, this thickness decreased. The sum of thickness of buccal cortical and trabecular bone in the mid-root of second molar tooth was 4.53 ± 2.461 mm in females and 3.28 ± 2.226 mm in males. The effect of age ($P<0.0001$) and gender ($P=0.006$) was significant on this thickness but the right and left quadrants were not significantly different ($P=0.580$). The mean thickness of buccal cortical plate at the apex of second molar tooth was 2.77 ± 0.478 mm in females and 3.28 ± 0.799 mm in males. The effect of age ($P=0.262$) and right/left quadrant ($P=0.722$) was not significant but gender had a significant effect on this thickness ($P=0.001$).

The sum of thickness of buccal cortical and trabecular bone at the apex of second molar tooth was 7.20 ± 2.378 mm in females and 7.56 ± 2.301 mm in males. The effect of age ($P=0.535$) and right/left quadrants ($P=0.303$) was not significant. But the effect of age was significant ($P<0.0001$) and by an increase in age, the thickness decreased. The buccal cortical plate thickness at the site of second molar in the inferior alveolar canal region was 2.38 ± 0.457 mm in females and 2.60 ± 0.519 mm in males. The effect of gender ($P=0.055$), right/left quadrant ($P=0.201$) and age ($P=0.117$) was not significant. The sum of cortical and trabecular bone at the site of second molar in the inferior alveolar canal region was 4.79 ± 1.148 mm in females and 5.35 ± 1.483 mm in males. The effect of gender ($P=0.084$), right/left quadrant ($P=0.221$) and age ($P=0.407$) was not significant. The mean density of cortical bone in the second molar site of the mandible was 1367.89 ± 172.448 HU in females and 1339.18 ± 191.882 HU in males. The effect of gender ($P=0.512$), right/left quadrant of patient ($P=0.665$) and age ($P=0.779$) on bone density was not significant.

Measured areas		Gender		
		Male	Female	
Canine	Mid-root	CB	0.277±0.456	0.019±0.056
		CB+TB	0.277±0.456	0.019±0.056
	Apex	CB	1.944±0.438	1.49±0.625
		CB+TB	4.25±1.459	3.01±1.399
Second Premolar	Mid-root	CB	1.05±0.718	0.460±0.625
		CB+TB	1.05±0.718	0.600±0.936
	Apex	CB	2.15±0.563	1.66±0.716
		CB+TB	4.05±1.267	2.98±1.3
Second Molar	Mid-root	CB	2.50±0.939	2.64±1.027
		CB+TB	4.53±2.461	3.28±2.226
	Apex	CB	3.28±0.799	2.77±0.478
		CB+TB	7.56±2.301	7.20±2.378
	IANC Region	CB	2.60±0.519	2.38±0.457
		CB+TB	5.35±1.483	4.79±1.148

CB: Buccal cortical bone thickness.

CB+TB: Buccal cortical and trabecular bone thickness.

Table 1. Measurements of buccal bone thickness in females (n=37) and males (n=43).

Discussion

The thickness of buccal cortical plate of the mandible is the distance between the outermost layer of cortex and the surface of the roots and the inferior alveolar canal [1]. This thickness is important for placement of mini-implants in orthodontic treatment and implant therapy [3]. Placement of mini-implants for fixation of mandibular fractures may compromise the roots or the inferior alveolar canal. To prevent traumatization of the inferior alveolar canal, the thickness of buccal cortical plate must be measured using CBCT prior to placement of mini-implants to ensure their stability and safety of anatomical structures [1]. In the past two decades, fixation by mini-implants has been the treatment of choice for mandibular fractures. Mini-implants are fabricated with different lengths but they all have 1mm diameter. Thus, information about the thickness of cortical bone and the distance between the external border and the tooth roots and the inferior alveolar canal is necessary prior to treatment planning for fixation of mandibular fractures or bone harvesting [1]. It should be noted that access to 3D imaging modalities such as CBCT is not always feasible. Thus, having an estimated mean value for this thickness in different populations can be helpful for clinicians. In this study, two observers measured the thickness of buccal cortical plate in the canine, second premolar

and second molar sites to find areas with adequate buccal bone thickness for placement of mini-implants and graft harvesting. The results showed that the thickness of buccal cortical plate increased from the canine towards the second molar site. This increase in thickness can provide higher stability for mini-implants. These findings were in agreement with those of Ono et al [8]. Both studies showed higher thickness of buccal cortical plate in the posterior mandible. As mentioned earlier, the minimum thickness of cortical bone required for mini-implant placement is 1mm. Our results were also in agreement with those of Talaat et al, [1] since both studies showed that the second molar site was the most suitable location for placement of mini-implants. The only difference between the two studies was in the method and site of measurement relative to the alveolar crest. Talaat et al. [1] made measurements at 4mm distance from the alveolar crest while in our study, the anatomic mid-root and apex of teeth were used for measurements due to the variable level of crestal bone loss in different individuals. The points used in our study have higher reproducibility. Our findings were also in line with those of Borges and Mucha [13] since they stated that the posterior mandible was the best location for placement of mini-implants; however, they measured the bone density while we measured both density and thickness of buccal cortical bone. Despite different software programs used for measurement of

bone density of the posterior mandible in the two studies, similar results were obtained in the range of 782 to 1610HU. Timock et al. [12] measured the height and thickness of buccal cortical plate of the mandible on dry skulls by direct measurement and measurement on CBCT scans and found no significant difference between the two measurement methods, which highlights the optimal accuracy of CBCT for such measurements. Natalie et al. [4] performed a similar study to assess the position of inferior alveolar canal and reported results similar to Timock et al [12]. Considering the confirmed accuracy of CBCT for such measurements, we performed measurements on CBCT scans in our study. Holmes et al, [5] also showed the highest thickness of buccal cortical plate of the mandible to be between the second premolar and first molar teeth. The difference between their study and ours was in the location of measurements since they measured the inter-radicular distances and thickness to find an ideal place for placement of mini-implants without traumatizing the roots or other anatomical structures while we measured the distance between the bone cortex and root surface and inferior alveolar canal to find areas with adequate thickness of cortical bone for suitable osseointegration of mini-implants and graft harvesting.

Both studies, however, showed that this thickness was greater in the posterior mandible. Zhang et al. [11] reported similar results regarding the thickness of buccal cortical plate of the mandible and its association with gender. Both studies showed that this thickness was greater in males than females in dentate areas; however, they found that age had no effect on buccal cortical plate thickness while in our study, the thickness of buccal cortical plate decreased with aging, which can be due to bone resorption in the region. Farnsworth et al. [6] found that this thickness had no association with gender, which is different from our findings; this difference can be due to evaluation of different age groups. They compared adolescents and adults in this respect and showed greater thickness in adults.

The results reported by Baumgaertel and Hans [10] were in line with those of Lim et al [2]. Both studies measured the buccal cortical plate thickness at 4mm from the mandibular alveolar crest and reported the highest buccal cortical plate thickness of the mandible at 4mm distance; this thickness increased towards the posterior mandible, which is in accordance with our results. Zhao et al. [9] and Lim et al. [2] found similar results and mentioned that the buccal cortical plate thickness in the mandible is greater than that in the

maxilla. The same finding was reported by Deguchi et al [7]. In our study, only the mandible was evaluated because most previous studies comparing the thickness of buccal cortical plate of the maxilla and mandible had reported greater thickness in the mandible. The results of Zhao et al, [9] regarding the buccal cortical plate thickness of the mandible were in agreement with ours and they also reported the greatest thickness in the mandibular second molar region, suitable for mini-implant placement. Park and Cho [3] reported similar results as well.

Ono et al. [8] evaluated the association of thickness of cortical plate and gender. Their results regarding gender were in line with ours; however, they used computed tomography scan for the measurements while we used CBCT. It should be noted that inadequate expertise in making measurements on CBCT scans may affect the results and this topic is in need of further investigation. Further studies with a larger sample size are required to compare the thickness of buccal cortical plate in the right and left quadrants of the jaw.

Conclusion

The results showed that the buccal cortical thickness of the mandible increased towards the posterior region and the mandibular second molar site had the most ideal thickness and density for placement of orthodontic mini-implants or autogenous graft harvesting.

Conflict of Interest

There is no conflict of interest to declare.

References

- [1] Talaat WM, Al Bayatti SW, Dohair DE, Zobeidi MA, Hannounh KM. A CBCT measurement of the mandibular buccal bone thickness in dentate adults. *Oral Surg.* 2015; 8(1):38-41.
- [2] Lim JE, Lee SJ, Kim YJ, Lim WH, Chun YS. Comparison of cortical bone thickness and root proximity at maxillary and mandibular interradicular sites for orthodontic mini-implant placement. *Orthod Craniofac Res.* 2009; 12(4):299-304.
- [3] Park J, Cho HJ. Three-dimensional evaluation of interradicular spaces and cortical bone thickness for the placement and initial stability of micro-implants in adults. *Am J Orthod Dentofacial Or-*

thop. 2009; 136(3):314-e1.

- [4] Massey ND, Galil KA, Wilson TD. Determining position of the inferior alveolar nerve via anatomical dissection and micro-computed tomography in preparation for dental implants. *J Can Dent Assoc.* 2013; 79(d39):1-7.
- [5] Holmes PB, Wolf BJ, Zhou J. A CBCT atlas of buccal cortical bone thickness in interradicular spaces. *Angle Orthod.* 2015; 85(6):911-9.
- [6] Farnsworth D, Rossouw PE, Ceen RF, Buschang PH. Cortical bone thickness at common miniscrew implant placement sites. *Am J Orthod Dentofacial Orthop.* 2011; 139(4):495-503.
- [7] Deguchi T, Nasu M, Murakami K, Yabuuchi T, Kamioka H, Takano-Yamamoto T. Quantitative evaluation of cortical bone thickness with computed tomographic scanning for orthodontic implants. *Am J Orthod Dentofacial Orthop.* 2006 Jun 1; 129(6):721-e7.
- [8] Ono A, Motoyoshi M, Shimizu N. Cortical bone thickness in the buccal posterior region for orthodontic mini-implants. *Int J Oral Maxillofacial Surg.* 2008; 37(4):334-40.
- [9] Zhao H, Gu XM, Liu HC, Wang ZW, Xun CL. Measurement of cortical bone thickness in adults by cone-beam computerized tomography for orthodontic miniscrews placement. *J Huazhong Univ Sci Technol.* 2013; 33(2):303-8.
- [10] Baumgaertel S, Hans MG. Buccal cortical bone thickness for mini-implant placement. *Am J Orthod Dentofacial Orthop.* 2009; 136(2):230-5.
- [11] Zhang W, Tullis J, Weltman R. Cone Beam Computerized Tomography Measurement of Alveolar Ridge at Posterior Mandible for Implant Graft Estimation. *J Oral Implantol.* 2015; 41(6):e231-7.
- [12] Timock AM, Cook V, McDonald T, Leo MC, Crowe J, Benninger BL, Covell Jr DA. Accuracy and reliability of buccal bone height and thickness measurements from cone-beam computed tomography imaging. *Am J Orthod Dentofacial Orthop.* 2011; 140(5):734-44.
- [13] Borges MS, Mucha JN. Bone density assessment for mini-implants positioning. *Dental Press J Or-*

Please cite this paper as:

Ghoncheh Z, Moghaddamzadeh B, Kaviani H, Jamali G, Feizi M; Measurement of buccal cortical plate thickness in the mandible of dentate adults in an Iranian population using cone-beam computed tomography. *J Craniomax Res* 2019; 6(2): 66-72