



Exploring the Advancements of Forensic Odontology: A Review

Amirmohammad Moradpour¹, Samareh Mortazavi², Iman Shiezhadeh^{1*}

1. Student Research Committee, Faculty of Dentistry, Mashhad University of Medical Sciences, Mashhad, Iran.

2. Department of Oral and Maxillofacial Radiology, School of Dentistry, Mashhad University of Medical Sciences, Mashhad, Iran.

ARTICLE INFO

Article Type:
Review Article

Received: 12 September 2025

Revised: 12 October 2025

Accepted: 19 November 2025

*Corresponding author:

Iman Shiezhadeh

Student Research Committee, Faculty of Dentistry,
Mashhad University of Medical Sciences, Mashhad,
Iran.

Tel: +98-903-5843399

Fax: +98-21-84903747

Email: shiezhadehimn@gmail.com

ABSTRACT

Introduction: Forensic dentistry is essential for human identification, but traditional manual techniques are often time-intensive and prone to subjectivity. The integration of artificial intelligence (AI) presents a transformative opportunity to enhance accuracy and efficiency across various forensic odontology applications. This systematic review consolidates and analyzes the existing literature on AI applications in forensic dentistry.

Materials and Methods: A comprehensive literature search was conducted in the PubMed and Scopus databases following the PRISMA (Preferred Reporting Items for Systematic Reviews and Meta-Analyses) guidelines. Studies published up to August 2025 were considered for inclusion.

Results: A total of 116 studies were analyzed. The primary applications included age estimation (54 studies), gender estimation (33 studies), and human/dental identification (26 studies). Bite mark analysis (1 study) and facial reconstruction (2 studies) were identified as underexplored areas. Convolutional neural networks (CNNs) were the most frequently employed AI algorithm, utilized in 64% (74/116) of studies, while orthopantomograms (OPGs) were the predominant imaging modality in 72% (84/116) of investigations. Quantitative results demonstrated significant promise: age estimation models achieved a mean absolute error (MAE) as low as 0.0079 years and a peak classification accuracy of 99.98%; gender estimation models attained accuracies between 68% and 98%; and human identification models reached up to 100% accuracy in optimal conditions, though sensitivity dropped to 69% in complex postmortem cases. Emerging techniques, such as microbiome analysis and generative adversarial networks (GANs), were noted as innovative future directions.

Conclusion: AI demonstrates significant potential to improve accuracy and reduce processing time in core forensic dentistry tasks, particularly age and gender estimation. However, challenges related to data privacy, algorithmic bias, and legal admissibility persist. Future research should prioritize the development of explainable AI models, standardized and diverse datasets, and robust regulatory frameworks to ensure ethical and trustworthy integration into forensic practice.

Keywords: Artificial intelligence; Dental identification; Forensic dentistry; Forensic odontology.

Please cite this Article as:

Moradpour A, Mortazavi S, Shiezhadeh I. Exploring the Advancements of Forensic Odontology: A Review. J Craniofac Res 2026; 13(1): 1-38. DOI: [10.18502/jcr.v13i1.21473](https://doi.org/10.18502/jcr.v13i1.21473)



Copyright © 2026 Tehran University of Medical Sciences.

This work is licensed under a Creative Commons Attribution-NonCommercial 4.0 International license (<https://creativecommons.org/licenses/by-nc/4.0/>). Non-commercial uses of the work are permitted, provided the original work is properly cited.

Introduction

Forensic is derived from the Latin term “forensic” (before forum), which provides a place for legal disputes. Forensic dentistry (forensic odontology) is essential in the criminal legal system and investigative contexts for human identification, bite mark analysis, disaster victim identification, age estimation, and the analysis of dental evidence in medico-legal cases [1-3]. From conventional manual comparisons of dental records, radiographs, and bite marks, forensic dental identification has developed to incorporate technology-assisted approaches [4]. Among the technological improvements that alter this field of science, artificial intelligence (AI) has been a game-changer in forensic applications since it allows fast processing of dental records, image analysis, and pattern identification in forensic scenarios [5]. Various AI-based algorithms, such as machine learning (ML), deep learning (DL), and computer vision have shown a great deal of applicability in the automation of dental profiling, bite mark analysis, dental age estimation, and craniofacial reconstruction [6]. The growing accessibility of dental datasets, advances in image recognition, and the creation of neural networks that increase the precision of radiograph and dental record analysis are the main drivers of AI integration in forensic odontology [7]. AI models significantly improve dental comparisons in both postmortem and antemortem analyses used to identify victims in major disasters and criminal investigations [2,8]. The objective of this systematic review is to explore the integration of AI in forensic dentistry, specifically how it can be used to identify people, estimate their ages, analyze forensic bite marks, and recreate the face and skull. The review also addresses challenges and ethical considerations, and it shows how AI-driven investigative odontology could evolve in the future.

Materials and Methods

An extensive search of the literature was conducted using the most common databases, including PubMed and Scopus, to identify studies that investigated the application of artificial intelligence (AI) in forensic dentistry. The search terms incorporated a combination of controlled vocabulary and free-text search items. Table 1 shows the searching strategy for each database (Table 1). Based on the primary literature review, the search strategy focused on four important applications: age and gender estimation, human and dental identification, bite mark analysis, and face reconstruction [6,8-10]. According to the defined inclusion criteria,

all English articles published from 2000 to 2025 (1st of August 2025) that evaluated AI applications in forensic dentistry/odontology for dental image analysis and automated predictive dental and human identification were included in the study. The selection process was conducted independently by two researchers (A.M. and I.S.) and consolidated under the supervision of S.M. To ensure completeness, additional relevant articles were manually added from other sources, including the references of selected papers and supplementary databases such as arXiv. Figure 1 (PRISMA flowchart) provides a detailed overview of this process.

Results and Discussion

As shown in Figure 1, a total of 116 articles were included in the study. These articles were classified into four categories according to the search strategy: age estimation (54 articles) and gender estimation (33 articles), human and dental identification (26 articles), bite mark analysis (1 article), and face reconstruction (2 articles). In the following, each application is described in detail.

Age & Gender Estimation

Age estimation

Age estimation is crucial in forensics and medicine for identification, legal matters, immigration, and diagnostics. Current approaches, which depend on visual examination of skeletal structures, dentition, and biochemical markers, are time-consuming, biased, and population-dependent. AI and ML have transformed age estimation, enhancing accuracy, speed, and consistency. AI models analyze medical images, dental records, genetics, and facial features by employing deep learning and regression to extract age-related features [11,12].

In forensic investigations and pediatric medicine, dental age estimation is commonly applied, where the information of tooth eruption patterns, root formation, and mineralization is used to estimate age. Conventional physical age estimation needs cephalometric and panoramic radiographs to assess, which must be performed by a forensic expert. Machine learning-based artificial intelligence has come a long way in automating tooth segmentation, mineralization analysis, and interpreting the eruption sequence [1,13]. Recent studies commonly used radiographic imaging modalities as the database with sample sizes ranging from 99 individuals [14] to 27,957 individuals [15] (Table 2). Panoramic radiographs or OPGs were used in

approximately 93% of studies (50 out of 54), followed by cone-beam computed tomography (CBCT) in about 4% (2 out of 54), with the remaining studies utilizing other modalities such as bitewing or periapical radiographs. Studies were conducted in diverse demographic populations, including Brazilian, Chinese, Indian, Malaysian, and archaeological specimens. Results revealed that convolutional neural network (CNN) based models were implemented in 70% of studies (38 out of 54). In contrast, traditional ML approaches such as support vector machine (SVM), random forest (RF), and k-nearest neighbors (KNN) were used in 22% (12 out of 54), and other neural networks (like artificial neural network (ANN), multi-layer perceptron (MLP)) were applied in approximately 19% (10 out of 54). Several studies utilized hybrid models and compared their accuracy.

Key evaluation metrics included mean absolute error (MAE) in years for age prediction, accuracy percentages for classification or staging, and root mean square error (RMSE), R^2 coefficients, and area under the curve (AUC) for steady improvements in automated forensic odontology tools. Studies showed a wide range of results in prior parameters, like MAE, which ranged from 0.0079 years [16] (using 2D-DCNN with Modified Genetic-Random Forest) to 7.07 years [17] (using DenseNet169 for age regression). Also, classification accuracy reached as high as 99.98% [18] (for one-year age intervals using hybrid CNN-KNN) and as low as 42.8% [19] (for five-class classification using SVM) in study results (Table 2). Clinical and forensic implications emphasize AI's potential in helping forensics to evaluate age faster and more reliable. This demonstrates the time-reducing advantage—as low as 2.72 seconds [20]—of AI in legal age verification and victim identification in situations like mass disasters.

Gender estimation

On the other hand, identifying gender is essential in mass disasters, accidental deaths, and forensic investigations. Jawbones and teeth, especially canines, are highly resistant to wear and decay, making them invaluable for post-mortem identification. Gender estimation using AI as applied to forensic dentistry was featured prominently for its capacity to improve accuracy and reduce human error in forensic cases. Traditionally, forensic experts estimated gender using dentition and craniofacial features such as canine dimorphism, mandibular measurement, and tooth morphology (Figure 2). However, manual approaches are time-consuming and subjective, which results in

non-uniformity in forensic micro-examinations. Specifically, in automated gender classification based on dental imaging in combination with biometric analysis, the precision of the used algorithms can be considerably increased by various AI-driven models, particularly when they are based on deep learning [12,21]. In gender estimation, OPGs were predominantly used in 64% of studies (21 out of 33), followed by CBCT in 12% (4 out of 33), lateral cephalometric radiographs in 6% (2 out of 33), and other modalities such as extracted teeth, facial computed tomography (CT), 3D scans or bitewing images in the remaining 21% (7 out of 33) (one study used CBCT and OPG). Study populations demonstrated demographic diversity, including China, Iran, Turkey, and Brazil (Table 3).

Similar to age estimation, CNNs and their variants (like DenseNet, ResNet, VGG, and EfficientNet) were the dominant approaches that were applied in 61% of studies (20 out of 33), followed by traditional machine learning models such as RF, SVM, KNN, and naive Bayes (NB) in 45% (15 out of 33). Some studies combined multiple algorithms to compare performance across different methods. Unlike age estimation, key evaluation metrics in gender estimation emphasized sensitivity, specificity, precision, recall, and F1 scores, while AUC was the only common metric (Table 3). Reported accuracy ranged from 68% [22] (using DenseNet121 on mandibular canines) to 98% [23] (using RF and gradient boosting on CBCT/OPG for gonial angle analysis). Also, AUC ranged from 0.58 [22] to 0.994 [23], while F1 scores ranged from 0.733 [24] (using KNN on mandibular images) to 0.979 [23]. Clinical and forensic outcomes highlight AI's effectiveness in gender estimation. These algorithms could speed up the process to 142 images per second [25]. Also, a systematic review and meta-analysis by Dashti et al. showed 88.66% pooled accuracy of AI algorithms to determine gender using OPGs. In these 13 studies, the best-performing model showed 99.20% accuracy [6]. Still, extensively designed clinical trials and high-quality systematic reviews are essential to validate the accuracy of various models in forensic dentistry [10,13,26].

Human and Dental Identification

AI enhances forensic odontology by automating the comparison of dental X-rays or 3D models, bite marks, and occlusal patterns, providing precise matches even when DNA or fingerprints are unusable due to decomposition or damage. Unlike the subjective and time-consuming manual methods, AI-driven image recognition and deep learning enhance the accuracy

of dental identifications [1,27,28]. Dental identification is a crucial aspect of forensic science because the size, shape, and grooves of teeth are unique enough to allow matching. It is particularly useful in mass disasters or decomposed remains because teeth are resistant to destruction, and dental records are typically available. It helps forensic experts to solve crimes and match missing persons [27,29]. Study sample sizes varied widely from 10 teeth [30] to 43,467 OPGs [31]. Also, Imaging modalities were diverse. OPGs (PRs/DPRs) were the most common, which were used in 50% of studies (13 out of 26). CBCT followed with 12% (3 out of 26), periapical or bitewing radiographs in 15% (4 out of 26), and intraoral scans or 3D models in 23% (6 out of 26). Some studies used mixed modalities to enhance evaluation (Table 4).

Performance metrics varied and included accuracy percentages, rank-based retrieval scores (like Rank-1, Rank-5), AUC, precision, recall, F1 scores, and intersection over union (IoU). CNNs and their variants (VGG16, ResNet, Inception, DenseNet, AlexNet) were utilized in 58% of studies (15 out of 26), and they were especially common in the studies that were published after 2017 (15 out of 23). Also, traditional ML models such as SVM, LDA, KNN, and ANN appeared in 23% (6 out of 26), and feature-based methods (like SURE, RANSAC, and SIFT) were used in 19% (5 out of 26). Some studies applied hybrid or custom networks (Table 4).

Accuracy outcomes covered a wide range. Rank-1 accuracy reached as high as 99.69% [32] (using PointResNet on 3D tooth models without missing teeth). Overall classification accuracy peaked at 100% [33] (using VGG16 on orthopantomography pairs) and fell to 69% sensitivity in postmortem scenarios [34] (using LDA on ovine rugae scans). AUC values ranged from 0.971 [35] (using GoogLeNet) to 0.996 [36] (using DENT-net) for human baselines. Additionally, the highest F1 score was 0.8720 [37] (using R-CNN). Forensic and clinical results showed that AI can outperform manual methods and reduce processing time to under five minutes [30]. Applications in victim identification during mass disasters were highlighted in most of the studies.

Bite Mark Analysis

Bite marks are generally regarded as an important form of evidence, particularly in cases of sexual assault, rape-homicide, and child abuse. Their ephemerality makes forensic odontological analysis and perpetrator profiling tricky. Historically, bite mark analysis has

been a controversial forensic method due to its subjectivity, risk of examiner bias, and variable results of manual comparison methods. Soft tissue distortion, variable bite depths, and discrepancies in examiners often introduce errors. Advancements in bite mark analysis have come about by using other sciences such as artificial intelligence (AI), which have introduced objectivity, accuracy, and automation to the process (Figure 3) [1,12,38]. Macorano et al. developed a new technique that involved 3D reverse engineering to produce a new analysis of a bite mark found on a portion of food from a crime scene. The pilot study used photogrammetry to generate 3D models in digital space for the bite marks and dental casts from a suspect and a victim. By comparing spatial distance, overlap, and interpenetration, they showed the potential of reverse engineering in forensic investigations, indicating the coincidence of the victim's dentition with the bite mark [39]. Also, researchers combined microbiome analysis with standard DNA profiling to improve the interpretation of bite mark evidence. The combined use of bite mark microbiome analysis and DNA profiling enhances forensic accuracy and reliability [40]. A preliminary study investigated the efficacy of artificial neural networks (ANN) in bite mark detection by examining 34 features imprinted on pink wax, resulting in promising accuracy. Although computer-aided analysis seeks to reduce human bias and improve impartiality, manual analysis continues to be a key component (Table 5) [41]. However, additional study is crucial to enhance feature selection and classification techniques, especially in the context of partial bite mark images.

Face Reconstruction

AI-driven face reconstruction has made marked improvements to forensic dentistry, particularly through the automation of skull-based facial reconstruction and enhanced accuracy and efficiency. In contrast to traditional manual techniques that were time-consuming and subjective, AI, machine learning, and deep learning have facilitated facial reconstruction, craniofacial superimposition, and forensic age progression. Deep neural networks, convolutional neural networks, and generative adversarial networks are key AI models that analyze skull morphology, tissue thickness, and facial symmetry to produce high-resolution reconstructions [9,29,42]. This review search identified only two studies that met the inclusion criteria, with sample sizes of 62 skulls and 82 heads [43], and 500 segmented skulls with around 30,000 celebrity face images [44]. Imaging modalities include volumetric CT head scans [43], and optical 3D surface scans and digital datasets [44], and

there was no overlap in modality types. Both studies focused on forensic applications, specifically skull-to-face mapping for identification. Also, the algorithmic approaches were different. Gietzen & Brylka (2019) applied Principal Component Analysis (PCA) and Iterative Closest Point (ICP) for statistical shape modeling [43]. In contrast, Mohammed et al. (2024) used convolutional neural networks (CNNs), Scale-Invariant Feature Transform (SIFT), and Generative Adversarial Networks (GANs) for deep learning-based skull-to-face synthesis [44].

Gietzen & Brylka reported precise skull registration errors below 0.5 mm, head fitting errors of 0.19 mm, and RMSE for head fittings between 1.32 and 4.04 mm [43]. Mohammed et al. showed feasibility on public datasets but did not provide quantitative real-world metrics due to the lack of paired skull-face data [44]. In conclusion, both studies highlight the forensic potential of AI-driven facial reconstruction. Furthermore, AI and facial reconstruction have shown promise in recognizing unknown individuals, planning disaster treatment, and estimating age. However, further research and optimized AI models are needed to maximize the efficacy of these emerging technologies [9,45].

Ethical Considerations and Challenges

The growing use of AI models in forensic dentistry raises serious ethical and legal concerns related to data privacy, bias, transparency, admissibility, and workforce implications. AI promises greater efficiency and objectivity but also invites worry over how evidence driven by AI could be deployed or misapplied [1,46]. Data privacy and security are top priorities of public concern. Sensitive dental datasets serve as training data for AI systems, making encryption, anonymization, and secure storage key mechanisms to protect against identity theft and unauthorized access. Adhering to regulations such as the General Data Protection Regulation (GDPR) and the Health Insurance Portability and Accountability Act (HIPAA) is imperative in preserving ethical integrity. Another big challenge is algorithmic bias. AI models trained on unbalanced datasets could result in more members of certain ethnic groups being misidentified than others and hence require more diverse training examples to combat bias and improve reliability [47,48]. The “black-box” nature of many AI models, which makes it difficult to understand how conclusions are reached, raises questions of transparency and admissibility. To satisfy the demand for accountability and legal credibility, authors

suggest explainable AI (XAI) frameworks. There is also the risk of over-relying on AI-generated results, otherwise known as automation bias. AI must always be supervised by a human who is responsible for ensuring the rightful identification [49-51]. However, the use of deepfake technology to generate AI-generated faces with matching bones and teeth raises further questions about the evidence-based on facial reconstruction and dental superimposition, which highlights the need for strict regulation on the use of synthetic identities [48]. With AI automation, there are also fears of workforce displacement in forensic odontology. Training programs will need to evolve to include AI while keeping the human element front and center. One of the major problems is the lack of regulatory frameworks designed for AI-generated forensic evidence. International AI policies must be established to preserve data integrity, reproducibility, and legal standardization. Since the risk of breaching different data privacy laws is present in such investigations, ethical complexity comes into play, and standardizing ethical guidelines such that data domination and cross-border compliance can occur is required for cross-border investigations of AI applications [1,48]. Last but not least, the trust of the public should be preserved. The two areas that would be a worry to forensic practitioners are transparency and accountability, and the ethical behavior of AI technologies [1,52].

Future Directions and Research Priorities

Integration of AI, three-dimensional imaging, and biometric technologies is transforming forensic dentistry. Future research should focus on: (1) improving the identification of tooth patterns with deep learning models; (2) automating age estimation using radiographic and CBCT data, with validation across different ethnic groups and marker assessments; and (3) advancing three-dimensional facial reconstruction through AI while maintaining high forensic accuracy. Building large and standardized databases for dental records and bite mark analysis is also essential, as these can improve standardization, admissibility, and accuracy in gender and age estimation. Legal acceptance will depend on greater interpretability and transparency in AI decision-making. Developing multi-data fusion models that combine dental, skeletal, and biometric indicators is another priority, and a multimodal natural language processing approach has been proposed for this purpose. Concluding, real-time victim identification systems powered by AI will have to be developed in collaboration between forensic odontologists, law enforcement, and technology science experts [51,53].

Table 1. Search strategy utilized for the systematic literature review.

Database	Search strategy	Result Number
PubMed	(«Artificial Intelligence»[All Fields] OR «AI»[All Fields] OR «Machine Learning»[All Fields] OR «Deep Learning»[All Fields] OR «Neural Networks»[All Fields] OR «Convolutional Neural Networks»[All Fields] OR «CNN»[All Fields] OR «Computer Vision»[All Fields] OR «Automated Analysis»[All Fields] OR «Support Vector Machines»[All Fields] OR «Random Forest»[All Fields]) AND («Forensic Dentistry»[All Fields] OR «Forensic Odontology»[All Fields] OR «Dental Identification»[All Fields] OR «Forensic Dental»[All Fields] OR «Dental Forensics»[All Fields]) AND («Age Estimation»[All Fields] OR «Gender Determination»[All Fields] OR «Sex Determination»[All Fields] OR «Bite Mark Analysis»[All Fields] OR «Human Identification»[All Fields] OR «Facial Reconstruction»[All Fields] OR «Dental Records»[All Fields] OR «Panoramic Radiography»[All Fields] OR «Dental Imaging»[All Fields])	73
Scopus	(TITLE-ABS-KEY («Artificial Intelligence» OR «AI» OR «Machine Learning» OR «Deep Learning» OR «Neural Networks» OR «Convolutional Neural Networks» OR «CNN» OR «Computer Vision» OR «Automated Analysis» OR «Support Vector Machines» OR «Random Forest»)) AND (TITLE-ABS-KEY («Forensic Dentistry» OR «Forensic Odontology» OR «Dental Identification» OR «Forensic Dental» OR «Dental Forensics»)) AND (TITLE-ABS-KEY («Age Estimation» OR «Gender Determination» OR «Sex Determination» OR «Bite Mark Analysis» OR «Human Identification» OR «Facial Reconstruction» OR «Dental Records» OR «Panoramic Radiography» OR «Dental Imaging»))	119

Table 2. Results of artificial intelligence algorithms and machine learning models applied to dental age estimation. The table presents chronological developments across 54 studies. Study populations ranged from 99 to 27,957 individuals across multiple demographics including Brazilian, Chinese, South Indian, Malaysian, and archaeological specimens, with age ranges typically focusing on pediatric to young adult populations (birth to 25 years).

Author and Date	AI Algorithm	Image Dataset Type	Sample Dataset Size	Accuracy of Model	Clinical Outcome	Reference
De Tobel et al. (2017)	AlexNet (kind of CNN)	Panoramic radiographs	400 panoramic radiographs	Mean accuracy (Rank-1 RR) was 0.51, and mean absolute difference was 0.6, and mean linearly weighted kappa was 0.82	Automated pilot approach for staging third molar development demonstrated comparable performance to human observers	(54)
Farhadian et al. (2019)	neural network model	Cone-beam computed tomographic (CBCT)	300 individuals (142 women and 158 men)	The RMSE of the model was 4.40 years, and the MAE was 4.12 years. The prediction errors of the regression model were higher	Neural networks achieved acceptable age estimation, offering potential for improved accuracy in forensics.	(55)
Merdietio Boedi et al. (2020)	bounding box AlexNet and DenseNet201 (both kind of CNN)	Panoramic radiographs (cropped ROIs)	400 panoramic radiographs	Full tooth segmentation increased accuracy by 7% vs bounding boxes	DenseNet201 is superior to AlexNet with 3% improvement in stage allocation accuracy	(56)

Author and Date	AI Algorithm	Image Dataset Type	Sample Dataset Size	Accuracy of Model	Clinical Outcome	Reference
Banar et al. (2020)	3 step CNN automation	OPGs	400 panoramic radiographs	Third molars were segmented with a 93% Dice score. Developmental stages were classified with 54% accuracy, and 0.69 MAE. The automated workflow averaged 2.72 s, significantly faster than manual staging.	Full automation shows promise in the pilot study compared to manual staging.	(20)
Banjšak et al. (2020)	VGG16, DenseNet201, ResNet50, VGG19 and Xception (CNN)	Panoramic dental X-ray images	4035 orthopantomographic images + 89 orthopantomographic images of an archaeological skull	The results showed a 73% accuracy in the age grouping of pictures	CNNs improve images but struggle with poor forensic quality. This neural network showed image analysis, evolution, and ML applications in forensic dentistry	(57)
Kim et al. (2021)	CNN algorithms (ResNet152)	Panoramic radiographs (maxillary and mandibular first molars)	1586 panoramic pictures from patients	accuracy of the tooth-wise estimation: 89.05-90.27% Area under curve (AUC): 0.94-0.98	Exceptional ability for tooth-wise age estimation across all age groups	(58)
Mohammad et al. (2021)	Deep Convolution Neural Network (DCNN)	OPG	657 panoramic radiographs	DCNN with 10 epochs achieved 92.5% accuracy. MAE was 0.17 (male, underestimated) and 0.22 (female, overestimated) for P1, and 0.02/0.03 (overestimated male and female) for P2.	The classification method outperformed the original method for premolar development staging on radiographs	(59)
Vila-Blanco et al. (2021)	CNN	Orthopantomographies (mandible)	1,195 images	MAE of 1.57 years and maximum R2 of 0.880	The shape model offers quantitative analysis and visualization of mandible changes, beneficial for clinical, surgical, dental, or legal applications.	(60)

Author and Date	AI Algorithm	Image Dataset Type	Sample Dataset Size	Accuracy of Model	Clinical Outcome	Reference
Vila-Blanco et al. (2022)	CNN	Orthopantomographs	1746 OPGs	MAE of 0.97 years	The model enables age and sex analysis per tooth, aiding experts in identifying relevant teeth, cohorts, or developmental issues	(61)
Sharifonnasabi et al. (2022)	Hybrid CNN-KNN with PCA	Panoramic dental radiographs	1,922 OPG of patients aged 15 to 23	Estimated ages for 1-year, 6-month, 3-month, and 1-month cases were determined with accuracies of 99.98%, 99.96%, 99.87%, and 98.78%.	Automated age measurement with high precision for forensic applications	(18)
Atas et al. (2022)	Modified Deep Learning Neural Network	Panoramic radiographs	1,332 dental panoramic radiography	mean absolute error (MAE): 3.13, root mean square error (RMSE): 4.77, R ² : 87%	Faster and more accurate dental age estimation with reduced parameters	(62)
Bunyarit et al. (2022)	artificial neural networks multi-layer perceptron (ANN-MLP)	Dental panoramic tomographs	1015 dental panoramic tomographs (494 male and 521 female)	The Chaillet and Demirjian method underestimated dental age 1.68 and 2.56 years in males and females, indicating inaccurate age estimation. The AI model decreased the MAE by 12 and 25 days for boys and girls.	A novel prediction model using ANN-MLP showed promise in increasing the precision of age estimation in children and adolescents	(63)
Mu et al. (2022)	Deep learning (ResNet, EfficientNet, VggNet, and DenseNet)	Panoramic photographs	3000 images (2400 for training, 300 for validation, and 300 for test)	EfficientNet-B5 was the top performer with 2.83 MAE and 4.59 RMSE	AI models can identify various features across age groups and are applicable for estimating age	(64)
Shan et al. (2022)	ML models (SVR, BPNN, RF, AdaBoost, KNN, Light GBM, XGBoost, DT, GBDT, and CatBoost)	Panoramic radiograph images of the South China population	1477 images (644 male and 833 female)	GBDT-based dental age estimation showed MAEs of 0.523/0.441 (training/test) for females and 0.534/0.495 for males. The model's effectiveness was optimized for each age group, with MAEs below 0.25 in the test set.	The GBDT algorithm enhanced forensic age prediction models through machine learning	(65)

Author and Date	AI Algorithm	Image Dataset Type	Sample Dataset Size	Accuracy of Model	Clinical Outcome	Reference
Rocha et al. (2022)	MLR and ANN against Willems method	Panoramic radiographs	1000 images (children from Southeastern Brazil)	Willems' model had overall differences of 0.27 (females) and 0.28 (males). MLR showed 0.54 and 0.35 differences, while ANN had 0.26 and 0.24 (halved the ME in female age predictions and improved 1/3 of male predictions). However, Willems' model performed similarly or better in 40% of age intervals	Willems method remains effective after 20 years; ANN model may enhance it based on sex and age range.	(66)
Alkaabi and Yussof (2022)	Convolution Long Short Term Memory (ConvLSTM) (CNN) for the improvement of DANet (neural network)	Panoramic radiograph images	2676 OPG images	The proposed techniques effectively lower the MAE to 0.75 years (DANet was 0.93 years)	An automated deep neural network using OPG images enables robust age estimation, with experiments showing significant improvement over existing methods	(67)
Milosevic et al. (2022)	ML models (DenseNet201, InceptionResNetV2, ResNet50, VGG16, VGG19, and Xception)	Panoramic radiograph images	2899 panoramic dental x-ray images (86495 tooth x-ray images)	The best model (VGG16) showed 4.94 years MAE for age estimation	Automated models improve forensic odontology accuracy	(68)
Milosevic et al. (2022)	DenseNet20, InceptionResNetV2, ResNet50, VGG16, VGG19 and Xception	Panoramic radiograph images	4035 panoramic dental x-ray images (76416 individual tooth images)	The model for full panoramic dental Xray images achieves a MAE of 3.96 years, a media absolute error of 2.95 years, and an R ² of 0.8439.	Panoramic dental X-ray images enable age estimation via deep learning. Combining teeth and skeletal structure as age indicators improves results, though single-tooth analysis is less effective than using the full image.	(69)
Alkaabi et al. (2023)	Conditional GAN (CGAN) for the improvement of DANet (neural network)	Orthopantomogram + generated OPG images	2676 OPGs images + CGAN generated 1000 new images	DASNET's coefficient of determination (R ²) and Absolute Error (AE) improved to 87%, 0.85, and 1.18 years, respectively, from 74%, 0.72, and 3.45 years when trained using real data.	The proposed method outperforms DASNET (0.87 accuracy, better E-median/AUC), and CGAN can generate training images with pseudo-labels (age, gender).	(70)

Author and Date	AI Algorithm	Image Dataset Type	Sample Dataset Size	Accuracy of Model	Clinical Outcome	Reference
Baydogan et al. (2023)	Age-Net (compared to CNNs like AlexNet, ResNet50, VGG16, SqueezeNet, EfficientNetB0, DenseNet201, and ResNet18) + added algorithms (NB, KNN, MLP, XGBoost, SVM, DT, LD)	OPG	933 orthopantomography images	The Efficient-NetB0-SVM hybrid model showed the best performance with accuracy, precision, sensitivity, F-score, and AUC values of 0.846, 0.850, 0.846, 0.846, and 0.970, respectively	Age-Net could save forensic experts time and money, but current data is limited. More age groups and data may improve its accuracy	(71)
Arian et al. (2023)	PENViT and TriplePENViT (neural networks)	Panoramic radiographs	706 panoramic radiographs	PENViT improved validation accuracy to 70.54% with ArcFace. Validation accuracy without ArcFace was 67.44% for Age and 84.49% for Gender.	The study showed ViT beat CNNs in regression, and ArcFace's performance varied. Also, PENViT showed higher validation accuracy than other backbones	(72)
Bui et al. (2023)	Mask R-CNN, U-Net with TDA	Mandibular radiographs (OPGs)	456 images	U-Net: 91.2% mIoU vs Mask R-CNN: 83.8%, 95% accuracy vs expert	Automated I3M solution with satisfying results compared to a forensic expert	(73)
Kim et al. (2023)	CNN age group classification	Panoramic dental radiographs	10,023 OPGs	The accuracies were 53.846% for ± 5 years tolerance, 95.121% for ± 15 years, and 99.581% for ± 25 years	Age group classification is possible even with imprecise chronological data	(74)
Shen et al. (2023)	Machine learning on the third molar and periodontal ligament of the second molar development (RF, DT, SVM, KNN, BNB, and LR)	Radiographic images	665 orthopantomographs	SVM demonstrated the highest Bayesian posterior probability (0.917) and a Youden index of 0.752	Machine learning techniques like SVM could significantly enhance the accuracy and reliability of age estimation in forensic identification	(75)

Author and Date	AI Algorithm	Image Dataset Type	Sample Dataset Size	Accuracy of Model	Clinical Outcome	Reference
Kahm et al. (2023)	Wide ResNet (WRN) and DenseNet (DN) with supervised learning	Entire dental panorama images	27,877 dental panorama images	In both models, type 2 (heuristic grouping) grouping with the deviation of ± 3 years, achieved the highest accuracy and F1 scores than type 1 (age grouping)	Comprehensive OPG analysis for improved age estimation with novel strategy showed better accuracy	(76)
Pereira de Sousa et al. (2023)	Kvaal method with ML classification (LR, KNN, SVR, DT, RF, and XGBR)	Panoramic radiographs (from the Brazilian population)	554	ML with 4.77 MAE was higher at age estimation than the Kvaal method with 5.68 MAE. XGBR showed best performance (MAE: 4.65)	ML showed promise for improvement in age estimation	(77)
Patil et al. (2023)	SVM, RF, and LR	Digital panoramic radiographs (from the South Indian population)	1000 panoramic radiographs	SVM accuracy: 2-class (86.4%), 3-class (66%), 5-class (42.8%). RF peak performance at 5-class accuracy: 47.6%.	A deep learning model showed right third molar mesial root length was a good age predictor. Combining different root lengths may improve machine learning model accuracy.	(19)
Upalananda et al. (2023)	GoogLeNet (DL)	Digital panoramic radiographs (cropped for mandibular third molar)	800 images	The method achieved an overall accuracy of 82.50%, with varying accuracy across developmental stages (87.50% to 97.50%)	The model showed accurate and available for quick dental age estimation by assessing mandibular third molar development.	(78)
Yusof et al. (2024)	F-DentEst Lab (DCNN)	panoramic dental radiographs,	4892 (Malaysian children)	The deep learning model underestimated chronological age (ME=0.02/0.003 for P1/P2, females/males) and refined stages D1-D5 with substages.	The model aids forensic odontologists in identification and offers a semi-automated approach that significantly reduces human intervention and computational time	(79)
Zhang et al. (2024)	AGENet and AGE-SPOS (Deep Neural Network)	OPGs	27,957 individuals (16,383 females and 11,574 males)	AGE-SPOS achieved an MAE of 1.80 years with 0.95 B FLOPs and Improved accuracy by 0.18 years.	Enhanced forensic age estimation methodology for adult populations	(15)

Author and Date	AI Algorithm	Image Dataset Type	Sample Dataset Size	Accuracy of Model	Clinical Outcome	Reference
Kahm et al. (2023)	Wide ResNet (WRN) and DenseNet (DN) with supervised learning	Entire dental panorama images	27,877 dental panorama images	In both models, type 2 (heuristic grouping) grouping with the deviation of ± 3 years, achieved the highest accuracy and F1 scores than type 1 (age grouping)	Comprehensive OPG analysis for improved age estimation with novel strategy showed better accuracy	(76)
Pereira de Sousa et al. (2023)	Kvaal method with ML classification (LR, KNN, SVR, DT, RF, and XGBR)	Panoramic radiographs (from the Brazilian population)	554	ML with 4.77 MAE was higher at age estimation than the Kvaal method with 5.68 MAE. XGBR showed best performance (MAE: 4.65)	ML showed promise for improvement in age estimation	(77)
Patil et al. (2023)	SVM, RF, and LR	Digital panoramic radiographs (from the South Indian population)	1000 panoramic radiographs	SVM accuracy: 2-class (86.4%), 3-class (66%), 5-class (42.8%). RF peak performance at 5-class accuracy: 47.6%.	A deep learning model showed right third molar mesial root length was a good age predictor. Combining different root lengths may improve machine learning model accuracy.	(19)
Upalananda et al. (2023)	GoogLeNet (DL)	Digital panoramic radiographs (cropped for mandibular third molar)	800 images	The method achieved an overall accuracy of 82.50%, with varying accuracy across developmental stages (87.50% to 97.50%)	The model showed accurate and available for quick dental age estimation by assessing mandibular third molar development.	(78)
Yusof et al. (2024)	F-DentEst Lab (DCNN)	panoramic dental radiographs,	4892 (Malaysian children)	The deep learning model underestimated chronological age (ME=0.02/0.003 for P1/P2, females/males) and refined stages D1-D5 with substages.	The model aids forensic odontologists in identification and offers a semi-automated approach that significantly reduces human intervention and computational time	(79)
Zhang et al. (2024)	AGENet and AGE-SPOS (Deep Neural Network)	OPGs	27,957 individuals (16,383 females and 11,574 males)	AGE-SPOS achieved an MAE of 1.80 years with 0.95 B FLOPs and Improved accuracy by 0.18 years.	Enhanced forensic age estimation methodology for adult populations	(15)

Author and Date	AI Algorithm	Image Dataset Type	Sample Dataset Size	Accuracy of Model	Clinical Outcome	Reference
Ali et al. (2024)	Machine learning algorithms (Catboost, GBM, AdaBoost, RF, XGB, LGB, ETC)	Dental biometrics (bitewing images)	862 individuals (459 males and 403 females)	RF and XGB models were effective F1 score: 73.26% for age estimation of XGB (peak performance)	Explainable AI model for automated age estimation in living individuals	(80)
Franco et al. (2024)	DenseNet121 (CNN)	Panoramic radiographs	11,640 (9680 for training and 1960 for validation) (5400 male and 6240 female)	AUC was 0.87 and 0.86 to classify males and females below and above the age of 14, 0.88 (males) and 0.83 (females) of 16, 0.94 (males) and 0.83 (females) of 18. Specificity rates were always between 0.80 and 0.92	Artificial intelligence successfully categorized males and females as being below or above the legal age limits of 14, 16, and 18 years with precision.	(81)
Oliveira et al. (2024)	CNN (InceptionV4)	Panoramic radiographs (Brazilian patients)	12,827 dental panoramic X-ray images	MAE of 3.1 years and R2value of 95.5%	Accurate age estimation using odontological features (like pulp chamber dimensions and tooth calcification stage) and anatomical data from the mandible, maxillary sinus, and vertebrae, even for edentulous cases.	(82)
Park et al. (2024)	Multi-task CNN (ForensicNet, EfficientNet-B3)	Panoramic radiographs	13,200 images	MAE of 2.93 ± 2.61 years and a coefficient of determination of 0.957 for chronological age	automatic and accurate estimation of both sex and chronological age from OPGs	(83)
Bizjak et al. (2024)	DentAge (CNN like ResNet34 based)	Panoramic dental X-ray	21,007 images	MAE was 3.12 years (ranging from 1.94 to 13.40). The least MAE was in the 10-20 group	Model strong performance across various age groups and dental conditions highlights its practical value	(84)
Büyükçakır et al. (2024)	EfficientNet-B4, DenseNet-201, and MobileNet V3	Orthopantomograms	3896 OPGs	The EfficientNet-B4 model showed an MAE of 0.562 at the size of 160. Increasing batch size improved performance for EfficientNet-B4 and DenseNet-201 models	Optimized hyperparameters enhance age estimation models. This will improve applications of deep learning in forensic sciences	(85)

Author and Date	AI Algorithm	Image Dataset Type	Sample Dataset Size	Accuracy of Model	Clinical Outcome	Reference
Dai et al. (2024)	ML algorithms (SVR, GBR, DTR, BRR, AdaBoost, KNN, ETR, RF, MLP, and PLS)	Orthopantomograms (from southwest Chinese population)	851 (449 males and 402 females)	Partial least squares regressor (PLS) outperformed other models in males with 4.151 years MAE. The SVR showed good performance in females (MAE= 3.806 years)	Machine learning models can help experts make accurate, understandable age assessments.	(86)
Hamidi et al. (2024)	Genetic Algorithm-Deep Neural Network (GADNN) and traditional ML algorithms (LR, RF, MLP, DL)	Cone-beam computed tomography	240 CBCT images (129 females and 111 males)	GADNN age determination showed the 68% accuracy. DL and RF showed accuracy of 92% and 57%	A combined method showed potential to improve sex and age determination accuracy	(87)
Murray et al. (2024)	CNN (DenseNet121)	Digital panoramic radiographs	4003 panoramic radiographs (2149 female and 1809 male)	The model showed 0.875 accuracy, 0.870 sensitivity, 0.879 specificity, 0.880 precision, and 0.876 F1-score	AI-powered machine vision can accurately identify adults using panoramic radiographs	(88)
Hundur et al. (2024)	3 CNN models	OPG	3716 orthopantomograms (1700 males and 2016 females)	Model 2 showed an accuracy of 97.90% in classifying into age groups. Model 3 predicts the age of individuals with the accuracy of 96.12%	CNNs accurately estimate gender/age from orthopantomograms (over 95% accuracy)	(89)
Matthijs et al. (2024)	CNN (DenseNet201)	Panoramic radiographs	1639 radiographs	Model accuracy, MAE, linearly weighted Cohen's Kappa, and intra-class correlation coefficient were 0.53, 0.71, 0.71, and 0.89, respectively	Mandibular molar development aids in leveraging automated age estimation	(90)
Merdietio Boedi et al. (2024)	CNN (MLR, SVR, and RT)	Cone-beam computed tomography	99 patients (45 males and 54 females)	Maxillary lateral incisor had the lowest error via SVR with 4.86 years MAE and 6.05 years RMSE	SVR-Poly modeling offers superior performance, especially for maxillary canines, but requires more time and training	(14)
Mohammad et al. (2024)	DCNN (F-DentEst Lab)	OPG	1892 digital dental panoramic images	The model underestimated chronological age with a ME of 0.03 and 0.05 for females and males, respectively.	A model for semi-automated dental staging shows promising results, outperforming other methods with minimal ME for both sexes and tooth types,	(91)

Author and Date	AI Algorithm	Image Dataset Type	Sample Dataset Size	Accuracy of Model	Clinical Outcome	Reference
Nafiyah et al. (2024)	ML methods used are MLP, DT, NB, KNN, LL, and SVM	Mandibular image on panoramic radiography	120 patients (61 males and 59 females)	MLP identifies age with 0.625 accuracy, 0.267 precision, 0.350 recall, and 0.297 F1 score as the best performer	Study suggests that MLP is the best model for age estimation and KNN is for gender prediction	(24)
Ozlu Ucan et al. (2025)	2D-DCNN with Modified Genetic-Random Forest	OPG images	At least 621 images (275 male and 346 female)	the MSE value was 0.00027, MAE value was 0.0079, RMSE was 0.0888, and R2 score was 0.999	Automated tooth age estimation addressing methodological variability	(16)
Li et al. (2025)	CNN models (LeNet-5, AlexNet, VGG-16, ResNet-50, Swin Transformer, and ConvNeXt)	Oral panoramic imaging	3,790 panoramic dental radiographs (1,693 males and 2,097 females)	ResNet-50 showed 1.13 MAE, 0.924 R2, 0.839 accuracy and ConvNeXt showed 1.12 MAE, 0.918 R2, 0.820 accuracy	Specialized approach for adolescent age determination using AI	(92)
Palmela Pereira et al. (2025)	CNN (VGG16 pre-trained model)	Orthopantomograms (OPGs)	1,235 (from 1,050 patients)	85% accuracy for age classification (model performed better between 16 and 23 years)	Useful for forensic identification of unknown people, especially in mass disasters	(93)
Kurniawan et al. (2025)	16-layer CNN architecture	Panoramic radiographs	801	average accuracy, precision, recall, and F1 score of 74% (highest F1 scores were in the 10-year and 12-year groups)	CNN advancements in forensic dentistry increase the precision and efficiency of age estimation	(94)
Upalananda et al. (2025)	ResNet-18, DenseNet-121, EfficientNet-B0, MobileNetV3 (for age estimation); YOLOv8-Nano (for canine detection)	Periapical radiographs of canine teeth	2,587 radiographs from 1,004 patients (691 females, 313 males)	MAE ranged from 3.55 to 5.18 years. YOLOv8-Nano model achieved F1 score of 0.994, and 98.94% detection success rate	The proposed framework is a promising and reliable tool for forensic age estimation	(95)
Balel et al. (2025)	YOLOv11-based deep learning model	Panoramic radiographs	4800 (for train) + 650 (for comparison)	No significant difference was found between manual assessment and AI (p = 0.433), though age-related prediction errors were notable in the AI model. Peak performance: 2nd Molar-H class (Precision: 0.99, F1: 0.995). Lowest performance: 1st Molar-B class (Precision: 0.471, F1: 0.601).	AI model revealed comparable accuracy and even higher performance in later stages of tooth development than the manual Demirjian method.	(96)

Author and Date	AI Algorithm	Image Dataset Type	Sample Dataset Size	Accuracy of Model	Clinical Outcome	Reference
Kim et al. (2025)	deep learning model (EfficientNetV2)	OPG	2067 orthopantomograms	MAE for age estimation was 3.43 years and R ² was 0.941. while the human accuracy ranges from 16.4 % to 91.3 % for age estimation.	AI accurately estimates sex and age from dental X-rays and outperforms humans in accuracy for forensic applications.	(97)
Yilmaz et al. (2025)	DL models (Xception, ResNet, ShuffleNet, InceptionV3, DarkNet, NasNet, DenseNet, EfficientNet, MobileNet, ResNet18, GoogleNet, SqueezeNet, and AlexNet) and DnCNN	Orthopantomography (OPG)	1941 pediatric patients' images	Xception showed best performance with a PAM score of 0.8828.	Deep learning model significantly improves forensic age estimation from OPG images, offering accurate age classification for legal use.	(98)
Ramamoorthy et al. (2025)	ML models (gradient boosting and neural networks)	digital dental panoramic radiographs	1000 OPGs	Gradient boosting (AUC=0.959, accuracy=0.765) outperformed the neural network (AUC=0.821, accuracy=0.529) in classification.	Gradient boosting is interpretable and efficient on small datasets. Neural networks model is complex and high-dimensional but need more resources.	(99)
Alam et al. (2025)	Neural network models (CNN, VGG16, VGG19, ResNet50, ResNet101, ResNet152, MobileNet, DenseNet121, DenseNet169) and vision-language models (Vision Transformer and Moondream2)	Panoramic radiographs	437 panoramic radiographs	DenseNet169 outperformed other models in age regression, achieving an R ² score of 0.57 and MAE of 7.07.	CNN and DenseNet169 excelled in sex classification and age regression from dental X-rays.	(17)

Table 3. Comprehensive overview of artificial intelligence algorithms and machine learning models applied to gender/sex determination from dental and craniofacial radiographic images. Study populations ranged from 20 to 207,946 individuals across multiple demographics including Turkish, Chinese, Iranian, Northern Chinese, and Brazilian populations across 33 studies.

Author and Date	AI Algorithm	Image Dataset Type	Sample Dataset Size	Accuracy of Model	Clinical Outcome	Reference
Akkoç et al. (2017)	DCT and RF algorithms	3D digital maxillary tooth plaster	40 Turkish individuals	RF showed A 85.166% average classification accuracy and 91.75% for AUC	The study proposes an accurate system to determine gender from 3D models of maxillary teeth	(100)
Ke et al. (2020)	Multiple Feature Fusion Model (CNN)	OPGs (from Chinese population)	19,976 panoramic dental X-ray images	The proposed method achieved the best performance (94.56% ± 0.58%) and the fastest speed (142 images/second) on the large dataset.	The model's saliency map highlights teeth, key for gender estimation. The method showed a promise for the gender estimation	(25)
Ortiz et al. (2020)	Neural Network (also SVM, RDA, cascade-forward/feed-forward neural networks, KNN, NB, LR)	Panoramic radiographs (anatomical points)	100	The best analysis for TrP accuracy was 0.937 via KNN and in Neural Network with 0.992. For the TeP, the Neural Network model presented the best results with 0.891 accuracy.	ML techniques improved accuracy significantly over discriminant analysis.	(101)
Patil et al. (2020)	ANN, LR, and discriminant analysis	Digital panoramic radiographs (mandible cut)	509 individuals	ANN was most accurate (75%) compared to discriminant analysis (69.1%) and logistic regression (69.9%)	ANN accurately predicts gender, automating gender ID in forensics	(102)
Esmailyfard et al. (2021)	RF Algorithm, SVM, NB	First Molar Teeth in CBCT Images	485 individuals (245 men and 240 women)	NB outperformed other methods for sex classification. NB, RF, and SVM AUC values were 0.918, 0.878, and 0.890, respectively. NB with genetic algorithm achieved 92.31% accuracy, 91.23% sensitivity, 89.83% precision, and 92.01% specificity.	First molar measurements offer acceptable sex classification and automated methods can combine with this parameter	(103)

Author and Date	AI Algorithm	Image Dataset Type	Sample Dataset Size	Accuracy of Model	Clinical Outcome	Reference
Gamulin et al. (2021)	SVM and ANN	Human extracted teeth	55 teeth (19 premolars and 36 molars)	AUC ranging 0.965–0.99 for all molar models. The classification accuracy was ≈70–90% for molars compared to ≈50–70% for premolars. SVM showed lower accuracy. premolar apex and premolar anatomical neck grouped accuracy was 60%.	Raman spectroscopy of teeth showed proper accuracy. ANN models performed slightly better, especially with molar apex data	(104)
Vila-Blanco et al. (2021)	CNN	Orthopantomographies (mandible)	1,195 images	87.8% of accuracy for sex estimation	The shape model offers quantitative analysis and visualization of mandible changes, beneficial for clinical, surgical, dental, or legal applications.	(60)
Vila-Blanco et al. (2022)	CNN	Orthopantomographies	1746 OPGs	Accuracy of sex classification was 91.82%	The model enables age and sex analysis per tooth, aiding experts in identifying relevant teeth, cohorts, or developmental issues	(61)
Milosevic et al. (2022)	ML models (DenseNet201, InceptionResNetV2, ResNet50, VGG16, VGG19, and Xception)	Panoramic radiograph images	2899 panoramic dental x-ray images)86495 tooth x-ray images)	The best model (VGG16) showed 76.41% accuracy for sex assessment	Automated models improve forensic odontology accuracy	(68)
Franco et al. (2022)	CNN (FS and TL)	Panoramic radiographs (ROI extracted)	4003 panoramic radiographs	TL accuracy: 82% vs FS: 71%. Accuracy for classifying adults (≥15 years) was 87% (females) and 84% (males), and for children (<15 years) was 80% (females) and 83% (males). AUC was 0.87-0.91	CNN-based models show promise for sex determination in dental forensics	(105)
Khazaei et al. (2022)	DenseNet, ResNet, and VGG (CNNs)	Lateral cephalometric radiographs (from Iranian population)	1,476 subjects (794 women and 682 men)	90% overall accuracy for sex determination (DenseNet121 as the best performer)	CNNs accurately predicted sex via automated feature extraction. Larger studies are needed for broader accuracy.	(106)

Author and Date	AI Algorithm	Image Dataset Type	Sample Dataset Size	Accuracy of Model	Clinical Outcome	Reference
Zhou et al. (2023)	Deep learning with Grad-CAM	Intraoral front view photographs	10,000 intraoral images (4786 males and 5214 females)	The model achieved 86.5% and 82.5% accuracy with uncropped and cropped images, respectively. Simulated removal of lips/bone showed mandibular and maxillary anterior teeth had similar importance for sex determination.	Deep learning accurately identifies gender from intraoral photos	(107)
Arian et al. (2023)	PENViT and TriplePENViT (neural networks)	Panoramic radiographs	706 panoramic radiographs	PENViT improved validation accuracy to 70.54% with ArcFace. Validation accuracy without ArcFace was 67.44% for Age and 84.49% for Gender.	Study showed ViT beat CNNs in regression and ArcFace's performance varied. Also, PENViT showed higher validation accuracy than other backbones	(72)
Bu et al. (2023)	ResNeXt101, EfficientNet L2, TResNet_xl, MiniViT, CoAtNet-4, Proposed model (CNN-based)	Orthopantomograms (OPGs) (from the Northern China population)	10,703 (total)	Accuracy was 76.92-86.79% (test set); 90.97% (adults), 82.64% (minors)	The model accurately identifies sex for adults by skeletal remains, offering forensic value and a reference for minors.	(108)
Ciconelle et al. (2023)	Standard CNN and ResNet	Panoramic radiographs	207,946 panoramic dental X-rays	CNN sex estimation accuracy: 95.02% (affected by image resolution). ResNet accuracy: 86% (age >6), 96% (age >16). Better performance on females; AUC >96% for most ages (except youngest).	AI tool accurately determines sex using dental records, while image resolution, age, and sex can affect results.	(109)
Bianchi et al. (2023)	GMA-ANN	3D dental scans (The upper first and second left premolars and the upper left first molar)	230 images (115 males and 115 females)	The method achieved 82% overall accuracy, classifying 94% of females and 68% of males correctly.	Premolar shape differences are more sexually dimorphic than first upper molars	(110)
Ali et al. (2024)	Machine learning algorithms (Catboost, GBM, AdaBoost, RF, XGB, LGB, ETC)	Dental biometrics (bitewing images)	862 individuals (459 males and 403 females)	RF and XGB models were effective F1 score: 77.53% for gender estimation of RF (peak performance)	Explainable AI model for automated age estimation in living individuals	(80)

Author and Date	AI Algorithm	Image Dataset Type	Sample Dataset Size	Accuracy of Model	Clinical Outcome	Reference
Park et al. (2024)	Multi-task CNN (ForensicNet, EfficientNet-B3)	Panoramic radiographs	13,200 images	0.992 accuracy, 0.993 specificity, and 0.990 sensitivity for gender prediction	automatic and accurate estimation of both sex and chronological age from OPGs	(83)
Hundur et al. (2024)	3 CNN models	OPG	3716 orthopantomograms (1700 males and 2016 females)	Model 1 showed 95.98% gender prediction accuracy.	CNNs accurately estimate gender/age from orthopantomograms (over 95% accuracy)	(89)
Hamidi et al. (2024)	Genetic Algorithm-Deep Neural Network (GADNN) and traditional ML algorithms (LR, RF, MLP, DL)	Cone-beam computed tomography	240 CBCT images (129 females and 111 males)	GADNN sex determination showed the 86% of accuracy. DL and RF showed accuracy of 78% and 71%	a combined method showed potential to improve sex and age determination accuracy	(87)
Franco et al. (2024)	DenseNet121	Digital panoramic radiograph (permanent left mandibular canines)	13,046 teeth (5838 males and 7208 females)	The accuracy was between 57-76% (mean: 68%±5%). The AUC was between 0.58 and 0.77. The best performances: around the age of 12 years, the worst: around the age of 7 years.	Canine morphological analysis for sex estimation should only be used when other dimorphic features are unavailable.	(22)
Nafiyah et al. (2024)	ML methods used are MLP, DT, NB, KNN, LL, and SVM	Mandibular image on panoramic radiography	120 patients (61 males and 59 females)	KNN identifies gender with 0.750 accuracy, 0.764 precision, 0.750 recall, and 0.733 F1 score as the best performer	Study suggests that MLP is the best model for age estimation and KNN is for gender prediction	(24)
Machado et al. (2024)	DT, RF, and ANN	Cone beam computed tomography	54 individuals	accuracy rate was >80% for males and >82% for females	This link between facial measurements and sex was confirmed. ML revealed the predictive and enhancing power in forensic	(111)
Pretorius et al. (2024)	SIMCA, PLS – DA, ANN and SVM	Bovine mandibles or jaw bone	107 (497 teeth)	The prediction of animal sex on the test set achieved 95% accuracy using a PLS-DA (SVM: 93%)	NIR spectroscopy shows promise for geographic origin discrimination in cattle. Similar studies on human teeth could aid forensic investigations	(112)

Author and Date	AI Algorithm	Image Dataset Type	Sample Dataset Size	Accuracy of Model	Clinical Outcome	Reference
Pertek et al. (2024)	ML algorithms (KNN, DT, SVM, NB, linear discrimination analysis, and ANN)	digital panoramic radiography	200 patients	all features yield $82.6 \pm 0.5\%$ accuracy. Individually, coronoid ($80.9 \pm 0.9\%$), condyle ($78.2 \pm 0.5\%$), and ramus height ($77.2 \pm 0.4\%$) are most accurate. NB algorithm achieves the highest accuracy at $84.0 \pm 0.4\%$.	Machine learning can accurately determine gender by analyzing mandibular structures in panoramic radiographs	(113)
Noel et al. (2024)	3D data modeling (Resnet3D, PointNet++, and MeshNet)	facial computed tomograms (CTs)	98 skull samples	All three approaches achieve AUC scores above 0.9; PointNet++ is most accurate, MeshNet least.	Deep learning models may aid gender-affirming craniofacial surgery planning and sex classification of 3D skull images	(114)
Kim et al. (2025)	deep learning model (EfficientNetV2)	OPG	2067 orthopantomograms	Sex estimation accuracy was 90.2 %	AI accurately estimates sex and age from dental X-rays and outperforms humans in accuracy for forensic applications.	(97)
Alam et al. (2025)	Neural network models (CNN, VGG16, VGG19, ResNet50, ResNet101, ResNet152, MobileNet, DenseNet121, DenseNet169) and vision-language models (Vision Transformer and Moondream2)	Panoramic radiographs	437 panoramic radiographs	Neural networks outperformed Moondream2 in sex classification, achieving 85% accuracy and 0.85 AUC versus 49% accuracy and 0.48 AUC. CNNs showed the best precision, recall, and F1 score for both sexes.	CNN and DenseNet169 excelled in sex classification and age regression from dental X-rays.	(17)
Talebi et al. (2025)	RDA, SVM, and cascade-forward and feed-forward neural network	Panoramic radiographs (maxillary left first molars) (from Iranian population)	131 panoramic radiographs (65 males and 66 females)	SVM best classified sex using length/width (scheme I) and variable ratios (scheme II). CEJL had the highest AUC (78.8). AUC was 75.27% and 70.08% for the schemes I and II for SVM	CEJL serves as an accurate metric for estimating sex (above 6.25 indicating male). AI can help in improving analysis	(115)

Author and Date	AI Algorithm	Image Dataset Type	Sample Dataset Size	Accuracy of Model	Clinical Outcome	Reference
Pereira et al. (2025)	VGG16 (CNN)	Panoramic radiographs	1050 OPGs	the model showed a F1-scores of 0.89 similar in both sexes	CNNs classify human remains by sex for medico-legal use with 89% accuracy, but further research is needed to improve performance.	(116)
Prabha et al. (2025)	ML models (RF and XGBoost)	lateral cephalometric radiographs	712 lateral cephalometric radiographs	RF: 97.20% accuracy, 97.65% precision, slightly better than XGBoost: 96.26% accuracy, 95.40% precision	ML models accurately determine sex from jaw features, promising forensic and clinical application	(117)
Kristanto et al. (2025)	ANN and SVM	human dental extracted teeth	20	ANN achieved 75% accuracy in identifying gender on Dentin surfaces. SVM, radial basis functions, and restricted Boltzmann machines were used for Enamel	Enamel and Dentin surfaces show potential for gender prediction via chemometric methods	(118)
Sowmya et al. (2025)	RF, NB, ANN, and Gradient boosting	CBCT and OPG	200 CBCTs + 200 OPGs	Models' accuracy: RF (98%), NB (97%), ANN (92%), and gradient boosting (98%). The Neural Network showed an AUC of 0.922 and a F1 score of 0.863 (Gradient boosting showed AUC of 0.994 and a F1 score of 0.979)	Gonial angle, a mandibular measurement, can help determine gender. CBCT is more accurate/reliable than OPG, especially for the right gonial angle. Neural networks and gradient boosting also predict gender using gonial angle measurements	(23)

Table 4. Comprehensive overview of artificial intelligence algorithms and machine learning models applied to dental identification and biometric applications from radiographic and digital dental images. The table presents chronological developments in automated dental identification methodologies, including algorithm types, imaging modalities, dataset characteristics, performance metrics, and forensic applications across 26 studies spanning twenty years of research in forensic dentistry and human identification systems. Study populations ranged from 10 to 43,467 cases across multiple demographics and applications.

Author and Date	AI Algorithm	Image Dataset Type	Sample Dataset Size	Accuracy of Model	Clinical Outcome	Reference
Chen et al. (2005)	Mixture of Gaussians, Anisotropic Diffusion, and Sequential Quadratic Programming	Dental radiographs	25 subjects (414 PM teeth and 738 AM teeth)	Tooth-Level Matching: 95% of genuine teeth ranked in the top 8%. Image-Level Matching: 90% of genuine images ranked in the top 7%. Subject Identification: Top-1: 72% accuracy, Top-4: 91% accuracy, Top-7: 100% accuracy.	The system uses AI for feature extraction and matching, ensuring accurate dental biometric identification even with poor image quality.	(119)
Chomdej et al. (2006)	IDIS (18 non-redundant identification models)	Dental information + dental digital image	3000 known subjects	Performance: Advanced: 82.61–100% accuracy, 0–1.19% error (max F16). Moderate: 61.14–99.22% accuracy, 0.67–10.15% error. Elementary: 60.42–88.81% accuracy, 1.43–13.72% error	IDIS uses rule-based AI and database matching for accurate forensic dental ID, ensuring <1.2% error even with incomplete data—ideal for mass disasters or investigations.	(120)
Pushparaj et al. (2014)	linear SVM	Periapical and bitewing images	166 dental Images (124 radiographs and 42 photographs) (442 teeth)	Tooth classification: 94.9% accuracy (basic features), 95.8% (geometric features added). Radiograph matching: Contour & skeleton-based 77.4% top-1, 96.7% top-15. Texture-based 70.9% top-1. Photograph matching: Contour-based 69.2% top-1, skeleton-based 66.6% top-1	An AI-driven system for dental victim identification offers high accuracy and clinical benefits: faster searches, adaptability with radiographs/photos, and reliable results despite missing or altered teeth	(121)
Miki et al. (2017)	DCNN with AlexNet	Dental Cone-Beam CT images	52 CBCT	average classification accuracy was 88.8% (data augmentation improved it approximately 5%)	Showed potential utility for automatic dental information recording	(122)
Heinrich et al. (2018)	SURF and RANSAC algorithm	Panoramic radiographs (PR)	43467 PRs (24545 patients)	The model showed 85 % accuracy in the test model	Automatic palatal rugae and computer vision offer fast and reliable identification even with altered dental features	(31)

Author and Date	AI Algorithm	Image Dataset Type	Sample Dataset Size	Accuracy of Model	Clinical Outcome	Reference
Chen et al. (2019)	Faster R-CNN with Inception ResNet v2	Digital dental periapical films	1250 dental X-ray films	Precision and recall >90%, mean IoU: 91%	High accuracy in dental detection and numbering for identification purposes	(123)
Matsuda et al. (2020)	Simple CNN (VGG16, ResNet50, Inception-v3, InceptionResNet-v2, Xception, and MobileNet-v2)	Orthopantomography	30 (before and after images)	VGG16 reached 100% accuracy with pretraining and fine-tuning; all models exceeded 80% accuracy after fine-tuning (Inception ResNet-v2: 96.7%)	CNN-based approach for individual identification using panoramic radiographs	(33)
Fan et al. (2020)	DENT-net (Custom CNN)	Panoramic dental radiographs (PDRs) with 5 landmarks	15,369 PDRs from 6300 individuals	Rank-1: 85.16%, Rank-5: 97.74%, AUC: 0.996	High accuracy for age estimation based on forensic experience landmarks	(36)
Lee et al. (2020)	CNN (GoogLeNet Inception-v3)	Panoramic and periapical radiographs	5390 panoramic and 5380 periapical radiographic images	CNN (AUC=0.971, 95% CI 0.963–0.978) and periodontist (AUC=0.925, 95% CI 0.913–0.935) demonstrated reliable classification accuracy.	Accurate identification of dental implant systems for forensic purposes	(35)
Sathya & Neelaveni (2020)	AlexNet	panoramic images	106 individuals (3159 teeth) (1585 teeth in maxilla and 1574 in mandible)	Performance: Jaw location: 100%. Tooth type: 95-97.5%. Numbering: Molars 94.16%, premolars 93.75%, canines 86.5%, incisors 91.5%. Matching: 95.34% top-1, 97.67% top-2, 100% top-5.	Deep learning automates forensic dental ID, exceeding classical methods in accuracy and speed. Useful for victim identification when other biometrics fail	(124)
Görürgöz et al. (2022)	R-CNN (GoogLeNet Inception v3 CNN)	Periapical radiographs	1686 PA	668 out of 864 teeth were correctly numbered. F1 score: 0.8720, precision: 0.7812, sensitivity: 0.9867	Automated tooth numbering system for forensic dental identification	(37)
Lai et al. (2021)	LCANet (CNN)	2-D panoramic dental X-ray images	1,168 dental panoramic images of 503 individuals	Dental image recognition achieves 87.21% rank-1 and 95.34% rank-5 accuracy for human identification	A novel approach for automated human identification in forensic dentistry using 2-D dental panoramic images. LCANet uses enhanced attention and learned connections for effective dental recognition, offering a large-scale forensic ID alternative to manual methods	(125)

Author and Date	AI Algorithm	Image Dataset Type	Sample Dataset Size	Accuracy of Model	Clinical Outcome	Reference
Milosevic et al. (2022)	ML models (DenseNet201, InceptionResNetV2, ResNet50, VGG16, VGG19, and Xception)	Panoramic radiograph images	2899 panoramic dental x-ray images)86495 tooth x-ray images)	The model showed the accuracy of 87.24% to 99.15% for tooth type determination	Automated models improve forensic odontology accuracy	(68)
Al-Sarem et al. (2022)	Enhanced CNN with pretrained models (AlexNet, VGG16, VGG19, ResNet50, DenseNet169, and MobileNetV3)	CBCT	50	The pretrained DL models achieved over 0.90 precision for normal teeth, with DenseNet169 leading at 0.98. MobileNetV3, VGG19, ResNet50, VGG16, and AlexNet reached 0.95, 0.94, 0.94, 0.93, and 0.92, respectively. DenseNet169 also excelled in CBCT detection/classification, with 93.3% segmentation and 89% missing tooth region classification accuracy	Improved detection accuracy for forensic dental identification applications	(126)
Kim et al. (2022)	CNN (VGG16 & Grad-CAM)	Dental panoramic radiograph	2760 DPRs (746 patients)	The model achieved rank-1, -3, and -5 accuracies of 82.84%, 89.14%, and 92.23%, respectively, Grad-CAM confirmed the model's focus on dental information for human identification	The model accurately identifies people from diverse images, quickly suggesting candidates to experts for efficient identification from large datasets.	(127)
Sandhya et al. (2022)	CNN (KNN, SVM, ANN, and ensemble classifiers)	Lip print picture	120 lip print images of 15 people	ensemble classifiers had the best performance (>95% accuracy). All of the models showed at least 80 % accuracy	Features from upper and lower lip regions effectively identify individuals.	(128)
Thurzo et al. (2022)	CNN (DIAG-NOCAT)	Human mandible with teeth (oral scans, CBCT, and Micro-CT)	10 teeth (1 jaw)	AI automatically segmented CBCT scans (mandible, teeth, nerve canal) in <5 minutes vs. 2+ hours manually. Minor nerve canal/molar contour errors were comparable to manual segmentation.	AI (3D CNN, Diagnocat) efficiently segments dental CBCT scans with high accuracy, but minor errors	(30)

Author and Date	AI Algorithm	Image Dataset Type	Sample Dataset Size	Accuracy of Model	Clinical Outcome	Reference
Hingad et al. (2023)	Deep learning models (multilayer neural networks)	intraoral scans (from rugae palatine)	-	The approach successfully automates the rugae identification	Deep learning and OpenCV automated rugae analysis for forensics, but more studies are needed	(129)
Pretorius et al. (2024)	SIMCA, PLS-DA, ANN and SVM	Bovine mandibles or jaw bone	107 (497 teeth)	SVM, ANN, and SIMCA models showed 89, 79 and 82%, accuracy respectively in predicting tooth type (deciduous, permanent unerupted, and erupted), but struggled to differentiate permanent unerupted from erupted teeth. PLS-DA showed 82% accuracy for discrimination of grain versus grass diet	NIR spectroscopy shows promise for geographic origin discrimination in cattle. Similar studies on human teeth could aid forensic investigations	(112)
Choi et al. 2024	CNN (EfficientDet-D3 - object detection)	Panoramic radiographs	1,029 paired DPRs	AM image matching success rates in the CG were 83.2%, 72.1%, and 59.4% for the top 20%, 10%, and 5% imaging time intervals. Success was sex-dependent, with women higher than men	Automated dental object detection and database creation on DPRs enables more accurate human identification than image comparison	(130)
Mikolicz et al. (2024)	LDA & Supervised ML	Intraoral scan	23 participants (60 scans)	Geometric ID: 91.2% sensitivity, 97.1% specificity. Superimposition: Repeatability 0.011–0.093 mm, MAD 0.214–1.068 mm	Fisher's LDA model accurately identifies individuals from palatal scans across populations	(131)
Palmela Pereira et al. (2025)	CNN (VGG16 pre-trained model)	Orthopantomograms (OPGs)	1,235 (from 1,050 patients)	85% accuracy for positive identification (model performed better at identifying OPG pairs different people)	Useful for forensic identification of unknown people, especially in mass disasters	(93)
Mouncif et al. (2025)	RNN	3D intraoral scanner data	28 individuals (448 tooth)	The method achieved accuracies of 98.01%, 98.88%, and 99.75% for the 16-class, 8-category, and 4-class datasets, respectively.	The method improves classification accuracy across 16, 8, and 4 categories by modeling complex spatial relationships in 3D tooth structures	(132)

Author and Date	AI Algorithm	Image Dataset Type	Sample Dataset Size	Accuracy of Model	Clinical Outcome	Reference
Bozkurt et al. (2025)	SIFT, SURF, KAZE, MSER, and RANSAC algorithms	panoramic X-ray images	250 images	The best models achieved the following Rank-1/5/10 accuracies by teeth-jaw matching approach: SIFT: Mandibular 69/99/99.5%, Maxillary 64/100/100%. SURF: Mandibular 91/95.8/96.3%, Maxillary 88/95.4/96.8%. KAZE: Mandibular 65.9/91/95.2%, Maxillary 69.4/95.3/96.3%.	The study shows the method matches neural network performance with lower computational complexity	(133)
Mikó et al. (2025)	Linear discriminant classification, iterative closest point algorithm, and gaussian smoothing algorithm	intraoral scans of <i>ovis aries rugae</i>	615 scan pairs	Precision: Washed samples 0.013 mm median; unwashed 0.025 mm. Rugae Discrimination Accuracy: Sensitivity declined from 89% (Day 1) to 69% (Day 20); specificity 59-66% over 20 days. 3D Deviation: Scans distinguishable up to 6 days postmortem.	AI-assisted intraoral scanning and machine learning accurately analyze palatal rugae for forensic identification, even after 20 days of postmortem decomposition. The lamb model supports future human studies.	(34)
Yuan et al. (2025)	PointResNet and Additive Angular Margin (AAM) Loss	3D tooth models	100 AM and 100 PM (50 individuals)	PointResNet achieved 99.69% Rank-1 accuracy with no missing teeth and 89.02% average accuracy with 0-15 missing teeth. WFA, local normalization, and residual connections improved accuracy by ~14% over PointNet++.	The deep learning framework for forensic dental identification, achieves 99.69% accuracy with intact dentition and excels in cases with missing teeth. Using 3D point clouds and advanced feature aggregation can outperform traditional methods and other models	(32)

Table 5. The table presents a summary of the study by Mahasantipiya et al. (2011) evaluating the application of an Artificial Neural Network (ANN) for bite mark identification. The model was trained and tested on separate datasets, achieving an average accuracy of 82%.

Author and Date	AI Algorithm	Image Dataset Type	Sample Dataset Size	Accuracy of Model	Clinical Outcome	Reference
Mahasantipiya et al. (2011)	ANN	JPEG images of bite marks (from lower teeth, on pink wax)	250 (training), 100 (testing)	82% (average accuracy)	ANN tested for bite mark identification using 34 features and achieved reasonable accuracy. Further research is needed to refine feature selection and classification methods	(41)

ANN, Artificial Neural Network; JPEG, Joint Photographic Experts Group.

Table 6. Comprehensive overview of artificial intelligence algorithms and machine learning models applied to forensic face reconstruction from radiographic and digital dental images. Gietzen and Brucka (2019) used Principal Component Analysis (PCA) and Iterative Closest Point (ICP) on volumetric CT head scans and 3D surface scans to enable probabilistic face estimation from incomplete skull remains. Mohammed et al. (2024) applied CNN-based methods, SIFT, and GANs with large public datasets (MUG500+, CelebA-mask-HQ) for skull-to-face mapping, showing feasibility but limited real-world validation.

Author and Date	AI Algorithm	Image Dataset Type	Sample Dataset Size	Accuracy of Model	Clinical Outcome	Reference
Gietzen & Brylka (2019)	Principal Component Analysis (PCA), and Iterative Closest Point (ICP)	Volumetric CT head scans; Optical 3D surface scans	Skull model: 62 skulls; Head model: 82 heads; FSTT statistic: 43 skull/skin pairs	Skull registration error < 0.5 mm; Head fitting error 0.19 mm; RMSE for head fittings 1.32-4.04 mm (PCA best fit)	Enables probabilistic face estimation and generation of plausible head variants from incomplete skull remains	(41)
Mohammed et al. (2024)	CNNSPS, SIFT, and GANs	MUG500+ and CelebAMask-HQ datasets	500 segmented skulls (MUG500+) + ~30,000 celebrity face images (CelebAMask-HQ)	The model showed Feasibility on public data, but real-world validation is limited by lack of paired skull-face data.	CNNSPS uses deep learning for forensic facial reconstruction, mapping skull to face via CNN and SIFT	(44)

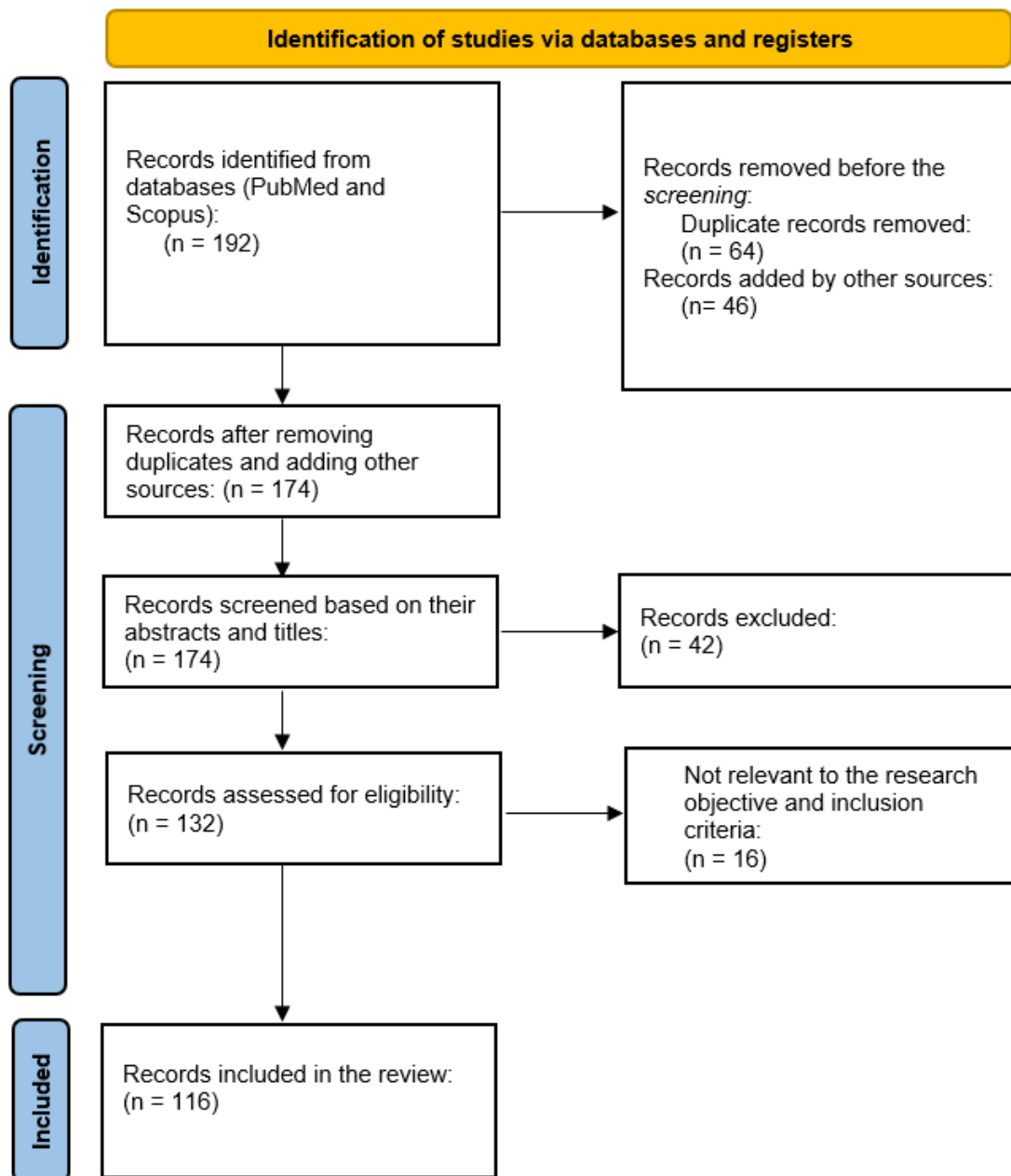


Figure 1. The flowchart illustrates the PRISMA protocol for the inclusion of studies. A total of 192 records were initially added from PubMed and Scopus. After removing 64 duplicates and incorporating 46 records from other sources, 174 unique records remained. Following title and abstract screening, 42 records were excluded. Of the 132 full-text articles assessed for eligibility, 16 were excluded for not meeting the research objectives or inclusion criteria. Ultimately, 116 studies were included in this review.

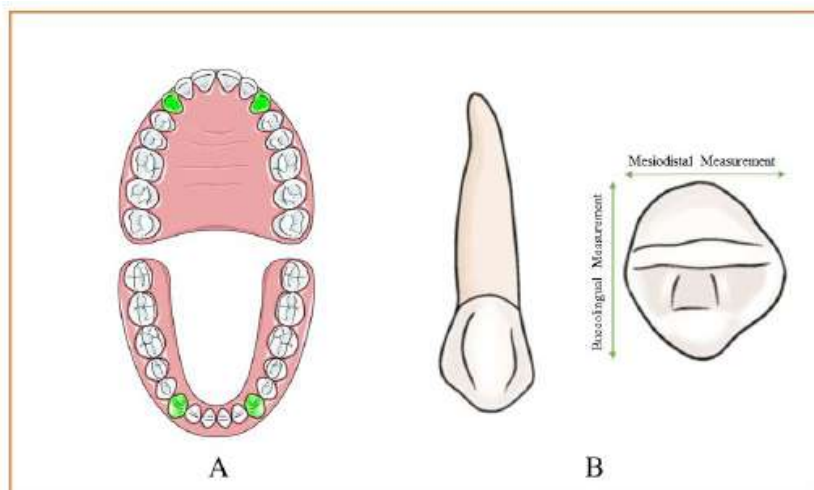


Figure 2. Illustration of mesiodistal and buccolingual measurements of canine teeth, highlighting the application of canine dimorphism in gender estimation within forensic dentistry. A) Canine teeth in both jaws. B) mesiodistal and buccolingual dimensional measurements; these dimensional analyses are crucial for accurate sex determination in forensic investigations.

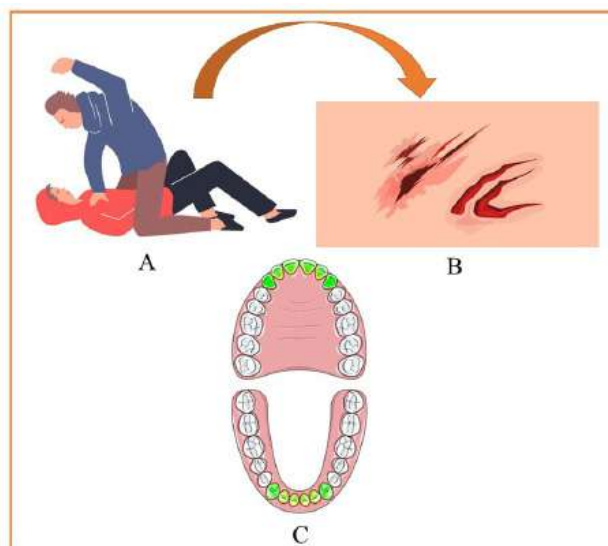


Figure 3. Forensic bite mark analysis: (A) An attacker biting a victim during an assault, (B) The resulting bite wound on the victim’s skin, showing characteristic teeth impressions, and (C) A dental chart highlighting the suspect’s unique bite pattern. Forensic odontologists use such evidence to compare bite marks with dental records, aiding in criminal investigations and suspect identification.

Conclusion

AI is transforming forensic dentistry by improving accuracy, speed, and reliability for applications such as human identification, bite mark analysis, age and gender estimation, dental identification, and facial reconstruction. Machine learning, deep learning, and convolutional neural network automate and refine these processes, improve objectivity, and enable large-scale data analysis, which is essential in mass disaster scenarios. This review included 116 studies across five applications of AI in forensic dentistry. Most studies focused on age (54 studies) and gender estimation (33 studies), followed by human and dental identification (26 studies). Only a few studies examined bite mark analysis (1 study) and face reconstruction (2 studies). Among imaging methods, 72% (84 out of 116) used OPGs, while 10 studies used CBCT, and the remaining studies applied other modalities. CNNs and their variants were the most common algorithms, used in 64% of studies (74 out of 116).

In age estimation, mean absolute error (MAE) values ranged from 0.0079 to 7.07 years, and classification accuracy reached as high as 99.98%. AI also reduced evaluation times to as little as 2.72 seconds. In gender estimation, reported accuracy ranged from 68% to 98%, with F1 scores up to 0.979. In human and dental identification, overall classification accuracy reached 100%, but sensitivity dropped to 69% in some post-mortem cases. Bite mark analysis and face reconstruction had fewer studies, limiting evidence of AI integration. However, the available research suggests AI has potential to improve accuracy in both areas. However, there are certain ethical and practical difficulties, such as data privacy, the risk of algorithmic bias, the “black-box” nature of some models, and the need for transparency. Automation and the risk of workforce displacement require balanced reliance and careful regulation alongside refined protocols. In conclusion, AI is revolutionizing forensic dentistry with improved effectiveness and precision, but unlocking its full potential requires interdisciplinary work and strong research to solve ethical, legal, and methodological issues, along with transparency, accountability, and continuous validation of the AI solutions deployed in the field.

Acknowledgment

The authors sincerely thank Mashhad University of Medical Sciences and its Student Research Committee for their support and assistance.

Conflict of Interest

There is no conflict of interest to declare.

References

- [1] Arthanari A, Raj SS, Ravindran V. A Narrative Review in Application of Artificial Intelligence in Forensic Science: Enhancing Accuracy in Crime Scene Analysis and Evidence Interpretation. *Journal of International Oral Health*. 2025; 17(1).
- [2] Palmela Pereira C, Carvalho R, Augusto D, Almeida T, Francisco AP, Salvado ESF, et al. Development of artificial intelligence-based algorithms for the process of human identification through dental evidence. *Int J Legal Med*. 2025.
- [3] Wankhade TD, Ingale SW, Mohite PM, Bankar NJ. Artificial Intelligence in Forensic Medicine and Toxicology: The Future of Forensic Medicine. *Cureus*. 2022; 14(8):e28376.
- [4] Revolutionizing Forensic Odontology: The Integration of 3D Scanning and AI for Enhanced Identification Processes. *Ricos Biology*. 2025; 3(1):80-92.
- [5] Samaranayake L, Tuygunov N, Schwendicke F, Osathanon T, Khurshid Z, Boymuradov SA, et al. The Transformative Role of Artificial Intelligence in Dentistry: A Comprehensive Overview. Part 1: Fundamentals of AI, and its Contemporary Applications in Dentistry. *International Dental Journal*. 2025.
- [6] Dashti M, Azimi T, Khosraviani F, Azimian S, Bahanan L, Zahmatkesh H, et al. Systematic Review and Meta-Analysis on the Accuracy of Artificial Intelligence Algorithms in Individuals Gender Detection Using Orthopantomograms. *International Dental Journal*. 2025.
- [7] Gharat M, Patil A, Bedia A, Jaiswal H, More S. Revolutionizing Dentistry by Exploring the Potential of Cone-Beam Computed Tomography: A Review. *Cureus*. 2025.
- [8] Khan MS, Afridi U, Ahmed MJ, Zeb B, Ullah I, Hassan MZ. Comprehensive evaluation of artificial intelligence applications in forensic odontology: a systematic review and meta-analysis. *IECE Transactions on Intelligent Systematics*. 2024; 1(3):176-89.
- [9] Setiawardani A, Rahman A, Utama A, Prakosa

- J, Susilo Y. The Role of Artificial Intelligence in 3D Development -Facial Reconstruction of Skull Bones as a Forensic Investigation Solution: A Comprehensive Review. *Jurnal Indonesia Sosial Teknologi*. 2025; 6:774.
- [10] Sancı A, Kaya B. Applications of artificial intelligence in age estimation: a review. *Journal of Radiology in Medicine*. 2024; 1:77-83.
- [11] Schmeling A, Dettmeyer R, Rudolf E, Vieth V, Genserick G. Forensic Age Estimation. *Dtsch Arztebl Int*. 2016; 113(4):44-50.
- [12] Ahmed O, Saleem SA, Khan AA, Daruwala S, Pettiwala A. Artificial intelligence in forensic odontology--A review. *International Dental Journal of Students' Research*. 2023; 11(2).
- [13] Akcay H, Bozkurt Ocbe M. Age Estimation in Pediatric Patients Using Artificial Intelligence Applications: A Traditional Review. 2024.
- [14] Merdietio Boedi R, Shepherd S, Oscandar F, Franco AJ, Mânica S. Machine learning assisted 5-part tooth segmentation method for CBCT-based dental age estimation in adults. *J Forensic Odontostomatol*. 2024; 42(1):22-9.
- [15] Zhang ZY, Yan CX, Min QM, Zhang YX, Jing WF, Hou WX, et al. Leverage Effective Deep Learning Searching Method for Forensic Age Estimation. *Bioengineering (Basel)*. 2024; 11(7).
- [16] Ozlu Ucan G, Gwassı OAH, Apaydin BK, Ucan B. Automated Age Estimation from OPG Images and Patient Records Using Deep Feature Extraction and Modified Genetic-Random Forest. *Diagnostics (Basel)*. 2025; 15(3).
- [17] Alam SS, Rashid N, Faiza TA, Ahmed S, Hassan RA, Dudley J, et al. Estimating Age and Sex from Dental Panoramic Radiographs Using Neural Networks and Vision–Language Models. *Oral [Internet]*. 2025; 5(1).
- [18] Sharifonnasabi F, Jhanjhi NZ, John J, Obeidy P, Band SS, Alinejad-Rokny H, et al. Hybrid HCNN-KNN Model Enhances Age Estimation Accuracy in Orthopantomography. *Frontiers in Public Health*. 2022; Volume 10 - 2022.
- [19] Patil V, Saxena J, Vineetha R, Paul R, Shetty DK, Sharma S, et al. Age Assessment through Root Lengths of Mandibular Second and Third Permanent Molars Using Machine Learning and Artificial Neural Networks. *J Imaging*. 2023; 9(2).
- [20] Banar N, Bertels J, Laurent F, Boedi RM, De Tobel J, Thevissen P, et al. Towards fully automated third molar development staging in panoramic radiographs. *Int J Legal Med*. 2020; 134(5):1831-41.
- [21] Albernaz Neves J, Antunes-Ferreira N, Machado V, Botelho J, Proença L, Quintas A, et al. An Umbrella Review of the Evidence of Sex Determination Procedures in Forensic Dentistry. *J Pers Med*. 2022; 12(5).
- [22] Franco A, Cornacchia AP, Moreira D, Miamoto P, Bueno J, Murray J, et al. Radiographic morphology of canines tested for sexual dimorphism via convolutional-neural-network-based artificial intelligence. *Morphologie*. 2024; 108(362):100772.
- [23] Sowmya S, Sangavi R, yadalam PK. Gradient boosting based prediction of gender based on gonial angle measurements. *Journal of Oral and Maxillofacial Surgery, Medicine, and Pathology*. 2025; 37(5):921-8.
- [24] Nafiyah N, Hanifah AI, Susanto E, Astuti ER, Putra RH, Setyati E. Analysis Of Machine Learning Methods For Gender And Age Identification. *Journal of Theoretical and Applied Information Technology*. 2024; 102(18):6588-600.
- [25] Ke W, Fan F, Liao P, Lai Y, Wu Q, Du W, et al. Biological Gender Estimation from Panoramic Dental X-ray Images Based on Multiple Feature Fusion Model. *Sensing and Imaging*. 2020; 21.
- [26] Neves JA, Lopes LB, Machado V, Botelho J, Delgado AS, Mendes JJ. Evidence of Age Estimation Procedures in Forensic Dentistry: Results from an Umbrella Review. *Medicina (Kaunas)*. 2023; 60(1).
- [27] Vodanović M, Subašić M, Milošević DP, Galić I, Brkić H. Artificial intelligence in forensic medicine and forensic dentistry. *J Forensic Odontostomatol*. 2023; 41(2):30-41.
- [28] Verkhovskiy AE, Apresyan SV, Stepanov AG. [A review of modern digital personal identification methods using artificial intelligence technology in forensic dentistry]. *Stomatologiya (Mosk)*. 2024; 103(6):79-82.
- [29] C D, A B. Artificial intelligence in forensic odontology: A review. *IP International Journal of Maxillofacial Imaging*. 2024; 10:6-10.
- [30] Thurzo A, Jančovičová V, Hain M, Thurzo M,

- Novák B, Kosnáčová H, et al. Human Remains Identification Using Micro-CT, Chemometric and AI Methods in Forensic Experimental Reconstruction of Dental Patterns after Concentrated Sulphuric Acid Significant Impact. *Molecules*. 2022; 27(13).
- [31] Heinrich A, Güttler F, Wendt S, Schenkl S, Hubig M, Wagner R, et al. Forensic Odontology: Automatic Identification of Persons Comparing Antemortem and Postmortem Panoramic Radiographs Using Computer Vision. *Rofo*. 2018; 190(12):1152-8.
- [32] Yuan L, Zhu L, Jo K, Li Y. Dental Identification Based on Single Tooth Feature Concatenation. *IEEE Access*. 2025.
- [33] Matsuda S, Miyamoto T, Yoshimura H, Hasegawa T. Personal identification with orthopantomography using simple convolutional neural networks: a preliminary study. *Sci Rep*. 2020; 10(1):13559.
- [34] Mikó S, Shahbazi A, Pellei D, Simon B, Vág J. Development of an experimental model for assessment of palatal tissue decomposition by intraoral scanner. *Forensic Sci Int*. 2025; 366:112303.
- [35] Lee JH, Jeong SN. Efficacy of deep convolutional neural network algorithm for the identification and classification of dental implant systems, using panoramic and periapical radiographs: A pilot study. *Medicine (Baltimore)*. 2020; 99(26):e20787.
- [36] Fan F, Ke W, Wu W, Tian X, Lyu T, Liu Y, et al. Automatic human identification from panoramic dental radiographs using the convolutional neural network. *Forensic Sci Int*. 2020; 314:110416.
- [37] Görürgöz C, Orhan K, Bayrakdar IS, Çelik Ö, Bilgir E, Odabaş A, et al. Performance of a convolutional neural network algorithm for tooth detection and numbering on periapical radiographs. *Dentomaxillofac Radiol*. 2022; 51(3):20210246.
- [38] Bm A, Fareed D, Babashet D, Srivathsa D. Credibility of bite mark analysis in forensic odontology: A diagnostic accuracy trail. *International Journal of Forensic Medicine*. 2024; 6:18-25.
- [39] Macorano E, Mele F, Calvano M, Leonardelli M, Duma S, De Gabriele G, et al. Reverse engineering in forensic investigations: a new approach to bite mark analysis. *J Forensic Odontostomatol*. 2023; 41(3):45-51.
- [40] Mehar PA, Bhojar LZ, Mahakalkar AL. Integration of Bite Mark Microbiome Analysis with Forensic DNA Profiling: Advancements, Challenges, and Synergistic Approaches. *Rambam Maimonides Med J*. 2024; 15(3).
- [41] P.M M, U Y, T S, J S, A D, T.Thaiupathump. Bite Mark Identification Using Neural Networks: A Preliminary Study. *Lecture Notes in Engineering and Computer Science*. 2011; 1.
- [42] Verkhovskiy AE, Apresyan SV, Stepanov AG. Modern personal identification methods in dentistry. *RJD*. 2024; 28(6):624-33.
- [43] Gietzen T, Brylka R, Achenbach J, Zum Hebel K, Schömer E, Botsch M, et al. A method for automatic forensic facial reconstruction based on dense statistics of soft tissue thickness. *PLoS One*. 2019; 14(1):e0210257.
- [44] Mohammed D, Elgendy M, Taha M. Deep learning approach for forensic facial reconstruction depends on unidentified skull. *IAES International Journal of Artificial Intelligence (IJ-AI)*. 2024; 13:3858.
- [45] Pham CV, Lee SJ, Kim SY, Lee S, Kim SH, Kim HS. Age estimation based on 3D post-mortem computed tomography images of mandible and femur using convolutional neural networks. *PLoS One*. 2021; 16(5):e0251388.
- [46] Martin-Fumadó C, Barbería E, Manso J. Artificial intelligence in forensic sciences: The future is now. *Spanish Journal of Legal Medicine*. 2024; 50:89-91.
- [47] Gómez J, Olivero MÁ, García-García JA, Escalona MJ. A Practical Experience Applying Security Audit Techniques in An Industrial Healthcare System. In: Misra S, Arumugam C, editors. *Illumination of Artificial Intelligence in Cybersecurity and Forensics*. Cham: Springer International Publishing; 2022. p. 1-20.
- [48] Geradts Z, Franke K. *Artificial Intelligence (AI) in Forensic Sciences*: John Wiley & Sons; 2023.
- [49] Savage N. Breaking into the black box of artificial intelligence. *Nature*. 2022.
- [50] Marsico F, Amigo M. Ethical and security challenges in AI for forensic genetics: From bias to adversarial attacks. *Forensic Science International: Genetics*. 2025; 76:103225.

- [51] Sharma N, Chand R, Buksh Z, Ali ABMS, Hanif A, Beheshti A. Explainable AI Frameworks: Navigating the Present Challenges and Unveiling Innovative Applications. *Algorithms*. 2024; 17:227.
- [52] Ahmed Alaa El-Din E. Artificial Intelligence In Forensic Science : Invasion Or Revolution? *Egyptian Society of Clinical Toxicology Journal*. 2022; 10(2):20-32.
- [53] Bonny T, Al Nassan W, Obaideen K, Rabie T, Al-Mallahi MN, Gupta S. Primary Methods and Algorithms in Artificial-Intelligence-Based Dental Image Analysis: A Systematic Review. *Algorithms [Internet]*. 2024; 17(12).
- [54] De Tobel J, Radesh P, Vandermeulen D, Thevissen PW. An automated technique to stage lower third molar development on panoramic radiographs for age estimation: a pilot study. *J Forensic Odontostomatol*. 2017; 35(2):42-54.
- [55] Farhadian M, Salemi F, Saati S, Nafisi N. Dental age estimation using the pulp-to-tooth ratio in canines by neural networks. *Imaging Sci Dent*. 2019; 49(1):19-26.
- [56] Merdietio Boedi R, Banar N, De Tobel J, Bertels J, Vandermeulen D, Thevissen PW. Effect of Lower Third Molar Segmentations on Automated Tooth Development Staging using a Convolutional Neural Network. *J Forensic Sci*. 2020; 65(2):481-6.
- [57] Banjšak L, Milošević D, Subašić M. Implementation of artificial intelligence in chronological age estimation from orthopantomographic X-ray images of archaeological skull remains. *Bulletin of the International Association for Paleodontology*. 2020; 14(2):122-9.
- [58] Kim S, Lee YH, Noh YK, Park FC, Auh QS. Age-group determination of living individuals using first molar images based on artificial intelligence. *Sci Rep*. 2021; 11(1):1073.
- [59] Mohammad N, Muad AM, Ahmad R, Mohd Yusof MYP. Reclassification of Demirjian's mandibular premolars staging for age estimation based on semi-automated segmentation of deep convolutional neural network. *Forensic Imaging*. 2021; 24.
- [60] Vila-Blanco N, Varas-Quintana P, Aneiros-Ardao Á, Tomás I, Carreira MJ. Automated description of the mandible shape by deep learning. *Int J Comput Assist Radiol Surg*. 2021; 16(12):2215-24.
- [61] Vila-Blanco N, Varas-Quintana P, Aneiros-Ardao Á, Tomás I, Carreira MJ. XAS: Automatic yet eXplainable Age and Sex determination by combining imprecise per-tooth predictions. *Comput Biol Med*. 2022; 149:106072.
- [62] Atas I, Özdemir C, Ataş M, Dogan Y. Forensic Dental Age Estimation Using Modified Deep Learning Neural Network. *ArXiv*. 2022; abs/2208.09799.
- [63] Bunyarit SS, Nambiar P, Naidu M, Asif MK, Poh RYY. Dental age estimation of Malaysian Indian children and adolescents: applicability of Chaillet and Demirjian's modified method using artificial neural network. *Ann Hum Biol*. 2022; 49(3-4):192-9.
- [64] Mu CC, Li G. Age Estimation using Panoramic Radiographs by Transfer Learning. *Chin J Dent Res*. 2022; 25(2):119-24.
- [65] Shan W, Sun Y, Hu L, Qiu J, Huo M, Zhang Z, et al. Boosting algorithm improves the accuracy of juvenile forensic dental age estimation in southern China population. *Sci Rep*. 2022; 12(1):15649.
- [66] Rocha LT, Ingold MS, Panzarella FK, Santiago BM, de Oliveira RN, de Macedo Bernardino Í, et al. Applicability of Willems method for age estimation in Brazilian children: performance of multiple linear regression and artificial neural network. *Egyptian Journal of Forensic Sciences*. 2022; 12(1).
- [67] Alkaabi S, Yussof S. Multi-level Multi-scale Deep Feature Encoding for Chronological Age Estimation from OPG Images. *Journal of Image and Graphics (United Kingdom)*. 2022; 10(4):151-7.
- [68] Milosevic D, Vodanovic M, Galic I, Subasic M. A Comprehensive Exploration of Neural Networks for Forensic Analysis of Adult Single Tooth X-Ray Images. *IEEE Access*. 2022; 10:70980-1002.
- [69] Milošević D, Vodanović M, Galić I, Subašić M. Automated estimation of chronological age from panoramic dental X-ray images using deep learning. *Expert Systems with Applications*. 2022; 189.
- [70] Alkaabi S, Yussof S, Al-Mulla S. Enhancing CNN for Forensics Age Estimation Using CGAN and Pseudo-Labeling. *Computers, Materials and Continua*. 2023; 74(2):2499-516.
- [71] Baydogan MP, Baybars SC, Tuncer SA. Age-Net: An Advanced Hybrid Deep Learning Model for

- Age Estimation Using Orthopantomograph Images. *Traitement du Signal*. 2023; 40(4):1553-63.
- [72] Arian MSH, Rakib MTA, Ali S, Ahmed S, Farook TH, Mohammed N, et al. Pseudo labelling workflow, margin losses, hard triplet mining, and PEN-ViT backbone for explainable age and biological gender estimation using dental panoramic radiographs. *SN Applied Sciences*. 2023; 5(11).
- [73] Bui R, Iozzino R, Richert R, Roy P, Boussel L, Tafrount C, et al. Artificial Intelligence as a Decision-Making Tool in Forensic Dentistry: A Pilot Study with I3M. *Int J Environ Res Public Health*. 2023; 20(5).
- [74] Kim YR, Choi JH, Ko J, Jung YJ, Kim B, Nam SH, et al. Age Group Classification of Dental Radiography without Precise Age Information Using Convolutional Neural Networks. *Healthcare (Basel)*. 2023; 11(8).
- [75] Shen S, Zhou Z, Wang J, Fan L, Han J, Tao J. Using machine learning to determine age over 16 based on development of third molar and periodontal ligament of second molar. *BMC Oral Health*. 2023; 23(1):680.
- [76] Kahm SH, Kim JY, Yoo S, Bae SM, Kang JE, Lee SH. Application of entire dental panorama image data in artificial intelligence model for age estimation. *BMC Oral Health*. 2023; 23(1):1007.
- [77] Pereira de Sousa D, Diniz Lima E, Souza Paulino JA, Dos Anjos Pontual ML, Meira Bento P, Melo DP. Age determination on panoramic radiographs using the Kvaal method with the aid of artificial intelligence. *Dentomaxillofac Radiol*. 2023; 52(4):20220363.
- [78] Upalananda W, Wantanajittikul K, Na Lampang S, Janhom A. Semi-automated technique to assess the developmental stage of mandibular third molars for age estimation. *Australian Journal of Forensic Sciences*. 2023; 55(1):23-33.
- [79] Yusof MYPM, Mohammad N, Ahmad R, Muad AM. Development and validation of automated Forensic Dental Age Estimation Lab (F-DentEst Lab). *Australian Journal of Forensic Sciences*. 2024; 56(sup1):75-7.
- [80] Ali M, Raza H, Gan JQ, Pokhojaev A, Katz M, Kosan E, et al. An Explainable Machine Learning Approach for Age and Gender Estimation in Living Individuals Using Dental Biometrics. *arXiv preprint arXiv:241108195*. 2024.
- [81] Franco A, Murray J, Heng D, Lygate A, Moreira D, Ferreira J, et al. Binary decisions of artificial intelligence to classify third molar development around the legal age thresholds of 14, 16 and 18 years. *Sci Rep*. 2024; 14(1):4668.
- [82] Oliveira W, Albuquerque Santos M, Burgardt CAP, Anjos Pontual ML, Zanchettin C. Estimation of human age using machine learning on panoramic radiographs for Brazilian patients. *Scientific Reports*. 2024; 14(1):19689.
- [83] Park SJ, Yang S, Kim JM, Kang JH, Kim JE, Huh KH, et al. Automatic and robust estimation of sex and chronological age from panoramic radiographs using a multi-task deep learning network: a study on a South Korean population. *Int J Legal Med*. 2024; 138(4):1741-57.
- [84] Bizjak Ž, Robič T. DentAge: Deep learning for automated age prediction using panoramic dental X-ray images. *J Forensic Sci*. 2024; 69(6):2069-74.
- [85] Büyükçakır B, Bertels J, Claes P, Vandermeulen D, de Tobel J, Thevissen PW. OPG-based dental age estimation using a data-technical exploration of deep learning techniques. *J Forensic Sci*. 2024; 69(3):919-31.
- [86] Dai X, Liu A, Liu J, Zhan M, Liu Y, Ke W, et al. Machine Learning Supported the Modified Gustafson's Criteria for Dental Age Estimation in Southwest China. *J Imaging Inform Med*. 2024; 37(2):611-9.
- [87] Hamidi O, Afrasiabi M, Namaki M. GADNN: a revolutionary hybrid deep learning neural network for age and sex determination utilizing cone beam computed tomography images of maxillary and frontal sinuses. *BMC Med Res Methodol*. 2024; 24(1):50.
- [88] Murray J, Heng D, Lygate A, Porto L, Abade A, Manica S, et al. Applying artificial intelligence to determination of legal age of majority from radiographic data. *Morphologie*. 2024; 108(360):100723.
- [89] Hundur Hiyari M, Pasic M, Zukic S. Application of Convolutional Neural Networks for Determining Gender and Age in Forensic Dentistry. *Cureus*. 2024; 16(11):e73028.
- [90] Matthijs L, Delande L, De Tobel J, Büyükçakır B, Claes P, Vandermeulen D, et al. Artificial intelli-

- gence and dental age estimation: development and validation of an automated stage allocation technique on all mandibular tooth types in panoramic radiographs. *Int J Legal Med.* 2024; 138(6):2469-79.
- [91] Mohammad N, Ahmad R, Gaus MHA, Kurniawan A, Yusof M. Accuracy of automated forensic dental age estimation lab (F-DentEst Lab) on large Malaysian dataset. *Forensic Sci Int.* 2024; 361:112150.
- [92] Li Z, Xiao N, Nan X, Chen K, Zhao Y, Wang S, et al. Automatic dental age estimation in adolescents via oral panoramic imaging. *Front Dent Med.* 2025; 6:1618246.
- [93] Palmela Pereira C, Carvalho R, Augusto D, Almeida T, Francisco AP, Salvado ESF, et al. Development of artificial intelligence-based algorithms for the process of human identification through dental evidence. *Int J Legal Med.* 2025; 139(4):1835-50.
- [94] Kurniawan A, Taqiasha S, Rachman I, Riyadi TL, Liang M, Pratiwi WAS, et al. From tradition to technology: artificial intelligence advancements in dental age estimation*. *Bulletin of the International Association for Paleodontology.* 2024; 18(2):117-25.
- [95] Upalananda W, Phisutphithayakun C, Assawasuksant P, Tanwattana P, Prasatkaew P. A fully automated deep learning framework for age estimation in adults using periapical radiographs of canine teeth. *Int J Legal Med.* 2025.
- [96] Balel Y, Sağtaş K, Bülbül HN. Development and evaluation of a deep learning-based system for dental age estimation using the demirjian method on panoramic radiographs. *BMC Oral Health.* 2025; 25(1):1172.
- [97] Kim I, Yang S, Choi Y, Kwon H, Lee C, Park W. Automated sex and age estimation from orthopantomograms using deep learning: A comparison with human predictions. *Forensic Sci Int.* 2025; 374:112531.
- [98] Yılmaz E, Görürgöz C, Kış HC, Canger EM, Özataş B. Forensic dental age estimation with deep learning: a modified xception model for panoramic X-Ray images. *Forensic Sci Med Pathol.* 2025.
- [99] Ramamoorthy K, Pillai DS, Yadalam PK, Sitaraman P. Comparing Gradient Boosting and Neural Networks in Predicting Age Based on Coronal Pulp Height from Panoramic Radiographs—A Retrospective Radiographic Study. *Journal of Indian Academy of Oral Medicine and Radiology.* 2025; 37(1):103-8.
- [100] Akkoç B, Arslan A, Kök H. Automatic gender determination from 3D digital maxillary tooth plaster models based on the random forest algorithm and discrete cosine transform. *Comput Methods Programs Biomed.* 2017; 143:59-65.
- [101] Ortiz AG, Costa C, Silva RHA, Biazevic MGH, Michel-Crosato E. Sex estimation: Anatomical references on panoramic radiographs using Machine Learning. *Forensic Imaging.* 2020; 20.
- [102] Patil D, Vineetha R, Vatsa S, Shetty D, Raju A, Naik N, et al. Artificial neural network for gender determination using mandibular morphometric parameters: A comparative retrospective study. *Cogent Engineering.* 2020; 7.
- [103] Esmaeilifard R, Paknahad M, Dokohaki S. Sex classification of first molar teeth in cone beam computed tomography images using data mining. *Forensic Sci Int.* 2021; 318:110633.
- [104] Gamulin O, Škrabić M, Serec K, Par M, Baković M, Krajačić M, et al. Possibility of Human Gender Recognition Using Raman Spectra of Teeth. *Molecules.* 2021; 26(13).
- [105] Franco A, Porto L, Heng D, Murray J, Lygate A, Franco R, et al. Diagnostic performance of convolutional neural networks for dental sexual dimorphism. *Sci Rep.* 2022; 12(1):17279.
- [106] Khazaei M, Mollabashi V, Khotanlou H, Farhadian M. Sex determination from lateral cephalometric radiographs using an automated deep learning convolutional neural network. *Imaging Sci Dent.* 2022; 52(3):239-44.
- [107] Zhou Y, Jiang F, Cheng F, Li J. Detecting representative characteristics of different genders using intraoral photographs: a deep learning model with interpretation of gradient-weighted class activation mapping. *BMC Oral Health.* 2023; 23(1):327.
- [108] Bu WQ, Guo YX, Zhang D, Du SY, Han MQ, Wu ZX, et al. Automatic sex estimation using deep convolutional neural network based on orthopantomogram images. *Forensic Science International.* 2023; 348.

- [109] Ciconelle ACM, da Silva RLB, Kim JH, Rocha BA, Dos Santos DG, Vianna LGR, et al. Deep learning for sex determination: Analyzing over 200,000 panoramic radiographs. *J Forensic Sci.* 2023; 68(6):2057-64.
- [110] Bianchi I, Oliva G, Vitale G, Bellugi B, Bertana G, Focardi M, et al. A Semi-Automatic Method on a Small Italian Sample for Estimating Sex Based on the Shape of the Crown of the Maxillary Posterior Teeth. *Healthcare (Basel).* 2023; 11(6).
- [111] Machado CR, Curi JP, da Costa Moraes CA, Santos LV, Melani RFH, Chilvarquer I, et al. Exploratory analysis of new craniometric measures for the investigation of biological sex using open-access statistical and machine-learning tools on a cone-beam computed tomography sample. *Int J Legal Med.* 2024; 138(6):2595-605.
- [112] Pretorius NE, Anderson N, Forrest AS, Walsh KB. Near infrared spectroscopy for the characterisation of bovine teeth in terms of sex, diet, tooth type and place of origin. *Journal of Near Infrared Spectroscopy.* 2024; 32(6):207-17.
- [113] Pertek H, Kamaşak M, Kotan S, Hatipoğlu FP, Hatipoğlu Ö, Köse TE. Comparison of mandibular morphometric parameters in digital panoramic radiography in gender determination using machine learning. *Oral Radiol.* 2024; 40(3):415-23.
- [114] Noel L, Fat SC, Causey JL, Dong W, Stubblefield J, Szymanski K, et al. Sex classification of 3D skull images using deep neural networks. *Sci Rep.* 2024; 14(1):13707.
- [115] Talebi S, Fallahzadeh H, Jambarsang S, Ezodini Ardakani F. Sex Estimation Based on Tooth Measurements on Panoramic Radiographs with Classical and Machine-Learning Classifiers. *Front Dent.* 2025; 22:14.
- [116] Pereira CP, Correia M, Augusto D, Coutinho F, Salvado Silva F, Santos R. Forensic sex classification by convolutional neural network approach by VGG16 model: accuracy, precision and sensitivity. *Int J Legal Med.* 2025; 139(3):1381-93.
- [117] Prabha PS, Ganesan A, Lakshmi KC, Murugan AJ. Sex determination through analysis of mandibular indices using lateral cephalogram: An Artificial intelligence diagnostics. *Discover Artificial Intelligence.* 2025; 5(1).
- [118] Kristanto R, Junitha K, Suyanto H, Pharmawati M, Yudianto A. Sex Determination Using Confocal Raman Microscope With Chemometric Method From Dental Sample And Confirmation By Amelogenin Gene. *New Armenian Medical Journal.* 2025; 19(1):87-94.
- [119] Chen H, Jain AK. Dental biometrics: alignment and matching of dental radiographs. *IEEE Trans Pattern Anal Mach Intell.* 2005; 27(8):1319-26.
- [120] Chomdej T, Pankaow W, Choychumroon S. Intelligent dental identification system (IDIS) in forensic medicine. *Forensic Sci Int.* 2006; 158(1):27-38.
- [121] Pushparaj V, Gurunathan U, Arumugam B. Victim identification with dental images using texture and morphological operations. *Journal of Electronic Imaging.* 2014; 23(1).
- [122] Miki Y, Muramatsu C, Hayashi T, Zhou X, Hara T, Katsumata A, et al. Classification of teeth in cone-beam CT using deep convolutional neural network. *Comput Biol Med.* 2017; 80:24-9.
- [123] Chen H, Zhang K, Lyu P, Li H, Zhang L, Wu J, et al. A deep learning approach to automatic teeth detection and numbering based on object detection in dental periapical films. *Sci Rep.* 2019; 9(1):3840.
- [124] B S, R N. Transfer Learning Based Automatic Human Identification using Dental Traits- An Aid to Forensic Odontology. *J Forensic Leg Med.* 2020; 76:102066.
- [125] Lai Y, Fan F, Wu Q, Ke W, Liao P, Deng Z, et al. LCANet: Learnable Connected Attention Network for Human Identification Using Dental Images. *IEEE Trans Med Imaging.* 2021; 40(3):905-15.
- [126] Al-Sarem M, Al-Asali M, Alqutaibi AY, Saeed F. Enhanced Tooth Region Detection Using Pre-trained Deep Learning Models. *Int J Environ Res Public Health.* 2022; 19(22).
- [127] Kim YH, Ha EG, Jeon KJ, Lee C, Han SS. A fully automated method of human identification based on dental panoramic radiographs using a convolutional neural network. *Dentomaxillofac Radiol.* 2022; 51(4):20210383.
- [128] Sandhya S, Fernandes R, Sapna S, Rodrigues AP. Comparative analysis of machine learning algorithms for Lip print based person identification. *Evolutionary Intelligence.* 2022; 15(1):743-57.

- [129] Hingad N, Siddeeqh S, Christian FV, Awinashe MV, Singh MP, Agarwal N. Application of Deep Learning Tools in Rugoscopy: Exploring Digital Imaging Study. *Journal of Indian Academy of Oral Medicine and Radiology*. 2023; 35(4):542-6.
- [130] Choi HR, Siadari TS, Ko DY, Kim JE, Huh KH, Yi WJ, et al. Can deep learning identify humans by automatically constructing a database with dental panoramic radiographs? *PLoS One*. 2024; 19(10):e0312537.
- [131] Mikolicz Á, Simon B, Roudgari A, Shahbazi A, Vág J. Human identification via digital palatal scans: a machine learning validation pilot study. *BMC Oral Health*. 2024; 24(1):1381.
- [132] Mouncif H, Kassimi A, Bertin Gardelle T, Tairi H, Riffi J. 3D tooth identification for forensic dentistry using deep learning. *BMC Oral Health*. 2025; 25(1):665.
- [133] Bozkurt MH, Karagol S, Omezli MM. Human identification through panoramic dental radiographs: a novel matching approach. *Knowledge and Information Systems*. 2025; 67(5):4431-58.