



Intraosseous lipoma of the mandible: A case report

Farnoosh Razmara¹, Farzane Mosavat², Forooz Keshani^{3*}

1. Department of Oral and Maxillofacial Surgery, Tehran University of Medical Sciences, Tehran, Iran.

2. Department of Oral and Maxillofacial Radiology, Tehran University of Medical Sciences, Tehran, Iran.

3. Dental Research Center, Department of Oral and Maxillofacial Pathology, Isfahan University of Medical Sciences, Isfahan, Iran.

ARTICLE INFO

Article Type: Case Report

Received: 3 Aug. 2018

Revised: 2 Oct. 2018

Accepted: 10 Nov. 2018

*Corresponding author:

Forooz Keshani

Department of Oral and Maxillofacial Pathology,
department, Isfahan University of Medical Sciences,
Isfahan, Iran.

Tel: +98-913-3088878

Fax: +98-21-84902473

Email: f_keshani@Dnt.mui.ac.ir

ABSTRACT

The lipoma is 5% of benign tumors and 25 to 50% of soft tissue tumors. It most occurs in the upper trunk area, neck and the extremities. But it is rare in the oral and maxillofacial area. It is a benign lesion composed of fat mature adipose tissue that Separated with fibrous septa and surrounded with a thin fibrous capsule. Jaw Intraosseous lipoma is very rare, and its prevalence has been mentioned in articles 1.0%. The case of this manuscript was a 33-year-old woman who referred to an orthodontic specialist with a complaint about the tooth crowding and requesting orthodontic treatment. Based on clinical, radiography and histopathology finding, a diagnosis of intraosseous lipoma of the mandible was made.

Keywords: Benign tumor; Lipoma; Intraosseous.

Introduction

The lipoma is a benign lesion composed of fat mature adipose tissue that Separated with fibrous septa and surrounded with a thin fibrous capsule. It is commonly found in subcutaneous, intramuscular, retroperitoneal regions [1]. It is 5% of benign tumors and 25 to 50% of soft tissue tumors. It most occurs in the upper trunk area, neck and the extremities. But it is rare in the oral and maxillofacial area [2-3]. The presence of this lesion is more common in the spongy bones of the lower extremities than in the facial bones [4]. Based on its association with the bones, they are divided into intra-bone (inter-medullary,

intra-cortical) or bone-attached (parenteral, sub-periosteal) types. Most of these lesions are asymptomatic, and they are randomly seen in the radiography [1]. Jaw Intraosseous lipoma is very rare, and its prevalence has been mentioned in articles 1.0%. Lipoma also is classified according to the amount of tissue in this lesion, in addition to fat. Histopathologically, the most common of which is fibrolipoma, which involves an increase in the amount of fibrosis in the adipose tissue. Others include angiolipoma with more capillaries, Myxolipoma, with a wide range of myxoma changes. The most rare types of lipomas are oste-

olipoma, ossifying lipoma and Lipoma with bone metastases is associated with bone and cartilage changes [5,6]. In this case-report the authors present a new case of intraosseous mandibular lipoma without expansion and pain.

Case Report

A case of this manuscript is a 33-year-old woman who referred to an orthodontic specialist with a complaint about the abnormal teeth and requesting orthodontic treatment. After viewing the lesion in the anterior mandible patient's panoramic radiography by orthodontist, for further investigation, was referred to oral and maxillofacial surgeon. The patient did not have pain and swelling. X-ray CT scan was requested by the surgeon for the patient.

Radiographic Evaluation

Reformatted CBCT study of mandible shows the psudopanoramic and alveolar cross-sectional reconstructed images. The panoramic like image illustrated a solitary unilacular radiolucent lesion with well-defined sclerotic border which has extended between canine teeth and is approximately 17.44 millimeter×15.77 millimeter in diameter (Figure 1). Cross-sectional view revealed a regular bordered lesion without any expansion in buccal and lingual plates. Root displacement can be seen in adjacent teeth but root resorption cannot be detected. According to radiographic appearances the best differential diagnosis are simple bone cyst, keratocystic odontogenic tumor and odontogenic myxoma.

Surgery:

An excisional biopsy of the lesion under bilateral mental block anesthesia was undertaken for precise diagnosis. The mucoperiosteal flap was raised in full thickness and the bone was removed by a Bur surgery. After the area was washed, the flap was sutured with vicryl 3-0 and the specimen was kept in formalin10%, then was sent to the pathology department (Figure 2).

Histopathologic evaluation:

The specimen received in formalin 10% consist of multiple pieces of yellow-gray to brown color soft tissue totally measuring 1×0.5×0.5 centimeter. The histopathology feature of lesion under Olympus optical microscope (Tokyo, Japon) showed variable size mature adipocyte with area of hemorrhage. There is no evidence of epithelial lining indicates cyst presence .The fat cells was without cellular atypia or mitotic figure.

There was no evidence of recurrence of the lesion after one year. Based on clinical, radiography and histopathology finding, a diagnosis of intraosseous lipoma of the mandible was made (Figure 3).


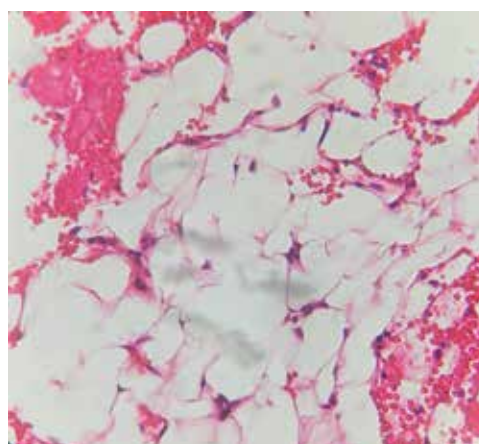


Figure 1. A solitary unilacular radiolucent lesion with well-defined sclerotic border which has extended between canine teeth and is approximately 17.44 millimeter×15.77 millimeter in diameter.

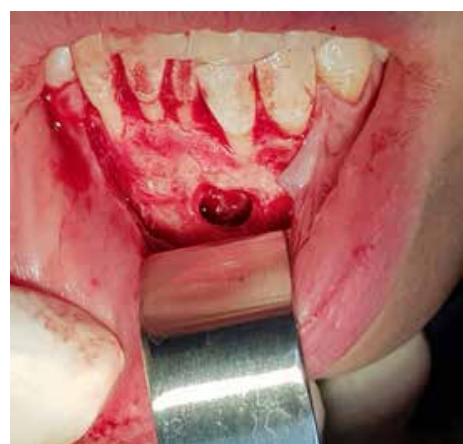

Figure 2. Surgery field in anterior region of mandible.



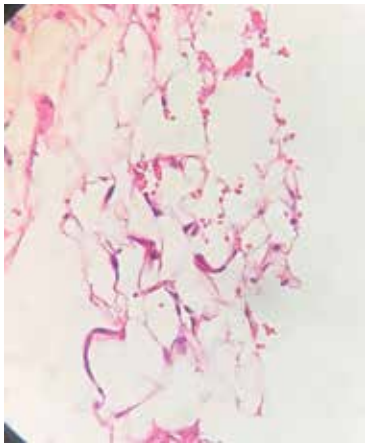


Figure 3. Variable size mature adipocyte without cellular atypia or mitotic figure with area of hemorrhage.

Discussion

Lipoma is the most common mesenchymal tumor and is microscopically divided into different types depending on the type and amount of non-fatty tissues. The most common of which is fibrolipoma, that includes large amounts of connective tissue fibrosis between fat cells. Other types of lipoma are angioliipoma with more capillaries, Myxoliipoma, with a wide range of myxoma changes and myoliipoma with smooth muscle. The formation of cartilage and bone occurs in some soft tissue tumors, rarely it occurs in the lipoma [5,6]. So osteoliipoma is a rare type of lipoma. In 2003, Jones and colleagues evaluated 10 cases of intraoral mesenchymal tumors, of which only one had bone with adipose tissue [7]. According to Fojimura and Enomoto, the use of the mesenchymoma for osteliipoma, which dominantly has fat, is incorrect [3].

There are two theories regarding the pathogenesis of osteoliipoma. Most researchers believe that Faty cells, chondroblasts, and osteoblasts originate from undifferentiated mesenchymal cells. It is assumed that neoplastic changes occur in several undifferentiated cells and then turns to cells that produce fatty cells, cartilage, bone and fibroblast. According to this hypothesis, bone or cartilage in this lesion is due to neoplastic changes. Another hypothesis is that only fat cells are affected by neoplastic changes, and cartilage or bone formation occurs due to fibroblasts metaplasia [3]. The structure and action of some mesenchymal cells can be affected by regional factors such as trauma or systemic problems, such as prolonged ischemia leading to infarction, haemorrhage and calcification [8] Mild continuous trauma and reduced blood supply can cause intralesional metaplasia in lipoma [9]. Most osteoliipomas develop within or near the bone [10]. They must be distinguished from parosteal lymphoma, which is

located directly on the bone cortex and sub periosteal area and causes patologic changes in the adjacent bone [3,9]. Few of the osteoliipomas also occur in soft tissue (Godby). The symptoms of the lipoma in the jaw depend on the position and size of the tumor. If the tumor grows up, it can cause root resorption and even symptoms such as paresthesia [11,2]. Malignant changes may occur in the intraosseous lipoma [12]. Although the origin of intraosseous lipoma is known from the bone marrow adipose tissue, the origin of it are still unknown [2,13,14]. Intraosseous lipoma often occurs in the 4th and 5th decades Buric et al in 2001, reported 13 cases with mandibular intraosseous lipoma [15]. Milgram made the largest case series and reported that men are more likely to have intraosseous lipoma than women with a ratio of 1.6 to 1 [16]. Hart et al Reported that the cause of intrabony lymphoma in the long bones could be due to infarction and nutritional problems [17]. It's hypothesized that in the mandible the obstruction of inferior alveolar artery branches may cause lipoma. In this area, fat cells of the bone marrow tissue may accumulate and develop a lipoma [18]. The present case may also be due to this cause. Another cause of this lesion is trauma [19,2]. But there is no history of trauma in this case. Most of the lipoma occurs in the posterior region of mandible [20,21] and only in three cases, anterior maxilla have been involved.

References

- [1] Rosai J. Rosai and Ackerman's surgical pathology. 9th ed. Edinburgh: Mosby Co; 2004.p.2573.
- [2] Elder DE, Elenitsas R, Johnson BL, Murphy GF. Lever's Histopathology of the skin.9th ed. Philadelphia: Lippincott Williams and Wilkins; 2005. p. 1063-86.
- [3] Fujimura N, Enomoto S. Lipoma of the tongue with cartilaginous change: A case report and review of the literature.J Oral Maxillofac Surg 1992; 50: 1015-17
- [4] Moschopoulos M, Becheanu G, Stamm B. Hypothalamic osteoliipoma of the tuber cinereum. J Cell Mol Med 2006; 10(1): 240-242.
- [5] Bogнар L, Balint K, Bardoczy Z. Symptomatic osteoliipoma of the tuber cinereum.Case report. J Neurosurg 2002 Feb; 96(2):361-3.
- [6] Sinson G, Gennarelli TA, Wells GB. Suprasellar osteoliipoma:case report. Surg Neurol 1998 Nov; 50(5): 457-60.

- [7] Turkoz HK, Varnali Y, Comunoglu C. A case of osteolipoma of the head and neck area. *Kulak Burun Bugaz Ihtis Derg* 2004; 13(3-4):84-6.
- [8] Shuangshoti S, Suwanwela C, Suwanwela N. Congenital osteolipoma of the skull. *Arch Otolaryngol* 1982 Jul; 108(7):454-7.
- [9] Ohno Y, Muraoka M, Ohashi Y, Nakai Y, Wakasa K. Osteolipoma in the parapharyngeal space. *Eur Arch Otorhinolaryngol* 1998; 255:315-17.
- [10] Godby AF, Drez PB, Field JL. Sublingual lipoma with ectopic bone formation. Report of a case. *Oral Surg Oral Med Oral Pathol* 1961; 14:625.
- [11] Dutescu N, Georgescu L, Hary M. Lipoma of submandibular space with osseous metaplasia. Report of a case. *Oral Surg Oral Med Oral Pathol* 1973; 35:611-15.
- [12] Piattelli A, Fioroni M, Lezzi G, Rubini C. Osteolipoma of the tongue. *Oral Oncology* 2001; 37(5):468-70.
- [13] McAndrew PG, Greenspan JS. Lipoma of lip with cartilage formation. *Br Dent J* 1976; 140:239.
- [14] Castilho RM, Squarize CH, Nunes FD, Pinto DS. Osteolipoma: a rare lesion in the oral cavity.
- [15] Br J Oral Maxillofac Surg 2004; 42(4):363-64. Buric N, Krasic D, Visnjic M, Katic V. Intraosseous mandibular lipoma: a case report and 1. review of the literature. *J Oral Maxillofac Surg* 2001; 59:1367-71.
- [16] Hughes Cl. Intraoral lipoma with osseous metaplasia. *Oral Surg Oral Med Oral Pathol* 1966; 21: 576.
- [17] Allard RHB, Van der Kwast WAM. Van der Waal I. Oral lipomas with osseous and chondrous metaplasia. Report of two cases. *J Oral Pathol* 1982; 11:18.
- [18] Jones AC, Trochesset D, Freedman PD. Intraoral benign mesenchymoma: A report of 10 cases and review of the literature. *Oral Surg Oral Med Oral Pathol* 2003; 95(1):67-76.
- [19] Enzinger FW, Weiss SW. *Soft tissue tumors*. 4th ed. Louis: Mosby; 2001. p.574-81.
- [20] Val-Bernal JE, Val D, Garijo MF, Vega A, Gonzalez-Vela MC. Subcutaneous ossifying lipoma: case report and review of the literature. *J Cutan Pathol* 2007 Jun.
- [21] Yabe Y, Kumagai J, Koizumi N, Kavamura M, Ono S, Hatori M. Osteolipoma arising adjacent to the sternoclavicular joint. A case report. *Upsala J Med Sci* 2006; 111(2):257-62.

Please cite this paper as:

Razmara F, Mosavat F, Keshani F; Intraosseous lipoma of the mandible: A case report. *J Craniomax Res* 2019; 6(1): 51-54