



## Panfacial fractures management, a report of surgical treatment sequence in three cases: A case series study

Mehrnoush Momeni Rouchi<sup>1</sup>, Sayna Nezaminia<sup>2\*</sup>, Narges Hajiani<sup>2</sup>

1. Department of Oral and Maxillofacial Surgery, Tehran University of Medical Sciences, Tehran, Iran.

2. Department of Oral and Maxillofacial Surgery, Sina Hospital, Tehran University of Medical Sciences, Tehran, Iran.

### ARTICLE INFO

#### Article Type: Case Report

Received: 23 Sep. 2022

Revised: 11 Oct. 2022

Accepted: 10 Dec. 2022

\*Corresponding author:

Sayna Nezaminia

Department of Oral and Maxillofacial Surgery, Sina Hospital, Tehran University of Medical Sciences, Tehran, Iran.

Tel: +98-937-2638248

Fax: +98-21-84902473

Email: sayna.nezaminia@gmail.com

### ABSTRACT

Multiple facial fractures, which involve the upper, middle, and lower thirds of the face, are called Panfacial fractures, and their management is one of the biggest challenges in the field of maxillofacial surgery. The proximity of maxillofacial skeleton to important sensory or vital structures such as the visual, olfactory, masticatory and respiratory systems and intracranial components in addition to negative effects on esthetic aspects of the face have doubled the intricacy. Small or thin fractured segments that are difficult to find and stabilize make management of pan facial fractures different from anywhere else in the body. One major challenge is to find the best pattern and sequence of treatment. There are different concepts, depending on the surgeon's experience and the pattern of fracture. This study reports three patients with the diagnosis of pan facial fractures. A 54-year-old woman, an 18-year-old and a 14-year-old man that were all victims of road traffic injuries (MVA). Conventional open reduction and internal fixation methods have been used and favorable results have been obtained in follow-up periods.

**Keywords:** Pan facial fracture; Midface fracture; Maxillofacial trauma.

### Introduction

Pan facial fracture includes the multiple fractures at upper, middle and lower facial thirds in which the most common regions that are involved along with the mandible, are the maxilla, the zygomatico-maxillary complex and the naso-ethmoido-orbital region [1,2]. Management of pan facial fracture is very challenging and complicated for several reasons. The number of fracture

segments is large and the dimensions of each segment are small. Often, after huge trauma, Reference point (the intact area around the fractured part as the starting point for fixation) and Confirming points (points which determine and ascertain the tridimensional orientation of midface especially in ZMC) are lost and reconstruction is difficult in situations where the facial bony framework is lost [3].

Copyright © 2023 Tehran University of Medical Sciences.

This work is licensed under a Creative Commons Attribution-NonCommercial 4.0 International license (<https://creativecommons.org/licenses/by-nc/4.0/>). Non-commercial uses of the work are permitted, provided the original work is properly cited.

At the same time, the soft tissue in the maxillofacial area has its own issue and loss of soft tissue in some parts will be irreparable. It is not easy to return esthetics to patients. Functions such as mouth opening, mastication, normal ocular movement without restriction may be affected and need to be restored with great care and obsession. A very important criterion is always occlusion, and treatment which will not eliminate malocclusion or lead to malocclusion itself is not optimal. Pan facial fractures are 4-19% of all facial fractures [4]. The higher the impact on the face, the greater the severity of the fracture and the fragmentation of the fractured bones. That's why high energy injuries such as road traffic accidents and gunshot are the most common causes of pan facial fractures.

The concept of "Facial pillars and buttresses" is emphasized in restoration of the facial skeleton. In association with the sequence of treatment, we have the concept of "Top-to-bottom" sequence, meaning that fixation of segments begins with frontal bone, followed by the midface complex then, using the upper jaw frame as a template, the mandible is finally restored. Another concept is fixation the largest and strongest facial bone, the mandible as the first step in order to restore the posterior facial height, and then fixation at other facial unites as the concept of "Bottom-to-top", which is most commonly used in management nowadays [5].

## Case Presentation

### Case 1

A 54-years-old woman is the first case of Panfacial fracture. due to motor vehicle accident (MVA) one week before operation. The patient's fractures were as follows:

LT. Le fort 1 fracture, RT. Le fort 2 fracture. , bilateral Le fort 3 fracture. , Bilateral type 2 NOE fracture. , nasal bone fracture, Mandibular symphysis fracture. And fracture of skull base with no clinical manifestations or limitation in our treatment. Under general anesthesia with submental intubation, we used these surgical approaches:

Bicoronal flap, Bilateral transconjunctival approach, LT Lynch approach, the previous laceration at right nasal dorsum, maxillary and mandibular vestibular approaches. Generally, in treatment of pan-facial fractures including mandibular fractures, the first area to be reduced and fixed will be mandible; Since the patient did not have the complete dentition, we had to

obey the anatomical reduction. That's why through the vestibular approach and exposure of fracture at Symphysis, with the aid of reduction forceps we completed the reduction in order not to prevent the flaring of segments at lingual aspect. After fixation of the mandibular fracture segments with two miniplates, we started to do ORIF the fracture segments due to the concept of "Top to Bottom" and "Outside to Inside". through a mandibular vestibular incision we reached the mandible symphysis fracture (Figure 2). In spite of a laceration in the right lateral orbito-temporal area, we preferred to chose the classical approaches; i.e. Bicoronal and Transconjunctival approaches in order to have better exposure. But since this laceration was badly sutured, we opened the suture and refreshed the edges and re-sutured properly (Figure 3). The left Frontozygomatic suture (ZFS) had a major displacement (Figure 4). Our reference in the correct reduction of the ZFS is the position of the ZSS or Zygomaticosphenoid suture. To ensure correct and complete reduction of the ZFS, the lateral orbital wall should be completely exposed not only temporally/externally but also internally from the orbital cavity in order to check out the Zygomaticosphenoid suture as Confirming point. We started to fix horizontal facial pillars from outside to inside. The first horizontal pillar is left zygomatic arch, which was broken into several parts (Figure 1). Which has been reduced and fixed with along MICROPLATE in order to prevent postoperative "Pseudozygomatic arch bowing" due to the volume of MINIPLATE (Figure 5,a).

In the right zygomatic arch there was a clear proximal fracture line and a suspicious distal line that had not been previously detected in the CT scan. In order to detect probable green stick fractures we grasped the apparently sound segment of zygomatic arch and moved it firmly to localize and detect the fracture to prevent postoperative Zygomatic arch bowing by opening the fracture line in this area. Since there was only 2 fracture lines on right zygomatic arch and the fracture lines were far apart each other, we fixed each fracture line with an individual three-hole mini plate. (Figure 5-b) in order to keep the major part of the arch out of plate. Thereafter both zygomatic bodies' comminuted fractures were reduced and fixed (Figure 5-c). In this area, we have the second confirming point: The Root of Zygomatic Arch. Inferior orbital rim is the second horizontal pillar. There were three broken pieces on the right and two on the left inferior orbital rims. We fixed each side with a low-profile rim plate (Figure 6). So that the plate cannot be palpated under the thin skin. On the way from the top to the bottom and from the

outside to the inside, now we have to manage NOE fracture. Due to type II of this fracture we were not worried about the medial canthal tendon. The only important thing is that even the smallest pieces must be found one by one and returned to their original place, and larger pieces with plates and smaller pieces with sutures must be fixed (Figure 7). Then we managed the third confirming point, Zygomatic Buttress, which is very important because it confirms the correct position of the zygomatic complex in both the medio-lateral and superior-inferior dimensions. After proper reduction, we fixed the zygomatic buttresses in both buttresses and pyriform rims. Finally we Performed suspension sutures for the Zygomaticus major M.s and frost sutures and applied external and internal nasal splints. By comparing the pre- and post-operative CT scans, it is clear that the orbital floor is well elevated (Figure 9-a). The ZSS,s are in correct place (Figure 9-b). There is no zygomatic arch bowing (Figure 9-c) and no flaring or opening at the lingual surface of the mandible is present (Figure 9-d). 8 months after the operation, the patient's profile shows very satisfying results the only problem is the scar due to Linch incision on the left side; a common complication in this approach (Figure10).

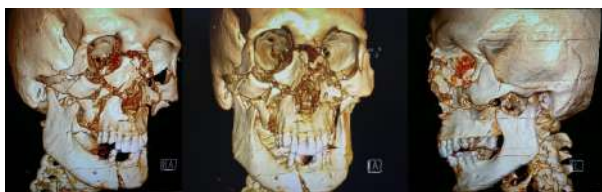

Figure 1. Pre-op three-dimensional reconstructed CT scan; The fractures are clearly comminuted.

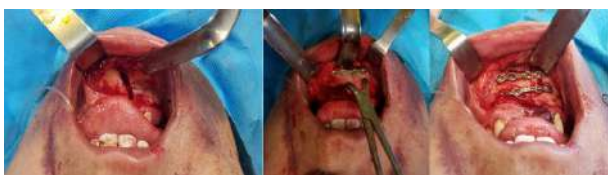

Figure 2. ORIF of mandibular symphysis Fx through a vestibular access.

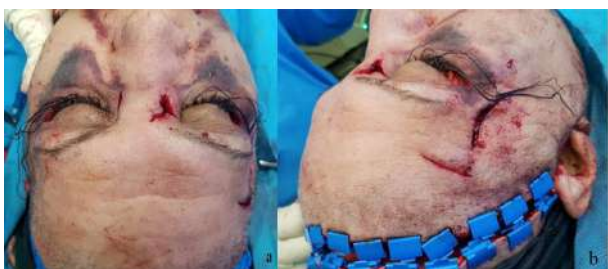

Figure 3. a) Lynch incision at left side and nasal skin laceration at right side were used to approach NOE complex. b) bicornal flap and the temporal laceration are seen.

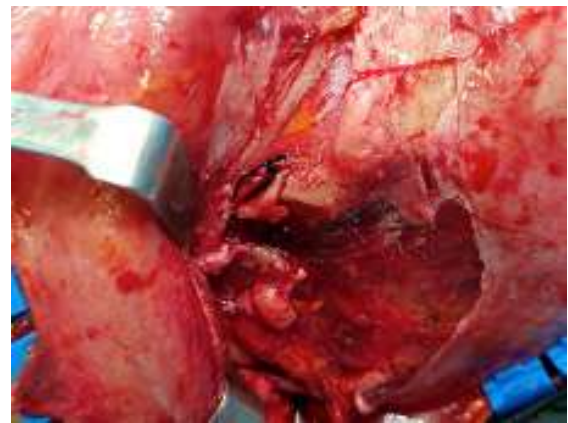


Figure 4. Displacement of zygomaticofrontal suture.

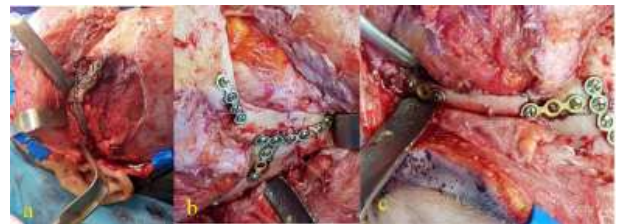

Figure 5. a) ORIF of left zygomatic arch by one long micro plate. B) ORIF of right zygomatic arch by 2 mini plates c) ORIF of zygomatic body.

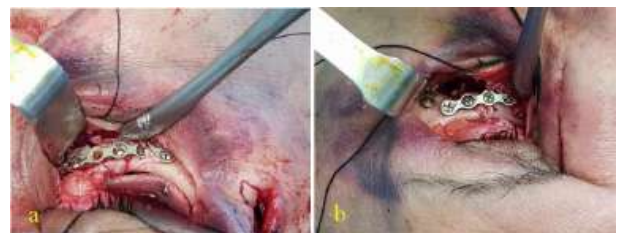

Figure 6. A) ORIF of right inferior orbital rim. The orbital floor med pore is also seen B) ORIF of left inferior orbital rim.

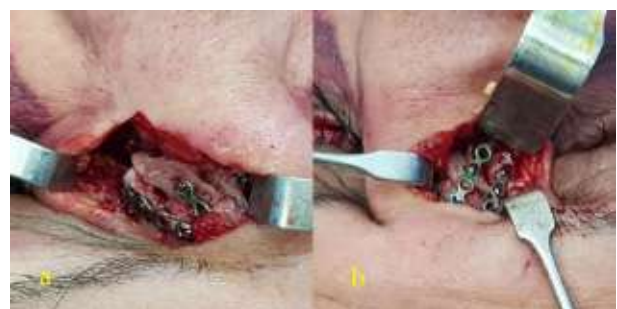

Figure 7. A) ORIF of left NOE complex fracture B) ORIF of right NOE complex fracture.

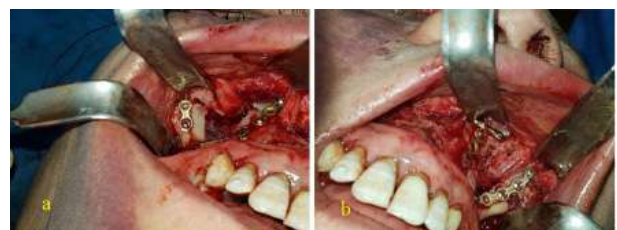

Figure 8. ORIF of both zygomatic buttresses and pyriform rim.



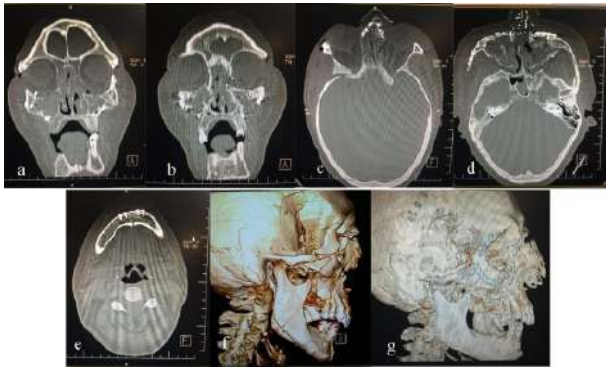


Figure 9. Comparison of pre-op and post-op CT scan cuts.

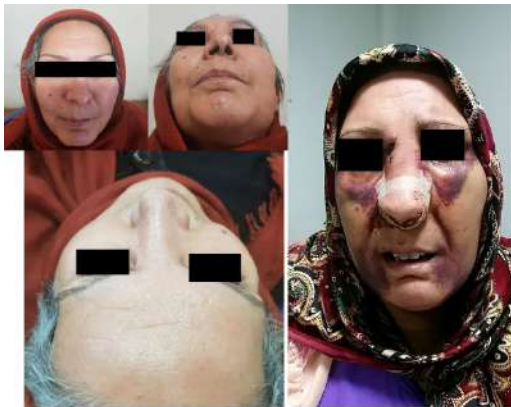

Figure 10. Post-operative photograph: A good comparison with the preoperative view of the patient.

### Case 2

A 17-years-old male patient was referred to OMFS ward of Sina Hospital with diagnosis of pan facial fracture due to motor cycle accident (MCA) 5 months ago (Figure 11) and a history of admission in neurosurgery Intensive Care Unit in this period of time.

The patient made three chief complaints:

- 1) Ptosis of left upper eyelid due to facial nerve paralysis.
- 2) Left malar depression.
- 3) A huge scar from the corner of the mouth to the tragus.
- 4) Uneven lip corners (due to nerve paresis, scar and parasymphyseal Fx.).

Clinical examination and radiographic analysis revealed:

- Left orbital roof fracture with encephalocele (Figure 12).
- Left zygomatico maxillary complex fracture. (Lt. ZMC Fx.).
- Left Posttraumatic enophthalmous and hypoglobus as a result of increase in orbital volume (Figure 12).

- Increased facial width caused by zygomatic arch fracture and its lateral displacement.
  - Malunion of Mandibular parasymphysis fracture and resulted malocclusion.
  - A maxillary tooth had been pushed and become impacted into maxillary sinus.
  - Posttraumatic left maxillary dentolaveolar defect.
  - Left side Hypertrophic scars of cheek and lower lip.
- It is obvious that the priority was with treatment of encephalocele.

Access to the frontal lobe and cranium was made through the bicoronal approach and craniotomy. Frontal lobe was retracted until we reached the orbital roof defect. That part of the frontal lobe that had been herniated to orbit for 5 months, had become atrophic and fibrotic, so that as far as possible the brain tissue was returned to the cranium and the remainder was separated by a bipolar cotter. Then the bone fragment that had fallen into orbit was returned to its place and fixed with a plate so the orbital roof became aligned (Figure 13).

After repositioning of orbital floor, a great distance between the orbital roof and the globe became apparent, so that we could move the orbital floor and the globe upwards into their correct location. The following photos show the problem list of patient at ZMC: In the second phase of surgery 1 week post-operatively and after submental intubation, exposure was provided by:

- Coronal approach.
- Transconjunctival (retroseptal) approach with lateral canthotomy.
- Maxillary vestibular approach.

At first, via coronal approach, fronto zygomatic suture was reduced and fixed (Figure 17a). Simultaneously lateral orbital wall was completely exposed in order to check out zygomatico sphenoid suture as the first confirming point in order to be sure that the reduction of ZFS and mediolateral orientation of ZMC is accurate. Then the fracture line at root of zygomatic arch was exposed and integrity of this horizontal pillar was restored with plate (Figure 17b). After that, inferior orbital rim, the second horizontal pillar, was reduced and fix by a low profile titanium rim plate (Figure 17c). Thereafter we exposed and reconstructed the orbital floor by titanium mesh after repositioning the entire orbital frame at 360 degrees (Figure 17c). Finally zy-

gomatic buttress was fixed by mini plates (Figure 17d). Below in figure 18 you can compare the pre- and post-operative CT-Scans of the patient and see the clinical view of the patient at the end of surgery. After the midface, the mandible fracture was operated, which had a severe bone step (Figure 19 a). Since maxilla was intact in this case, there is no need to operate the mandible at first step. In other words, it seemed that we two separate fracture. That is why we preferred to operate the ZMC complex and then mandible, because the fracture at midface was more challenging and time consuming. In spite to routine, we obeyed the concept of “UP- bottom”. In CT scan, there were two things to note:

- 1) The bony callus formed on the lingual side of the mandible fracture (Figure 19 b).
- 2) The sagittal direction of fracture that caused our osteotomy to be sagittal as well, which is a difficult job for a 5 months old fracture (Figure 19 c).

Through Mand. vesibular incision the fracture was exposed. Osteotomy was performed in sagittal pattern for adopting lateral and inferiorly displaced proximal segment back to correct occlusion. Bone-reducing forceps has been used to reduce the segments and provide inter fragmentary compression, while adapting the bone plate. We could not use functional reduction because there was no reliable occlusal reference due to post traumatic multiple teeth loss at upper jaw. Therefore, we reduced mandibular segments anatomically. For fixation at first, we applied the larger reconstruction plate superiorly and after that, the miniplate inferiorly at the inferior mandibular border. In this case, when we wanted to fix the inferior plate at first step and with the larger plate, the fracture line had the tendency to open. The best method is w-plasty. It is important that you keep the scar revision path parallel to the RSTLs. The internal angles of the w-plasty incisions must be 60 degrees.

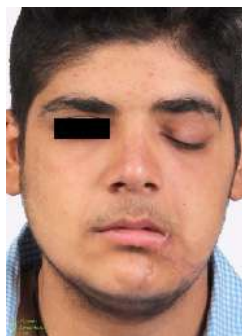

Figure 11. Face of case 2.

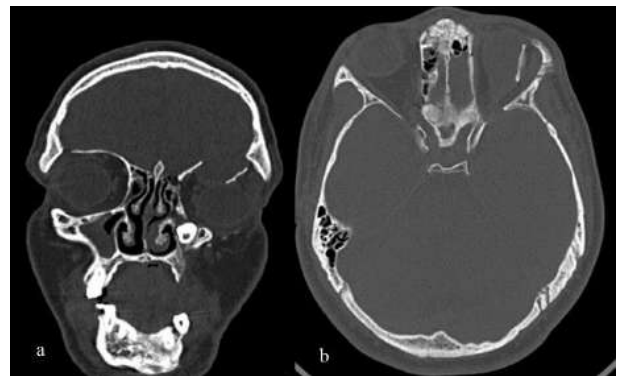


Figure 12. a) The encephalocele and herniation of frontal lobe of brain into the orbit due to orbital roof fracture and the hypophthalmos as a result of concurrent orbital floor fracture. , b) a bony fragment from broken orbital roof had fallen into the orbit.

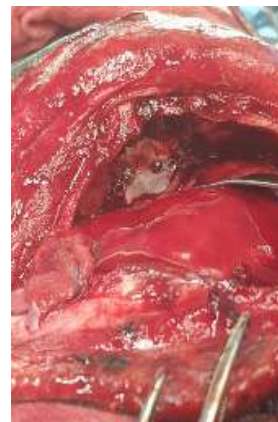

Figure 13. Alignment of fractured segment of orbital floor and fixation with mini plate.

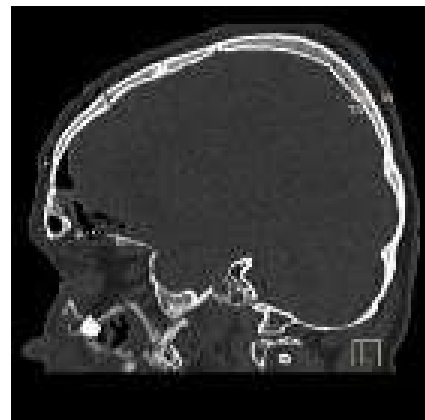
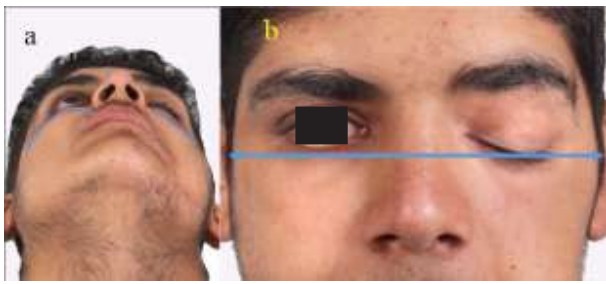
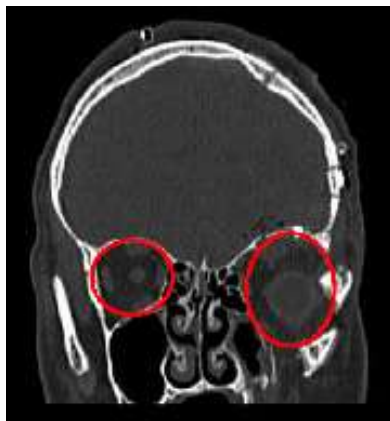


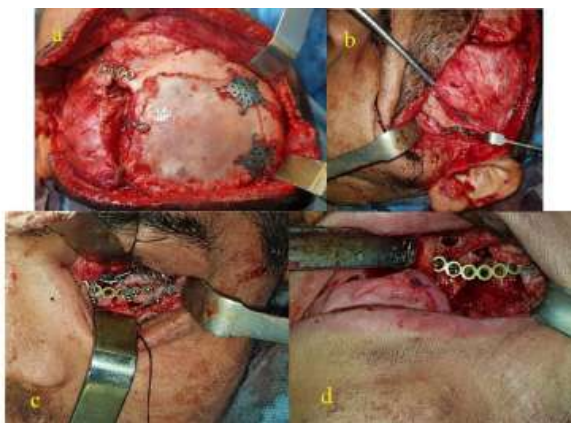Figure 14. Sagittal view of post-surgical CT scan, after craniotomy and orbital roof re-alignment.



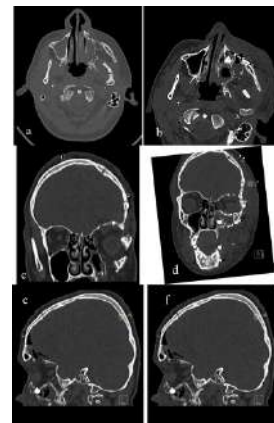
**Figure 15.** a) the patient presented with Malar region depression due to zygomaticomaxillary complex Fx. , b) increased facial width is caused by zygomatic arch Fx. and lateral displacement. Also in this picture, despite the ptosis, hypo globous can be diagnosed by comparison of the right and left upper lash lines.



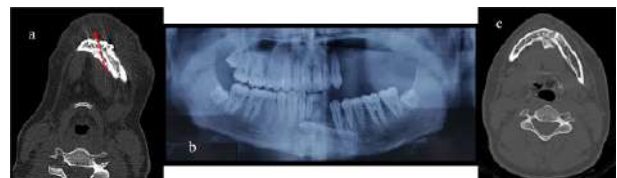**Figure 16.** Coronal CT scan views of lateral wall and orbital floor fracture, increase of the orbital volume is obvious.



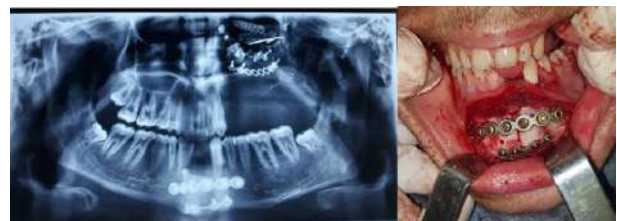**Figure 17.** a) through the coronal approach, fronto zygomatic suture was reduced and fixed, b) Surgical exposure of Zygomatic arc root through coronal incision. Zygomatic arc root alignment and fixation with microplate. c) Surgical exposure of inferior orbital rim and orbital floor by Tranconjunctival incision. Orbital floor reconstruction with titanium mesh device. d) Surgical exposure of zygomatico maxillary buttress.



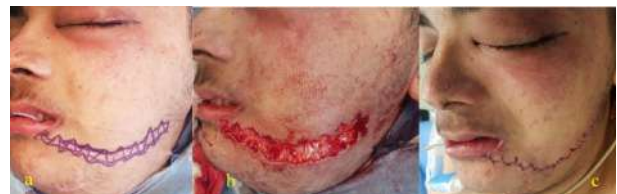**Figure 18.** Post operative clinical appearance of corrected malar projection and eyelid fullness and pre-op and post-op CT scan cuts comparison. a and b) axial view show anterior maxillary sinus wall changes. c and d) coronal view. e and f) sagittal view, the orbital floor alignment has reached quite as far as the orbital apex.



**Figure 19.** Mandible fracture. A) panoramic view shows major bone displacement. B) Axial CT scan views of mandibular fracture callus formation and inferior and laterally displacement of fractured segment. C) Axial view of Oblique osteotomy of mandibular parasymphysis.



**Figure 20.** Mandibular open reduction and internal fixation through vestibular approach. The last phase of surgery was the scar revision.



**Figure 21.** Scar revision surgery by w-plasty technique. A) W-plasty performed by designing repeating triangular flaps roughly parallel to RSTLs on either side of scar. B) Scar excised and W-plasty completed. C) Wound closure with interrupted sutures.



### CASE 3

An 18-years-old male patient has been referred to OMFS ward of Sina hospital 2.5 months after the trauma due to motor vehicle accident (MVA), with the following problem list:

- Frontal & supra orbital rim depression.
- Minimally displaced ZMC Fx. that could be ignored due to mild clinical manifestations.
- Dystopia & Diplopia.
- Tearing in dura matter & fracture of posterior wall of frontal sinus.

Because of intracranial injury, the surgery was performed as a team work in collaboration with the neurosurgery team. It is important to note that diplopia and distopia are not always related to the disruption of the orbital floor, the sagging of the orbital roof can be the cause, so first we must reposition the orbital roof. Figure 24; it is very clear that the fractured bone is completely comminuted and depressed, and there is also a low-displacement fracture in the ZMC that we could ignore. In these views, depression is much more obvious. All fracture lines should always be marked on pre-operative CT scan cuts. In this case for example, at supra orbital rim, in addition to the two clear fracture lines, there is a non-displaced linear fracture between them that we should be aware of preoperatively, because it may have displacement during operation (Figure 25).

Under general anesthesia (submental intubation) through Hemicoronal and subciliary approaches, we implemented this treatment plan step by step:

- Removal of four fractured pieces from the frontal area and frontozygomatic suture.
- Curettage of frontal sinus.
- Repair of dura matter & coverage of frontal sinus.
- ORIF of frontal bone, zygomaticosphenoid suture & adding titanium mesh to cover this area.
- Osteotomy of zygomatic arch.
- Int. orbital reconstruction (Figure 26).

We first cleaned the broken pieces from the bone callus and then returned them to their correct place and fixed them with microplates. (Figure 27-a). In old fractures, after reduction, we always have remained gap between the fracture fragments, especially after osteotomy and removal of calli. In addition, we have some

bone resorption after old traumas, therefore we had still bone depression. So, it is recommended to cover the area with titanium mesh (Figure 27-b). The rough surface of mesh should be completely covered with pericranium (Figure 27-c). In next step, we exposed the orbital floor through a subciliary incision, and re-constructed the orbital floor by titanium mesh and an overlying medpore (Figure 28). At the end of the operation and according to the photos everything has been corrected and returned to its original place. The patient has no dystopia. The projection of the two globes is exactly the same (Figure 29). The postoperative complication that occurred was “retrobulbar hemorrhagia”. After 24 hours, the patient gradually developed severe proptosis (Figure 30). Other symptoms included severe pain in the retrobulbar area and dilated pupils and decreased visual acuity. CT scan proved this complication (Figure 30). So we need to perform a lateral canthotomy and cantholysis immediately. Fortunately, all the signs and symptoms were resolved.

After 6 months the overall condition was satisfying but the remaining problem list was:

- Remained depression on the right temporal area & supra orbital rim.
- Vertical dystopia & unlevelled globes' axis: the right globe was positioned a little bit higher.

So we planned a second surgery for removal of titanium mesh, reshaping & replacement of orbital floor porex through transconjunctival approach. Also the depression of temporal fossa and irregularity of supra orbital rim was filled with dermis fat graft.



Figure 22. Face of case 3.

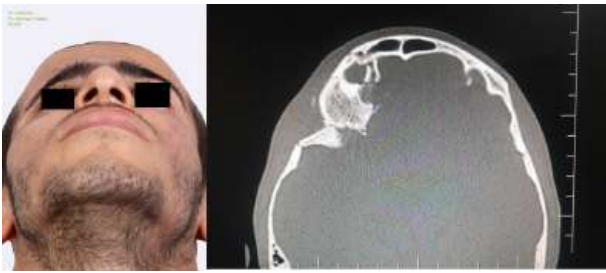


Figure 23. Depression of the supra orbital rim area is very clear in this view.

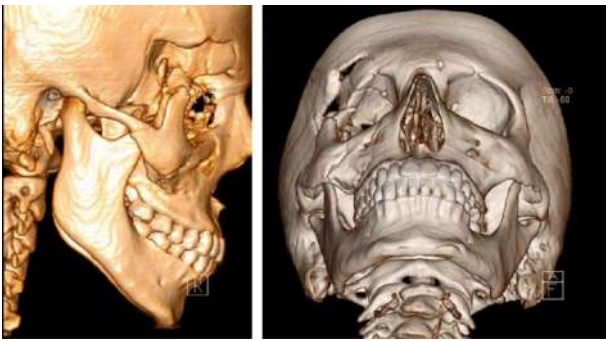


Figure 24. 3-D CT scan of ZMC.

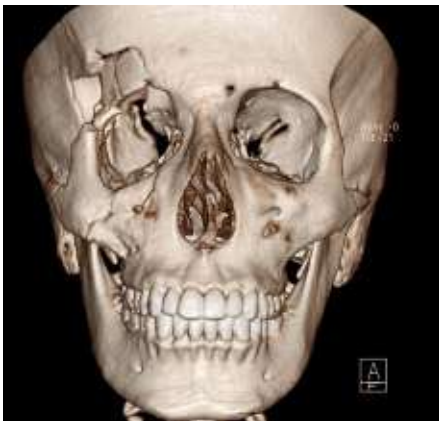

Figure 25. All fracture lines should be marked and noticed before operating.

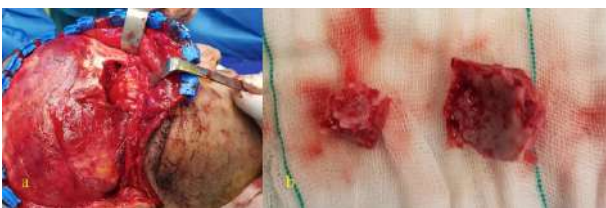

Figure 26. A) Exposure of supra orbital rim vis hemi-coronal flap. B) Bone fragments were removed to access the rupture of dura matter.

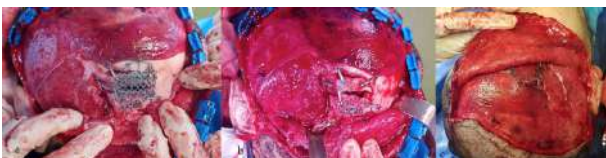

Figure 27. A) Orif of frontal and supra orbital rim, B) titanum mesh covering the fracture area, C) pericranium covering the titanum mesh.

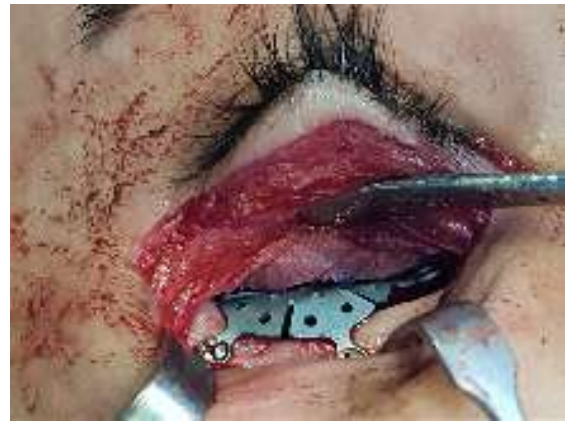

Figure 28. Internal orbital reconstruction by titanum plate and medpore.

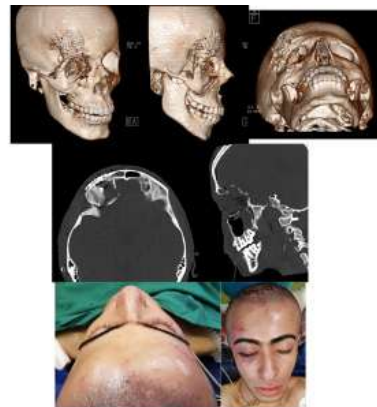


Figure 29. Final photos at the end of surgery and post-operative CT scan.

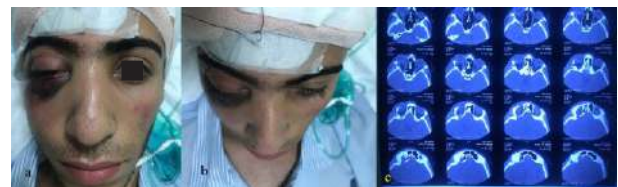

Figure 30. A,B) proptosis is one of clinical manifestation of retrobulbar hemorrhage. C) retrobulbar blood accumulation is seen in post-operative orbital CT scan.

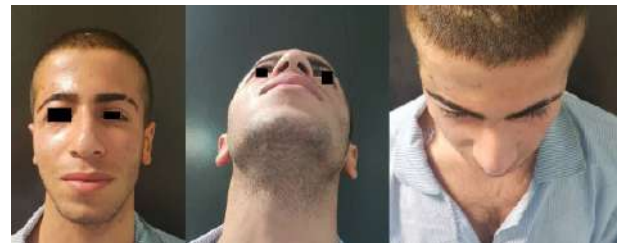


Figure 31. After the second surgery vertical dystopia and the remained temporal depression are gone.



## Discussion

Pan facial fractures involve all thirds of the face at the same time. According to Markowitz, if it has spread to the frontal and palato-alveolar unite, it is called extended pan facial fracture. In treatment of pan facial fractures, the main goals are regaining of anatomy, rehabilitation of function, restoring of three-dimensional facial contours and avoiding the creation of new or remaining postoperative deformity [6,7]. Usually pan facial fractures are due to a multiple trauma, so it is necessary to have a systematic examinations and Interdisciplinary consultations to detect possible associated problems Bilateral pan facial fractures usually occur following MVA [8].

Submental intubation is usually considered as the intubation technique of choice in these cases, with which there is the minimum interfering with intraoral procedures, also examination of occlusal relationships, reduction and manipulation of NOE and nasal fractures, internal and external nasal splint placement and checking out the symmetry of the malar protrusion intraoperatively would be possible. The importance of horizontal and vertical buttresses in strength of facial contours and transferring masticatory forces to the skull base is obvious. In treatment sequencing, there are two main concepts: “Bottom-up, Inside-out” and vice versa [6]. Some surgeons use the concept of “Bottom-up and Inside-out” as the most useful arrangement [4,9]. But it can be modified depending on the pattern of fracture and experience of the surgeon. The concept applied in our cases is as follows: if there is a mandibular fracture, first the mandible—as the strongest facial bone— has to be reduced and fixed, with which posterior height of the face can be gained. After that, all fractures are reduced and fixed “Top-to-bottom and Outside-in”. In addition, our criterion for sequence of fixation in midface is based on Reference point? Depending on which point around the fracture area has maintained intact, we apply the “Inside-out” and sometimes or the “Outside-in”. Our favorite approach in most pan facial fractures is Coronal; An ideal approach is the one that is minimally invasive and uses with the least negative esthetic side effect, but at the same time provides adequate access and An inexperienced surgeon may think that smaller access has more desirable cosmetic outcomes, but insufficient access through a small incision specially in pan facial cases leads to malpractice. In most cases, the scar in coronal incision can be hidden behind the hairline.

## Conclusion

The best postoperative outcomes are achieved when surgery is performed as soon as possible after the trauma. Although the patient with pan facial fracture must always be aware of the necessity of a secondary corrective surgery. The ideal intubation technique for these patients is usually Sub mental. We need to use some approaches that give the best access and the least aesthetic negative effect. It is important to pay attention to horizontal and vertical buttress and “Confirming and Reference points”, and the best operation sequencing is the one that reconstructs Occlusal relationship and horizontal and vertical facial proportions, rehabilitation of three-dimensional facial contour and restoring functions such as mastication, ocular movement and mouth opening. The surgeon’s experience always plays the key role in this decision.

## Conflict of Interest

There is no conflict of interest to declare.

## References

- [1] He D, Zhang Y, Ellis III E. Panfacial fractures: analysis of 33 cases treated late. *Journal of Oral and Maxillofacial Surgery*. 2007; 65(12):2459-65.
- [2] Miloro M, Ghali G, Larsen P, Waite P, Of PsP. *Oral And Maxillofacial Surgery*. BC Decker, Ontario; 2004.
- [3] Singh A, Singh VK, Tiwari R, Thanvi G. Management of Panfacial Trauma: A Case Report.
- [4] Yang R, Zhang C, Liu Y, Li Z, Li Z. Why should we start from mandibular fractures in the treatment of panfacial fractures? *Journal of oral and maxillofacial surgery*. 2012; 70(6):1386-92.
- [5] Markowitz BL, Manson P. Panfacial fractures: organization of treatment. *Clinics in plastic surgery*. 1989; 16(1):105-14.
- [6] Miloro M, Ghalli G, Larsen PE, Waite PD, editors. *Textbook of Peterson’s principles of Oral & Maxillofacial Surgery: Vol-1*.
- [7] Pau M, Reinbacher KE, Feichtinger M, Navysany K, Kärcher H. The mandibular symphysis as a starting point for the occlusal-level reconstruction of panfacial fractures with bicondylar fractures and interruption of the maxillary and mandibular arches: report of two cases. *Journal of Cranio-Maxillofacial Surgery*. 2014; 42(4):e51-e6.

- [8] Obuekwe O, Ojo MA, Akpata O, Etetafia M. Maxillofacial trauma due to road traffic accidents in Benin City, Nigeria: a prospective study. *Annals of African Medicine*. 2003; 2(2):58-63.
- [9] Sharma S, Dhanasekaran V. Surgical approaches and management of panfacial trauma: a case report. *Journal of clinical and diagnostic research: JCDR*. 2015; 9(8):ZD13.

*Please cite this paper as:*

Rouchi Mehrnoush M, Nezaminia S, Hajiani N. Panfacial fractures management, a report of surgical treatment sequence in three cases: A case series study. *J Craniomax Res* 2023; 10(1): 36-45