



Rehabilitation of edentulous patient using endosteal and subperiosteal implants: A case report

Fulya Gulener ^{1*}, Mustafa Mert Acikgoz ², Deger Ongul ³, Gulsum Ak ²

1. Institute of Health Sciences, Prosthodontics PhD Program, Istanbul University, Istanbul, Turkiye.

2. Department of Oral and Maxillofacial Surgery, Faculty of Dentistry, Istanbul University, Istanbul, Turkiye.

3. Department of Prosthodontics, Faculty of Dentistry, Istanbul University, Istanbul, Turkiye.

ARTICLE INFO

Article Type: Case Report

Received: 9 Aug. 2022

Revised: 10 Oct. 2022

Accepted: 10 Dec. 2022

*Corresponding author:

Fulya Gulener

Institute of Health Sciences, Prosthodontics PhD Program, Istanbul University, Istanbul, Turkiye.

Tel: 00905373619594

Fax: 00902124400000

Email: fulya.acikgoz@Ogr.iu.edu.tr

ABSTRACT

Introduction: Endosteal implants may be insufficient in treating complete edentulism in severe bone loss, such as advanced bone resorption, trauma, infection, intraoral pathologies, and traumatic tooth extractions. With the developing technology, in cases where bone quality and quantity are inadequate, treatment with custom-made subperiosteal implants also emerges as an alternative.

Case: This case report examined the procedural steps and the six-month post-operative period while evaluating our edentulous patient who rehabilitated using endosteal and custom-made subperiosteal implants.

Results: No resorption or mobility of the implants was detected in the 6th-month post-operative control of our complete edentulous case, which was rehabilitated using traditionally used intra-bone implants in the maxilla and subperiosteal implants in the mandible.

Conclusion: One of the essential advantages of the subperiosteal implant system is that it provides fixed prosthetic treatment, especially in jaws with advanced bone atrophy. Correct case selection and appropriate surgical and prosthetic treatment will increase success.

Keywords: Dental implantation; Endosteal; Mouth rehabilitation; Subperiosteal.

Introduction

Endosteal implants are widely used in the treatment of complete edentulism. Conditions like advanced bone resorption and poor bone quality may preclude traditional implant applications. In such cases, advanced surgical methods such as sinus lifting, zygoma implants, and guided bone regeneration can be used in

the maxilla. In contrast, short implants, alveolar crest expansion, nerve lateralization, and block graft applications can be preferred in the mandible [1-4]. The new generation of custom-made subperiosteal implants has become more common in recent years and appears as an alternative to all these advanced surgical methods [5]. Subperi-

implants are custom-made implants covered with a full-thickness mucoperiosteal flap placed under the periosteum, in contact with the bone, and fixed to the bone with fixation screws [6]. Personally designed subperiosteal implants produced using additive manufacturing technology. They can be applied to the patient in four stages: design, production, surgery, and prosthetic procedures. Before proceeding to the design phase, the tomography from the patient with the large FOV area is transferred to the design program in DICOM format. After the patient is modeled in 3D using the obtained STL data, the design of subperiosteal implants can be started. The implants' durability, stress, and fatigue resistance are tested using finite element analysis. As a result of the finite element analysis, the designs are reviewed, and an ideal design is shared with the specialists performing the surgical and prosthetic procedures. Suppose specialists desire additional abutments, replacement of fixation screws due to surgical difficulty, or changes in the distance to anatomical points. These are transferred to the models, and the finite element analysis is repeated. With the approval of the specialists, the production phase is started. After production, the implants are sent for sterilization. Prosthetic design and production can be done with subperiosteal implants or after surgery using multi-unit abutments in the mouth. The simultaneous prosthetic and surgical design production allows the prosthesis to be loaded without needing post-surgical impressions. However, the slightest change in the surgically applied subperiosteal implants' position may cause the prosthesis not to fit correctly or be placed under stress. The most common complications in subperiosteal implants are gingival opening on the implant surface, inflammation, infection, fistula formation, and implant mobility [7,8].

Case Description and Results

A 60-year-old male patient was applied to us with the complaint of complete edentulism. The patient had no systemic disease other than Hepatitis B in his anamnesis. The tomographic evaluation determined enough bone to place endosteal implants in the maxilla. However, the bone height is insufficient in the posterior region of the mandible for placing traditional dental implants. Eight endosteal implants in the maxilla and two subperiosteal implants in the mandible were planned for the patient. We followed the "Principles of the Helsinki Declaration," and an "informed consent form" was obtained from the patient. Maxillary surgery and prosthetic treatment were given priority to our patients who wanted to avoid being toothless for a long

time for professional reasons. Under local anesthesia, eight intraosseous implants were placed in the maxilla, and the area was sutured. After the 3-month osseointegration process, a controlling x-ray was taken, and the healing caps of the implants were performed with minor surgery under local anesthesia. A healthy gingival form was expected for one week, and the maxillary implants took open impression posts. The total prosthesis impression was taken from the mandible. After 12 zirconia teeth in the maxilla and a total prosthesis in the mandible, the patient was put on hold for subperiosteal implant design and production. The position and measurement designs of subperiosteal implants are decided according to the zirconia crowns in the maxilla. During the design phase, the distance to anatomical structures such as the mental foramen and mandibular canal was planned to be at least 2mm (Figure 1 a,b).

Since the mandible has a compact structure and to avoid stress or incompatibility in the prostheses to be made on it due to the positioning in the surgical application, it was planned to perform the surgical and prosthetic phases independently of each other. After the design of the subperiosteal implants was approved, the production phase started. After three weeks, we received the subperiosteal implants, 3D printed models, and fixation screws with the instructions. In the procedure performed under general anesthesia, the full-thickness mucoperiosteal flap was removed, and both the buccal and lingual flaps were released for comfortable screwing. Milling and screwing using a low-speed handpick was performed in the vestibule and lingual region, and subperiosteal implants were fixed to the mandible (Figure 2 a,b,c). Suturing was completed so that the multiunit abutments remained in the mouth. The prosthetic phase was started two days after the surgical procedure. When beginning the prosthetic rehabilitation of the subperiosteal implants, impression posts were placed on the multiunit heads in the first stage. Impressions were taken with the double mixing impression method with C-type silicone polymerized by condensation. The laboratory splinted the impression pieces with acrylic (Figure 3a) on the prepared model (Figure 3b) and returned them. After the intraoral fit was checked, the left posterior impression post did not fit. The acrylic base was divided with a steel separating disc, placed in the mouth, and bonded again with acrylic. The last impression was taken with type A impression paste, an additional silicone impression paste. The passive compatibility of the metal substructure sent from the laboratory was checked, and it was seen that there was no problem (Figure 3c). The occlu-

sion of the teeth was adjusted in the final fitting and sent for polishing. The final prosthesis was fixed in the mouth at the torque values determined by the company (30Ncm), and the screw gaps were closed with composite fillings (Figure 3d). The 6-month postoperative controls of our patient were performed by radiographic and intraoral examination, and no complications were observed (Figure 4).

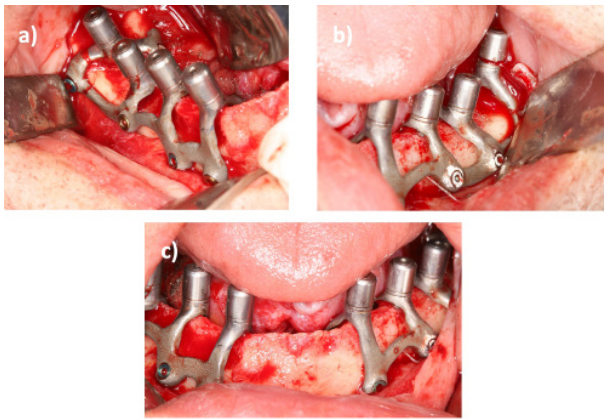


Figure 1. a) Design of the subperiosteal implant and the probable prosthesis frontal view b) Lingual view of the design.

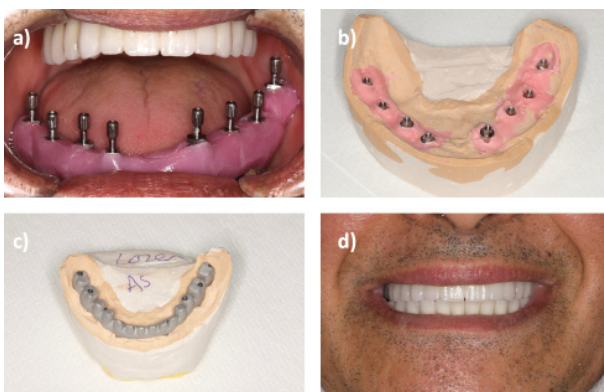


Figure 2. a) View of the fixed subperiosteal implant on the right side of the mandible. b) View of the fixed subperiosteal implant on the left side of the mandible. c) View of both fixed subperiosteal implants.

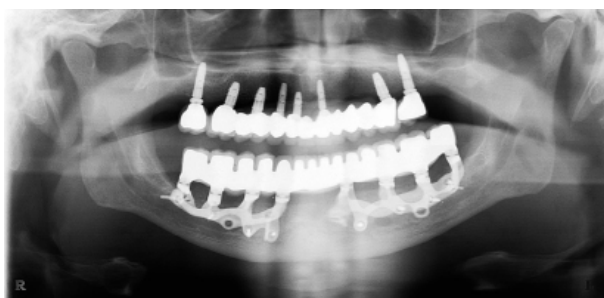

Figure 3. a) Splinted the impression pieces with acrylic. b) Model prepared after impression. c) Metal framework d) Final intraoral situation after prosthetic treatment.

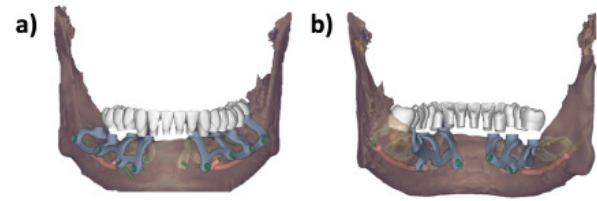


Figure 4. Post-operative 6th-month control X-ray.

Discussion

Subperiosteal implants can be an alternative to advanced surgical methods in cases that prevent the application of traditional intraosseous implants [9]. Subperiosteal implants, successfully applied in both the maxilla and mandible, can also be used together with intraosseous implants, as in our case [5,10,11]. Although the high cost of production seems to be a disadvantage, some studies have shown that the chance of success is higher than in advanced surgical procedures with similar expenses [11]. It is estimated that the cost will decrease with increased production centers.

Subperiosteal implants' design, manufacturing, surgery, and prosthetic procedures require high precision. The quality of the tomography obtained from the patient before the design phase and the ability to observe the maxilla and mandible on the same tomography (wide FOV area) are essential to ensure occlusion. Attention to anatomical structures during the design phase will also prevent possible complications. During the surgical procedure's milling and screw fixation phases, the surrounding tissues should be protected, work should be performed in a clean area, and lighting should be intense [12,13]. No resorption or mobility of the implants was detected in the 6th-month post-operative control of our complete edentulous case, which was rehabilitated using traditionally used intra-bone implants in the maxilla and subperiosteal implants in the mandible. No complications were encountered in the maxillary and mandibular prostheses.

Conclusion

With the development of three-dimensional technologies, subperiosteal implant applications are becoming widespread. Subperiosteal implants and intra-osseous implants can be successfully used together in different jaws. One of the essential advantages of the system is that it provides fixed prosthetic treatment, especially in jaws with advanced bone atrophy. Correct case selection and appropriate surgical and prosthetic

treatment will increase success. Many cases and finite element analyses must be performed to reveal possible complications.

Conflict of Interest

There is no conflict of interest to declare.

References

- [1] Venet L, Perriat M, Mangano FG, Fortin T. Horizontal ridge reconstruction of the anterior maxilla using customized allogeneic bone blocks with a minimally invasive technique -a case series. *BMC Oral Health*. 2017; 17(1):146. [Medline: 29216869] [doi: 10.1186/s12903-017-0423-0].
- [2] Wessing B, Lettner S, Zechner W. Guided Bone Regeneration with Collagen Membranes and Particulate Graft Materials: A Systematic Review and Meta-Analysis. *Int J Oral Maxillofac Implants*. 2018; 33(1):87-100. [Medline: 28938035] [doi: 10.11607/jomi.5461].
- [3] El Chaar E, Urtula AB, Georgantza A, Cruz S, Fallah-Abed, Castano A, Abitbol T, Warner MM. Treatment of Atrophic Ridges with Titanium Mesh: A Retrospective Study Using 100% Mineralized Allograft and Comparing Dental Stone Versus 3D-Printed Models. *Int J Periodontics Restorative Dent*. 2019; 39(4):491-500. [Medline: 31226186] [doi: 10.11607/prd.3733].
- [4] Karan NB, Akinci HO. A Novel Approach for Horizontal Augmentation of Posterior Maxilla Using Ridge Split Technique. *J Craniofac Surg*. 2019; 30(5):1584-8. [Medline: 31299774] [doi: 10.1097/SCS.00000000000005124].
- [5] Weiss CM, Reynolds T. A collective conference on the utilization of subperiosteal implants in implant dentistry. *J Oral Implantol*. 2000; 26(2):127-8. [Medline: 11831330] [doi: 10.1563/1548-1336(2000)26<127:SR>2.0.CO; 2].
- [6] Mangano C, Bianchi A, Mangano FG, Dana J, Colombo M, Solor I, Admakin O. Custom-made 3D printed subperiosteal titanium implants for the prosthetic restoration of the atrophic posterior mandible of elderly patients: a case series. *3D Printing in Medicine*. 2020 Jan 8; 6(1):1. [Medline: 31915946] [doi: 10.1186/s41205-019-0055-x]
- [7] Van den Borre C, Rinaldi M, De Neef B, Loomans NAJ, Nout E, Van Doorne L, Naert I, Politis C, Schouten H, Klomp G, Beckers L, Freilich MM, Mommaerts MY. Patient- and clinician-reported outcomes for the additively manufactured subperiosteal jaw implant (AMSJI) in the maxilla: a prospective multicentre one-year follow-up study. *International Journal of Oral and Maxillofacial Surgery* 2022; 51(2):243-250. [Medline: 34074574] [doi: 10.1016/j.ijom.2021.05.015].
- [8] Zwerger S, Abu-Id MH, Kreusch T. Long-term results of fitting subperiosteal implants: report of twelve patient cases. *Mund Kiefer Gesichtschir*. 2007; 11(6):359-62. [Medline: 17972118] [doi: 10.1007/s10006-007-0081-5].
- [9] Bai L, Zheng L, Ji P, Wan H, Zhou N, Liu R, Wang C. Additively Manufactured Lattice-like Subperiosteal Implants for Rehabilitation of the Severely Atrophic Ridge. *ACS Biomaterials Science & Engineering* 2022; 8(2):912-920. [Medline: 34984904] [doi: 10.1021/acsbiomaterials.1c00962].
- [10] Ma S, Chen Z, Qia F, Sun Y, Yang X, Deng X, Cen L, Cai Q, Wu M, Zhang X, Gao P. Guided bone regeneration with tripolyphosphate cross-linked asymmetric chitosan membrane. *Journal of Dentistry* 2014; 42(12):1603-1612. [Medline: 25193523] [doi: 10.1016/j.jdent.2014.08.015].
- [11] Berton F, Porrelli D, Di Lenarda R, Turco G. A critical review on the production of electrospun nanofibres for guided bone regeneration in oral surgery. *Nanomaterials* 2019; 10(1):16. [Medline: 31861582] [doi: 10.3390/nano10010016].
- [12] De Moor E, Huys SEF, van Lenthe GH, Mommaerts MY, Vander Sloten J. Mechanical evaluation of a patient-specific additively manufactured subperiosteal jaw implant (AMSJI) using finite-element analysis. *International Journal of Oral and Maxillofacial Surgery* 2022; 51(3):405-411. [Medline: 34059405] [doi: 10.1016/j.ijom.2021.05.011].
- [13] Dimitroulis G, Gupta B, Wilson I, Hart C. The atrophic edentulous alveolus. A preliminary study on a new generation of subperiosteal implants. *Oral Maxillofac. Surg.* 2023 Mar; 27(1):69-78. [Medline: 35119553] [doi: 10.1007/s10006-022-01044-3].

Please cite this paper as:
 Gulener F, Mert Acikgoz M, Ongul D, Ak G. Rehabilitation of edentulous patient using endosteal and subperiosteal implants: A case report. *J Craniomax Res* 2023; 10(1): 27-30