



Conservative management of large unicystic ameloblastoma in a young patient: A case report

Abbas Haghghat ¹, Sayed Mohammad Razavi ², Saeedeh Khalesi ^{3*}

1. Craniofacial and Cleft Research Center, Department of Oral and Maxillofacial Surgery, School of Dentistry, Isfahan University of Medical Sciences, Isfahan, Iran.
2. Dental Implant Research Center, Department of Oral and Maxillofacial Pathology, School of Dentistry, Isfahan University of Medical Sciences, Isfahan, Iran.
3. Dental Materials Research Center, Department of Oral and Maxillofacial Pathology, School of Dentistry, Isfahan University of Medical Sciences, Isfahan, Iran.

ARTICLE INFO

Article Type:
Case Report

Received: 8 Nov. 2021
Revised: 5 Dec. 2021
Accepted: 19 Feb. 2022

*Corresponding author:
Saeedeh Khalesi

Dental Materials Research Center, Department of Oral and Maxillofacial Pathology, School of Dentistry, Isfahan University of Medical Sciences, Isfahan, Iran.

Tel: +98-913-1079487
Fax: +98-21-84902473
Email: S_khalesi@Dnt.mui.ac.ir

ABSTRACT

Objectives: Ameloblastoma is a benign neoplasm with origin from odontogenic epithelium. Unicystic ameloblastoma has clinical and radiographically features resemble to other odontogenic cysts but it has a typical ameloblastomatous epithelium lining the cyst cavity.

Case: In this case report study, we presented a 9-year-old girl who was referred to Oral and Maxillofacial Surgery of Isfahan Dental School for the management of a large swelling on the right posterior mandibular region. The histopathologic examination of the specimen showed mural type of unicystic ameloblastoma. In the first step, the patient was treated by decompression of the lesion. Five month after it, shrinkage of the lesion was observed and in the second stage of surgery, curettage of the remaining lesion and extraction of tooth buds in the areas of lesion was performed. After two years, radiographic image showed new bone formation and complete healing of the lesion.

Conclusion: Choosing the best treatment for children with unicystic ameloblastoma requires more attention and all clinical and histopathological parameters should be considered. Conservative treatment for ameloblastoma leads to reduce complications after treatment and affect the patient's quality of life.

Keywords: Ameloblastoma; Jaw; Pathology.

Introduction

Ameloblastoma is a benign neoplasm with origin from odontogenic epithelium [1]. Unicystic ameloblastoma (UA) is a less encountered variant of ameloblastoma that was described in 1977 for the first time by Robinson and Martinez [2]. According to studies, uni-

cystic ameloblastoma may originate from reduced enamel epithelium; or as a result of transformation of dentigerous cyst; or cystic degeneration of solid ameloblastoma [3]. Unicystic ameloblastoma has clinical and radiographical features resemble to other odontogenic cysts but it has a

typical ameloblastomatous epithelium lining the cyst cavity. This lesion has three different variants in histopathological feature with prognostic significance including luminal, intraluminal and mural [4,5]. Because the unicystic ameloblastoma is a less aggressive type of ameloblastoma, simple enucleation has been suggested to be adequate for the majority of these cases [6]. But, a treatment strategy of UA should be decided by histopathological type of the lesion. Unicystic ameloblastoma in mandible bone is a very rare in under 10-year pediatric population [4]. We present a case of unicystic ameloblastoma in a 9-year-old girl and report a conservative approach of patient treatment.

Case Report

A 9-year-old girl referred to the Department of Oral and maxillofacial Surgery of Isfahan Dental School, Iran, with the chief complaint of asymptomatic swelling in the right posterior mandibular region. She has not contributory medical history. The girl had noticed the swelling approximately four months ago and the size of the lesion has increased significantly over time. In extraoral examination, a diffuse large swelling on the right mandibular region with tenderness on palpation was observed. In intraoral examination, there was bony expansion of the labial cortex from the lower right retromolar area to the first deciduous molar (Fig 1,A). Teeth in the area responded to vitality tests. There was no sign of facial nerve or inferior alveolar nerve involvement. Panoramic x-ray revealed a well-defined unilocular radiolucent lesion involving the left side of ramus and angle of mandible that it has second permanent molar teeth bud and first molar teeth roots (Fig 1,B).

Based on the clinical and radiographical features, differential diagnosis was considered as benign odontogenic cyst or tumor including dentigerous cyst, odontogenic keratocyst and ameloblastoma. An incisional biopsy was performed under local anesthesia for the patient. In histopathological examination of the specimen observed a cystic lesion that was lined by ameloblastic epithelium. The lesion has typical features of ameloblastoma in some areas, including columnar basal cells in palisading arrangement with vacuolated cytoplasm, hyperchromatic nuclei polarized away from basement membrane that was resemble to pre-ameloblasts. Suprabasal cells have loosely texture that was resemble to stellate reticulum. Cystic odontogenic epithelium with characteristic features lining fibrous connective tissue wall and the ameloblastoma tumor islands and bonds in the fibrous connective tissue wall

with plexiform pattern were observed. Finally, a definitive diagnosis was made of mural unicystic ameloblastoma (Fig 2,A,B). Patient's parents were informed regarding the different treatment options and recurrence rate of lesion. After obtaining informed consent from the patient's parents and taking into consideration the age of patient, conservative treatment plane was done under general anesthesia. In the first stage of treatment, decompression for privation of bone resection and subsequence of facial deformity was performed for the patient.

In the first stage of surgery, by cutting and removing the mandibular mucosal tissue in the affected area, the retromandibular bone defect was enlarged with a regenerator and washed with a large amount of normal saline. Defective relationship was maintained with the oral cavity with a gauze impregnated with tetracycline ointment which was left in the wound for 4 days. Antibiotics and analgesics were prescribed. Seven days after the operation, the antibiotic gauze was removed and a silicon obturator fabricated on the cast and designed to avoid occlusal interference was used to maintain the fenestration window. Marginal adaptation of the obturator was performed with a secondary silicon impression material. The obturator negated the requirement for frequent gauze changes. The patient carefully washed the cavity regularly and maintain overall proper hygiene of the oral cavity through self-irrigation for five months with the help of her parents. Five months after the first stage of surgery, shrinkage of the lesion, repair and extensive improvement of the bone defect was observed and the radiolucent area was significantly reduced (Fig 3,A). In the second stage of surgery, scar tissue was removed from the bone surface of the markedly diminished fenestration and curettage of the remaining lesion was performed along with extraction of the second and third molar tooth buds to reduce recurrence. Therefore, the patient was in a long-term follow-up. After two years, panoramic x-ray showed that visible new bone formed and the buccal and lingual cortex of mandible was found to be symmetry (Fig 3,B). At the last follow-up period, normal mandible bone contour without signs of recurrence was evident.

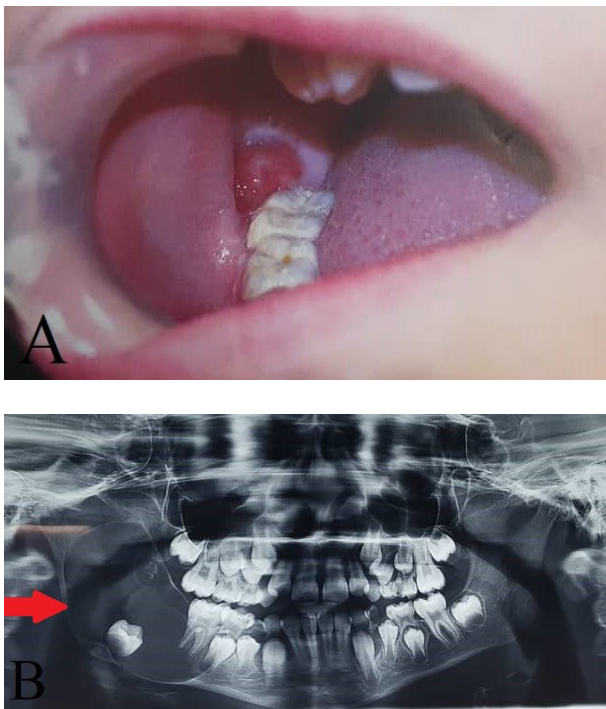


Figure 1. A: Intraoral view showing swelling on the right mandibular region, B: Panoramic x-ray revealed a well-defined unilocular radiolucent lesion involving the left side of mandible.

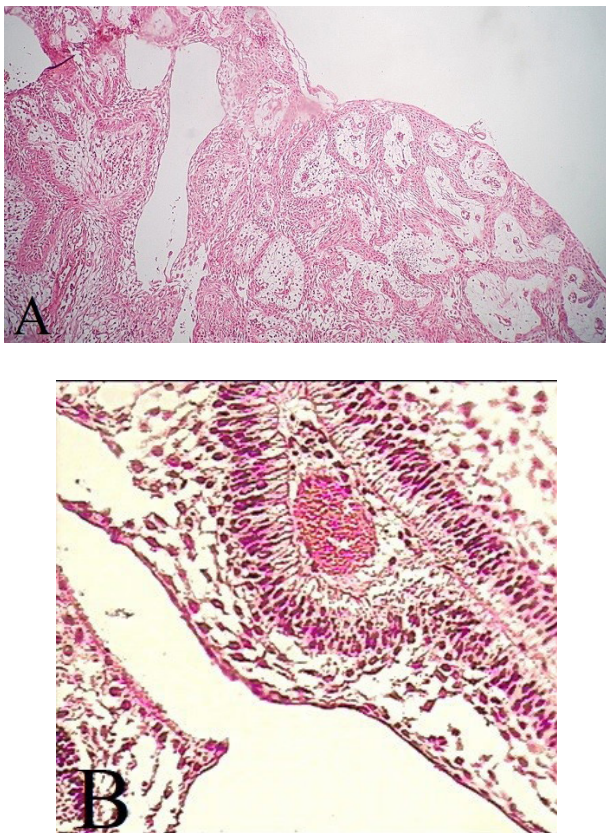


Figure 2. A: Cystic lesion lined by ameloblastomatous epithelium proliferating into connective tissue wall in a plexiform pattern, B: Preameloblasts and stellate reticulum in the surface of lesion.

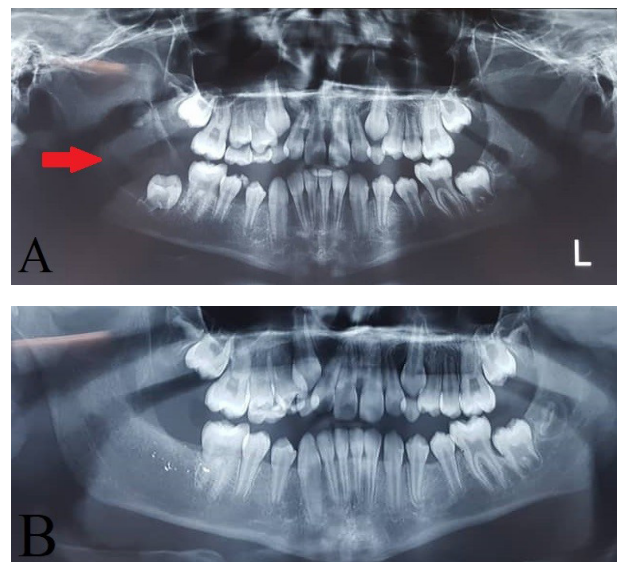


Figure 3. A: Reduce lesion size and repair the mandible bone after first surgery in panoramic x-ray, B: Forming visible new bone at the site of the lesion.

Discussion

Unicystic ameloblastoma accounts for 10% to 15% of all intra-osseous ameloblastoma. This lesion is a tumor of young age group especially in the second decade and has unilocular radiolucency in radiographic view [7]. However, it is often found with impacted teeth, but this lesion can be seen anywhere on the jaw without related to the tooth. The ratio of mandibular to maxillary involvement in unicystic ameloblastoma has been reported to be 13:1 [8]. The most clinical manifestations include painless swelling, facial asymmetry, tooth impaction, displacement and mobility of tooth, root resorption or divergence, occlusal interference, and extrusion of tooth [9]. The present case report describes the UA of mandibular molar region in a 9-years-old girl. Kalaskar et al. reported this lesion in 9 and 12 years old patients [7]. Sasaki et al. described a large UA in 20-years old patient [1]. UA associated with impacted teeth occur more in males than females, but the lesions without association the impacted teeth were more common in females [4]. In this case being a child with the unerupted permanent teeth.

Dentigerous cyst, odontogenic keratocyst, residual cyst, adenomatoid odontogenic tumor and solid ameloblastoma are the differential diagnosis for UA. Odontogenic keratocyst usually has antero-posteriorly growth and large amount of keratin on aspiration. Residual cysts are associated with older age and missing teeth that have been extracted. Adenomatoid odontogenic tumors have a predilection for anterior maxilla. Solid ameloblastoma has multilocular radiolucency and is

seen rare in patients less than 30 years old. Therefore, dentigerous cyst is the most important lesion which should be differentiated from UA [9,10]. Based on classification of Ackermann, UA are three groups on histopathological feature including 1: cyst lined with a variable and often nondescript epithelium (luminal); 2: cyst showing the intraluminal plexiform proliferation of epithelium (intraluminal); 3: cyst with the invasion of epithelium into the cyst wall in either follicular or plexiform pattern (mural) [11]. According to most studies, there is a different behavior between pathological types of UA. The lesion with epithelial penetration in fibrous wall (mural) have the capacity to invade the adjacent bone [12]. Therefore, histopathological type of UA is the most important factor in the treatment strategy. The most studies reported that enucleation is the best treatment plane for Group 1 and Group 2 lesions, while Group 3 lesions should be treated with aggressive plan such as radical resection [1]. The treatment of UA can be radical or conservative approaches. Radical treatments can be achieved by segmental or marginal resection of the lesion, followed by insertion of reconstructive plates. while, conservative approaches comprise enucleation, enucleation followed by application of Carnoy's solution, or marsupialization followed by enucleation [13]. Based on studies, the recurrence rate of the lesion is 3.6% for resection, 30.5% for enucleation, 16% for enucleation with the application of Carnoy solution and 18% for marsupialization with or without other treatment in the second phase [14]. However, overall health of patient, pathological and anatomical indicators, size, location, duration, periodic follow-up examinations should be taken when choosing a treatment plan [15]. But, the presence of ameloblastoma cells in the connective tissue of the cyst wall was the most important predictor of the recurrence of the lesion [16].

In children, the treatment of UA is influenced by three factors including [1] continuing facial growth, different bone physiology (greater percentage of cancellous bone, increased bone turnover and reactive periosteum) and presence of unerupted teeth; [2] difficulty in initial diagnosis; and [3] type of UA. Therefore, although invasive treatment has been suggested to prevent recurrence, more conservative treatments can be used in children [15]. De Paulo et al. treated the extensive unicystic ameloblastoma in a 7-year-old child with marsupialization followed by enucleation [17]. Sasaki et al. reported the treatment with enucleation and deflation of a large UA with mural invasion in a 20-year-old patient without recurrence after a long-

term follow-up [1]. Furthermore, in Meshram et al's study showed that UA in younger population can be successfully treated by a conservative treatment plan by enucleation and bone curettage [15]. Sineedi et al. reported a UA of the mandible in a 9-year-old child. This lesion was surgically managed by enucleation of the cyst with all the impacted teeth. There were no signs of recurrence and his latest radiographic examination showed good bone formation [4]. Kim et al. described a case of an 11-year-old girl with UA of the posterior region of mandibular bone with impaction of the second and third molars. The lesion was marsupialized, and 31 months after marsupialization, surgical enucleation was performed with extraction of the impacted third molar. The second molar, which was preserved, spontaneously and completely erupted [13]. In the Ahmed's study, 10 patients with UA was treated by enucleation with bone curettage followed by application of Carnoy's solution. He showed that even mural types can be successfully treated with conservative approaches [18]. The patient in this study was a 9-year-old girl with a large mural type of UA that was successfully treated conservatively without recurrence and with favorable bone formation after two years of follow-up. Then unicystic ameloblastomas are biologically less aggressive and respond to conservative management such as enucleation, curettage and marsupialization [16]. Aggressive surgical treatment plane like segmental resection should not be performed in children and used only in the patients with recurrent lesions [19]. Bone resection causes deformity that is requires reconstruction methods especially in young people [6]. In general, choosing the right treatment depends on several factors. The continuous growth and facial bone physiology in children with a higher percentage of cancellous bone, bone turn-over and periosteal activity are the effective factors in choosing treatment in children with UA [20]. Recent studies suggest that the radical treatment strategies have severe consequences for the patient and reduces their quality of life. Furthermore, conservative treatment methods for ameloblastoma are associated with a higher risk of recurrence but these methods have lower risks of other complications and fewer surgical interventions for esthetic and functional rehabilitation. Consequently, conservative treatment methods receive a better response from patients. Therefore, less invasive treatment plans for ameloblastoma associated with increasing the quality of life of patients and their greater satisfaction [21]. Marsupialization and decompression are different methods with the aim of reducing the size of lesion by lowering the pressure of cystic fluid and inducing bony apposition to the cystic wall.

In decompression, the surgeon creates a small opening in the cyst and keeps it open by using a rigid drainage tube which prevents the accumulation of food and microorganisms in the area. while, in marsupialization, creating a large window in the bone and connecting the inner cystic wall to the oral mucosa done. Secondary infection is the most disadvantage of these treatment plane [22].

Conclusion

Choosing the best treatment for children with unicystic ameloblastoma requires more attention and all clinical and histopathological parameters should be considered. The management of mural type of unicystic ameloblastoma in children is still require further studies. Conservative treatment for ameloblastoma leads to reduce complications after treatment and affect the patient's quality of life.

Conflict of Interest

There is no conflict of interest to declare.

References

- [1] Sasaki R, Watanabe Y, Ando T, Akizuki T. Two stage enucleation and deflation of a large unicystic ameloblastoma with mural invasion in mandible. *Cranio-maxillofac Trauma Reconstruction* 2014; 7: 139–42.
- [2] Robinson L, Martinez MG. Unicystic ameloblastoma: a prognostically distinct entity. *Cancer* 1977; 40: 2278-85.
- [3] Bajpai M, Agarwal D, Bhalla A, Kumar M, Garg R, Kumar M. Multilocular unicystic ameloblastoma of mandible. *Case Rep Dent* 2013; 2013: 835892.
- [4] Sineedi FA, Aruveetil YA, Kavarodi AM, Harbi SO. Bilocular unicystic ameloblastoma of the mandible in a 9 year old child—A diagnostic and management dilemma. *Saudi Dent J* 2018; 30: 250–5.
- [5] Mahajan AD, Manjunatha, BS, Khurana NM, Shah N. Unicystic ameloblastoma arising from a residual cyst. *BMJ Case Reports* 2014; 2014: bcr2014205157.
- [6] Nowair IM, Eid MK. A modified surgical approach for the treatment of mandibular unicystic ameloblastoma in young patients. *J Cranio-Maxillofacial Surg* 2020; 48 (2): 148-55.
- [7] Kalaskar R, Unawane AS, Kalaskar AR, Pandilwar P. Conservative management of unicystic ameloblastoma in a young child: Report of two cases. *Contemp Clin Dent* 2011; 2(4): 359–63.
- [8] Agani Z, Hamiti-Krasniqi V, Recica J, Loxha MP, Kurshumliu F, Rexhepi A. Maxillary unicystic ameloblastoma: a case report. *BMC Res Notes* 2016; 9: 469.
- [9] Navarro CM, Principi SM, Massucato EM, Sposto MR. Maxillary unicystic ameloblastoma. *Dento-maxillofac Radiol* 2004; 331: 60–2.
- [10] Chaudhary Z, Sangwan V, Pal US, Sharma P. Unicystic ameloblastoma: A diagnostic dilemma. *Natl J Maxillofac Surg.* 2011; 2(1): 89-92.
- [11] Ackermann GL, Altini M, Shear M. The unicystic ameloblastoma: a clinicopathological study of 57 cases. *J Oral Pathol* 1988; 17(9–10): 541–6.
- [12] Gupta N, Saxena S, Rathod VC, Aggarwal P. Unicystic ameloblastoma of the mandible. *J Oral Maxillo Pathol* 2011; 15: 228-31.
- [13] Kim J, Nam E, Yoon S. Conservative management (marsupialization) of unicystic ameloblastoma: literature review and a case report. *Maxillofac Plast Reconstr Surg* 2017; 39, 38.
- [14] Lau SL, Samman N. Recurrence related to treatment modalities of unicystic ameloblastoma: a systematic review. *Int J Oral Maxillofac Surg* 2006; 35(8): 681–90.
- [15] Meshram M, Sagarka L, Dhuvad J, Anchlia S, Vyas S, Shah H. Conservative management of unicystic ameloblastoma in young patients: a prospective single-center trial and review of literature. *J Maxillofac Oral Surg* 2017; 16(3): 333–41.
- [16] Rosenstein T, Pogrel MA, Smith RA, Regezi JA. Cystic ameloblastoma—behavior and treatment of 21 cases. *J Oral Maxillofac Surg* 2001; 59(11): 1311-6.
- [17] De Paulo LF, Oliveira MT, Rodrigues A'R, Zanetta-Barbosa D. Treatment of an extensive unicystic ameloblastoma in a 7-year-old child: the best approach? *Br J Oral Maxillofac Surg* 2015; 53(3): 292–4.
- [18] Ahmed W. Conservative treatment of unicystic ameloblastoma. *Egypt J Oral Maxillofacial Surg* 2020; 11: 8-14.

- [19] Andrade NN, Shetye SP, Mhatre TS. Trends in pediatric ameloblastoma and its management: a 15 year Indian experience. *J Maxillofac Oral Surg* 2013; 12 (1), 60–7.
- [20] Awadalkreem F, Abdoun O. Enucleation and surgical stent as a treatment strategy for a large unicystic ameloblastoma: Case report and review of literature. *Int J Surg Case Rep* 2020; 77: 371-7.
- [21] Hresko A, Burtyn O, Pavlovskiy L, Snisarevskiy P, Lapshyna J, Chepurnyi Y, et al. Controversies in ameloblastoma management: evaluation of decision making, based on a retrospective analysis. *Med Oral Patol Oral Cir Bucal* 2021; 26(2): e181-e186.
- [22] Matsuda SH, Yoshimura H, Yoshida H, Imamura Y, Ueno T, Sano K. Three-dimensional volumetric analysis of unicystic ameloblastoma before and after marsupialization using OsiriX Software. *J Hard Tissue Biol* 2019; 28(2): 233-6.

Please cite this paper as:

Haghighat A, Razavi M, Khalesi S. Conservative management of large unicystic ameloblastoma in a young patient: A case report. *J Craniomax Res* 2022; 9(2): 100-105