

## Acute Lymphoblastic Leukemia Masquerading as Idiopathic Hypereosinophilic Syndrome in an Adolescent Male: A Case Report and Review of Diagnostic Strategies

Ruchee Khanna MD<sup>1\*</sup>, Anjali Chaurasia MD<sup>2</sup>, Seemitr Verma MD<sup>3</sup>, Vinay Khanna MD<sup>4</sup>

1. Associate Professor (MD Pathology), Department of Pathology, Kasturba Medical College, Manipal, Manipal Academy of Higher Education, Manipal, Karnataka

2. Tutor, Department of Pathology, Kasturba Medical College, Manipal, Manipal Academy of Higher Education, Manipal, Karnataka

3. Associate Professor (MD Pathology), Department of Pathology, Kasturba Medical College, Manipal, Manipal Academy of Higher Education, Manipal, Karnataka

4. Associate Professor (MD Microbiology), Department of Microbiology, Kasturba Medical College, Manipal, Manipal Academy of Higher Education, Manipal, Karnataka

\*Corresponding author: Dr Ruchee Khanna, Associate Professor (MD Pathology), Department of Pathology, Kasturba Medical College, Manipal, Manipal Academy of Higher Education, Manipal, Karnataka. Email: druchikmc@gmail.com. ORCID ID: 0000-0002-4308-2961.

Received: 21 April 2024

Accepted: 23 January 2025

### Abstract

Acute lymphoblastic leukemia (ALL) accompanying with hypereosinophilia is an extremely rare blood cancer, with an incidence rate of less than 1%. In most cases, patients with ALL and hypereosinophilia rarely show blasts in the peripheral blood, which can potentially lead to misdiagnosis. This study presents a case of an 18-year-old male who was initially diagnosed with Idiopathic Hypereosinophilic Syndrome (IHES) and later found to have B-cell ALL with hypereosinophilia. The patient presented with complaints of excessive weight gain, easy fatigability, stretch marks on the skin, and mild limb pain. Initial blood examinations revealed leucocytosis with eosinophilia and atypical cells. Bone marrow examination and flow cytometry confirmed the diagnosis of B-cell ALL with eosinophilia. For adolescents and young adults with hypereosinophilia, a comprehensive clinical assessment should be conducted. This includes a complete blood count with differential analysis, peripheral blood smear examination, as well as bone marrow aspiration and biopsy. Flow cytometry and cytogenetic studies of the bone marrow are crucial to confirm ALL diagnosis and to identify any associated genetic abnormalities. The most frequently observed genetic abnormality in patients with ALL and hypereosinophilia is the translocation t(5;14)(q31;q32), which results in the overproduction of interleukin (IL)-3, IL-5 and granulocyte-macrophage colony-stimulating factor (GM-CSF). This case underscores the importance of maintaining a high level of clinical suspicion and performing a thorough evaluation when managing adolescents and young adults presenting with atypical manifestations of ALL.

**Keywords:** Acute lymphoblastic leukemia, Cytogenetics, Hypereosinophilic Syndrome

### Introduction

Eosinophilia, which is manifested by an elevated eosinophil count in the bloodstream, is associated with various conditions, including allergic reactions, infections by parasites, and certain cancers (1). Acute Lymphoblastic Leukemia (ALL) may be accompanied with an increased number of eosinophils in the blood, known as hypereosinophilia, a particularly rare incidence accounting for less than 1% of cases (2).

Patients with ALL accompanied by hypereosinophilia seldom have blasts present in their blood, a condition that may lead to a misdiagnosis of ALL (3). Healthcare professionals must recognize this rare presentation of ALL to prevent diagnostic delays and administer prompt treatments. ALL is considered as the leading type of childhood cancer, typically peaking in incidence among children aged two to five (4). Most diagnoses occur in children younger than 10 years of old.

However, in adolescents and young adults, the incidence rate of ALL drops considerably. The presentation of ALL in these elder age groups can be different from that of younger children and often involves a greater prevalence of hypereosinophilia with fewer circulating blasts. Such nonstandard presentation may contribute to diagnostic and treatment delays. An exhaustive clinical examination and a complete blood count that includes a differential as well as a peripheral blood smear analysis are necessary for the evaluation of hypereosinophilia in adolescents and young adults. Furthermore, bone marrow aspiration and biopsy are critical. Flow cytometry along with cytogenetic testing of the bone marrow samples are vital to confirm ALL and detect any genetic irregularities. The most prevalent genetic variation related to ALL with concurrent hypereosinophilia is the chromosomal translocation t (5; 14 q31; q32). This anomaly triggers excessive production of interleukins (IL)-3, IL-5, and the granulocyte-macrophage colony-stimulating factor (GM-CSF) (5). Once ALL has been definitively diagnosed, commencing chemotherapy without delay is imperative to enhance patient outcomes. The presence of hypereosinophilia in cases of ALL is an indicator of a challenging prognosis for both pediatric and adult patients, with an average survival period of approximately seven and a half months. This is often due to the infiltration of organs and the emergence of severe complications. As such, it is critical to promptly identify and treat this uncommon manifestation of ALL, and thus to enhance the chances of a better patient outcome.

## Case Report

This study presents a case of an 18-year-old male who was initially identified with Idiopathic Hypereosinophilic Syndrome (IHES) at a different institution. He

reported experiencing significant weight gain, a general sense of fatigue, noticeable stretch marks on his skin, and mild discomfort in his extremities. Upon physical examination, he manifested characteristics suggestive of Cushing's syndrome; however, his general assessment was unremarkable, indicating no signs of lymphadenopathy.

Initial blood investigations showed a hemoglobin level of 11.6 g/dL and a total leukocyte count of  $67.4 \times 10^3/\mu\text{L}$ . The differential count on the peripheral smear revealed 35% neutrophils, 10% lymphocytes, 50% eosinophils, and 5% atypical cells. The absolute eosinophil count was  $33.70 \times 10^3/\mu\text{L}$ , and the platelet count was  $174 \times 10^3/\mu\text{L}$ .

Bone marrow examination revealed an increased cellularity with suppressed erythroid production and atypical myeloid development. Analysis of the bone marrow aspirate's nucleated cell population showed 44% blast cells and 28% eosinophils along with their precursors. The blast cells ranged from small to medium in size, exhibiting a high nuclear-to-cytoplasmic ratio, compact nuclear chromatin, indistinct nucleoli, and minimal cytoplasm. While megakaryocytes were present in normal quantities, they displayed slight dysplastic features. Cytochemical stains, including Myeloperoxidase (MPO), Sudan Black B (SBB), and PAS, yielded negative results. These findings led to a diagnosis of Acute Leukemia with Eosinophilia. A bone marrow biopsy was performed, confirmed the findings of the aspirate, and showed hypercellular marrow with extensive infiltration by lymphoblasts and increased eosinophils.

Flow cytometry performed on the bone marrow aspirate showed cells with low side scatter and dim CD45 expression, which were gated as blasts. The blasts were positive for B-lymphoid markers (CD19, CD10, and cCD79a) and stem cell markers

(CD34 and HLA-DR). The blasts were negative for all myeloid, monocytic, and T-lymphoid cell markers. Additionally, a population showing high side scatter (60.5% of viable events) and moderate CD45 expression was observed, suggestive of eosinophils. The immunophenotypic analysis led to a conclusive diagnosis of B-cell Acute Lymphoblastic Leukemia (ALL) with eosinophilia. Cytogenetic analysis was performed on the bone marrow sample, revealing a normal karyotype (46, XY). Molecular diagnostic tests, including PCR for BCR-ABL1, MLL rearrangements, and ETV6-RUNX1 were negative. To rule out secondary causes of eosinophilia, the present authors conducted tests for parasitic infections, allergies, and autoimmune disorders, all of which came back negative.

While ALL accompanied by hypereosinophilia is uncommon in adolescent and young adult populations, medical practitioners should remain vigilant when evaluating patients with unexplained hypereosinophilia. A thorough diagnostic process, encompassing bone marrow analysis and flow cytometric studies, is crucial for accurate identification and timely commencement of suitable treatment. This case study underscores the necessity of maintaining a high degree of clinical suspicion and conducting comprehensive assessments when managing adolescents and young adults who exhibit unusual manifestations of ALL.

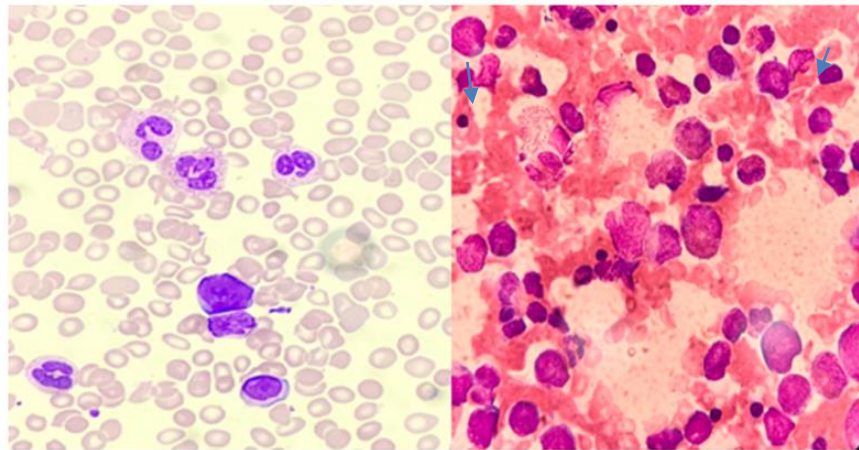


Figure 1. Peripheral smear and bone marrow aspirate showing blasts, eosinophils, and myeloid precursors (MGG stain, Leishman stain 40x)

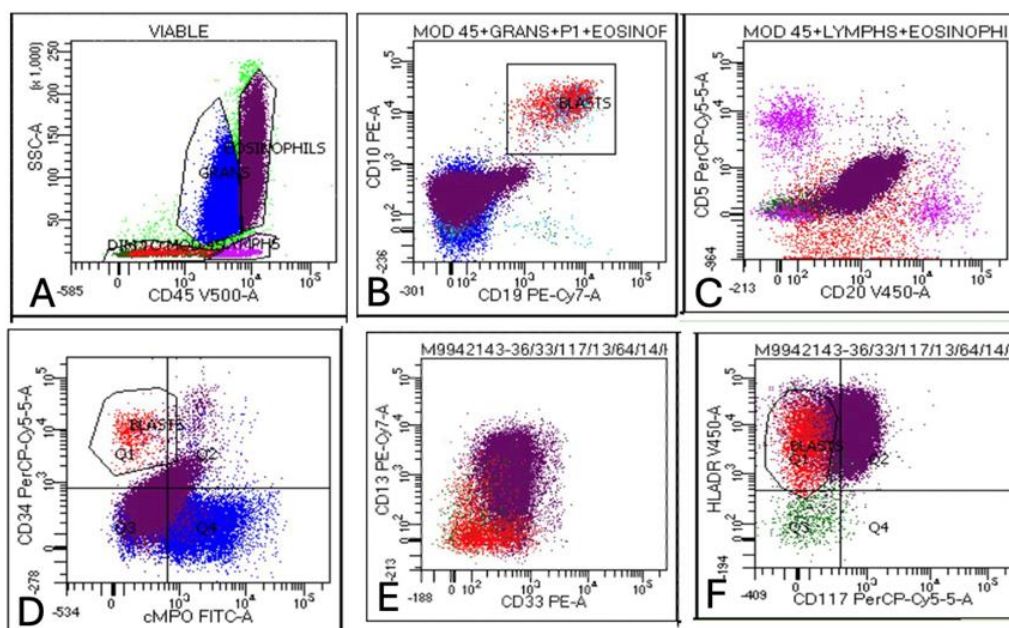


Figure 2. (A) Flow cytometry scatter plot showing blasts with low side scatter and dim to moderate CD45 expression. Eosinophils are increased (~50% of the total population). (B): Blasts showing homogeneous bright expression of CD10 and CD19 (C): Blasts showing heterogeneous expression for CD20 and being negative for CD5 (D): Blasts being bright positive for CD34 and negative for cMPO (E): Blasts being negative for CD13 and CD33. (F): Blasts being bright for HLADR and negative for CD117

## Discussion

Hypereosinophilia concurrent with ALL, initially reported by Spitzer and Garson in 1973, is an uncommon phenomenon (6). The etiology of hypereosinophilia is diverse, encompassing both primary (clonal and idiopathic) and secondary medical disorders. Among the secondary causes, infectious origins, such as tissue-invading parasites, as well as non-infectious sources, including medication side effects, toxin exposure, allergic reactions, or inflammatory processes, can be identified. The diagnosis of B-cell ALL with hypereosinophilia in this case was based on a combination of clinical presentation, morphological findings, immunophenotyping, and genetic studies. The absence of circulating blasts initially led to a misdiagnosis of an idiopathic hypereosinophilic syndrome, highlighting the importance of thorough bone marrow examination and flow cytometry in cases of

unexplained hypereosinophilia (1). Eosinophilia is noted in a minority of pediatric ALL cases, with an increased incidence in males and an average onset of 14 years (2) and the present case of an 18 year old male shows similar demographic profile. This phenotype is typically accompanied by organ involvement due to eosinophilic infiltration, commonly affecting the cardiac, pulmonary, dermal, and central nervous systems, as well as hepatic and splenic tissues (7). The differential diagnosis for this case initially encompassed several conditions associated with hypereosinophilia. Idiopathic Hypereosinophilic Syndrome was first considered due to the marked eosinophilia without an apparent cause. Chronic Eosinophilic Leukemia, a clonal proliferation of eosinophils, was also one of the differential diagnosis. Lymphocyte-Variant Hypereosinophilia, where T-cell clones produce cytokines leading to

eosinophilia, was another possibility. Parasitic infections, particularly those causing tissue invasion, were considered as they can lead to marked eosinophilia. Allergic or autoimmune disorders, which can sometimes be manifested with significant eosinophilia, were also part of the initial differential. Lastly, Acute Myeloid Leukemia with Eosinophilia was considered as another hematological malignancy that can be accompanied with an increase in eosinophils. The final diagnosis of B-cell ALL with hypereosinophilia was reached based on several key findings. The bone marrow examination revealed 44% lymphoblasts, which was crucial in steering toward a leukemic process. Flow cytometry confirmed the B-lymphoid lineage of the blasts, showing positivity for CD19, CD10, cCD79a, CD34, and HLA-DR. The negative myeloid markers helped rule out AML. The absence of clonal T-cell populations or parasitic infections further narrowed the diagnosis. Additionally, the lack of PDGFRA, PDGFRB, or FGFR1 rearrangements, typically seen in myeloid neoplasms with eosinophilia, supported the diagnosis of ALL. This case underscores the importance of comprehensive bone marrow evaluation, including morphology, flow cytometry, and genetic studies, in patients showing unexplained hypereosinophilia, even when peripheral blood blasts are not evident. Notably, the chromosomal anomaly is typically observed exclusively in leukemic blast cells, whereas eosinophils display a normal karyotype in 90% of instances. This supports the theory that the eosinophilia is a secondary response (7). In the 2008 WHO classification of lymphoid neoplasms, this condition is categorized as "B lymphoblastic leukemia/lymphoma with (5; 14); IL3-IGH (7). Additional cytogenetic irregularities sporadically linked to this condition encompass 45XY, t(7;12)(q22;p13), -9, hyperdiploidy with 5q

deletion, 9p21 deletion, t(5;14), t(5;12)(q31;p13) (8), 12p13, and ETV6/ACS2 due to t(9;12)(q22;p13) (3). Cases exhibiting normal karyotype, as observed in the present case, have also been documented. Research by Sutton et al. highlighted the median age of diagnosis as 14 years and the prevalence of the B-cell phenotype in ALL with eosinophilia. The most recurrent genetic translocation reported was t(5; 14) (q31; q32) (9). It was noted that such patients often have a challenging prognosis, with a median survival noted to be 7.5 months. In a report, Wiersma et al. described a patient with ALL and hypereosinophilia who manifested fever, respiratory distress, and myocardial infarction, stressing the significance of including ALL in differential diagnoses when hypereosinophilia is present, irrespective of cytogenetic normalcy (10). The management of patients with ALL and hypereosinophilia involves a combination of chemotherapy and supportive care. The chemotherapy regimen typically includes induction, consolidation, and maintenance phases, with the use of agents such as vincristine, daunorubicin, L-asparaginase, and prednisone (11). The patient was started on a modified BFM (Berlin-Frankfurt-Münster) protocol for high-risk ALL. The patient tolerated the treatment well, with a rapid reduction in peripheral blood eosinophil count within the first week of therapy. Supportive care measures included management of complications related to hypereosinophilia, such as organ damage and thromboembolic events (12). The patient was closely monitored since achieving remission. Follow-up procedures included regular complete blood counts and biochemical profiles during maintenance therapy, conducted monthly. The chosen treatment protocol followed current guidelines for high-risk ALL in adolescents and young adults. While targeted therapies have shown promise in certain ALL

subtypes, the absence of specific genetic abnormalities in this case precluded their use. The rapid response to standard chemotherapy, as evidenced by the quick reduction in eosinophil count and achievement of morphological remission, supports the efficacy of this approach in ALL with hypereosinophilia. Recent literature suggests that patients with ALL and hypereosinophilia may have a poorer prognosis compared to those without hypereosinophilia. However, early recognition and prompt initiation of intensive chemotherapy can lead to favorable outcomes, as demonstrated in the present case. Long-term follow-up and monitoring for potential late effects, particularly those related to eosinophil-mediated organ damage, remain crucial in the management of these patients.

## Conclusion

The elevated eosinophil count in peripheral blood samples can complicate the identification of ALL in this rare variant. The limited number of blast cells observable in peripheral blood tests may hinder timely ALL diagnosis. Medical professionals, including clinicians and pathologists require thorough familiarity with this uncommon presentation to enable early detection and swift commencement of treatment. Although ALL presenting with hypereosinophilia is rare in adolescents and young adults, its diagnosis should be considered in patients presenting with unexplained hypereosinophilia. A comprehensive diagnostic workup, including bone marrow examination, flow cytometry, and cytogenetic studies, is essential for accurate diagnosis and timely initiation of appropriate treatment.

## Acknowledgments

We would like to express our gratitude to the patient and his family for their cooperation. We also acknowledge the support and guidance provided by the Department of Hematology and Oncology at our institution. AI was not used in the article.

## Author's Contributions

Dr. Ruchee Khanna, Dr. Seemitr Verma, and Dr. Vinay Khanna conceptualized and designed the study. Dr. Ruchee Khanna and Dr. Anjali Chaurasia conducted the literature review. Dr. Anjali Chaurasia drafted the original manuscript. Dr. Ruchee Khanna, Dr. Seemitr Verma, and Dr. Vinay Khanna revised and modified the draft and contributed to addressing the reviewers' comments. Dr. Ruchee Khanna held primary responsibility for the final content. All authors critically reviewed, revised, and approved the final version of the manuscript for submission.

## Funding

None

## Conflict of Interest

The authors declare no conflict of interest regarding this manuscript.

## References

1. Gotlib J. World Health Organization-defined eosinophilic disorders: 2017 update on diagnosis, risk stratification, and management. *Am J Hematol* 2017; 92(11): 1243-1259.
2. Rezamand A, Ghorashi Z, Ghorashi S, Nezami N. Eosinophilic presentation of acute lymphoblastic leukemia. *Am J Case Rep* 2013; 14:143-146.
3. Bhatti FA, Hussain I, Ali MZ. Adult B lymphoblastic leukaemia/lymphoma with hypodiploidy (-9) and a novel chromosomal translocation t (7; 12) (q22;

- p13) presenting with severe eosinophilia - case report and review of literature. *J Hematol Oncol* 2009; 2:26-29.
4. Hunger SP, Mullighan CG. Acute lymphoblastic leukemia in children. *N Engl J Med* 2015; 373 (16):1541-1552.
  5. Grimaldi JC, Meeker TC. The t (5; 14) chromosomal translocation in a case of acute lymphocytic leukemia joins the interleukin-3 gene to the immunoglobulin heavy chain gene. *Blood* 1989; 73(8): 2081-2085.
  6. Spitzer G, Garson OM. Lymphoblastic leukemia with marked eosinophilia: a report of two cases. *Blood* 1973; 42(3):377-384.
  7. Narayanan G, Soman LV, Kumar R. Hypereosinophilia: A rare presentation of acute lymphoblastic leukaemia. *J Postgrad Med* 2018; 64(1): 50-52.
  8. Shomali W, Gotlib J. World Health Organization-defined eosinophilic disorders: 2019 update on diagnosis, risk stratification, and management. *Am J Hematol* 2019; 94(10): 1149-1167.
  9. Sutton R, Venn NC, Tolisano J, Bahar AY, Giles JE, Ashton LJ, et al. Clinical significance of elevated eosinophil number in acute lymphoblastic leukemia in children and adolescents: an analysis of 22 cases. *Leuk Lymphoma* 2009; 50(12):2036-2040.
  10. Wiersma SR, Ortega J, Sobel E, Weinberg KI. Clinical importance of myeloid-antigen expression in acute lymphoblastic leukemia of childhood. *N Engl J Med* 1991; 324(12): 800-808.
  11. Terwilliger T, Abdul-Hay M. Acute lymphoblastic leukemia: a comprehensive review and 2017 update. *Blood Cancer J* 2017; 7(6): e577-e579.
  12. Wilson F, Tefferi A. Acute lymphocytic leukemia with eosinophilia: two case reports and a literature review. *Leuk lymphoma* 2005; 46(7):1045-1050.