

Locally Advanced Childhood Nasopharyngeal Cancer: A Case Series

Julius Oentario MD^{*1}, Irwan Ramli PhD¹, Endang Nuryadi PhD¹

1. Department of Radiation Oncology, Faculty of Medicine Universitas Indonesia - Dr. Cipto Mangunkusumo Hospital, Jakarta, Indonesia

*Corresponding author: dr Julius Oentario, Department of Radiation Oncology, Faculty of Medicine Universitas Indonesia – Dr. Cipto Mangunkusumo Hospital, Jakarta, Indonesia. Email: Julius_oentario2005@yahoo.com. ORCID ID: 0000-0003-2839-2555.

Received: 22 October 2023

Accepted: 29 April 2024

Abstract

Nasopharyngeal carcinoma is a rare malignant tumor in childhood. To date, no consensus has been achieved concerning the recommendations for the management of childhood Nasopharyngeal carcinoma. Chemotherapy and radiotherapy are the main modalities in the management of nasopharyngeal carcinoma (NPC). Five cases (with an age range between 10 and 16 years), including one patient with stage III NPC and four patients with stage IV NPC, are reported in this study. All patients received four courses of induction chemotherapy followed by concurrent chemoradiation with cumulative irradiation, with a dose of 70 Gy in 33-37 fractions. Patients were treated with intensity modulated radiation therapy with simultaneous integrated boost technique using helical Tomotherapy. After two-year's follow-up, four patients were achieved complete response, one patient showed residual disease in lymph nodes in the neck and bone metastases one year after the completion of treatment. Treatment side effects were well tolerated, there was no acute toxicity grade 3 or 4, and late toxicity consisted of chronic sinusitis, grade 1 xerostomia, and grade 1 skin fibrosis.

Keywords: Chemoradiotherapy, Childhood, Induction chemotherapy, Nasopharyngeal carcinoma

Introduction

Nasopharyngeal carcinoma (NPC) is known to be endemic in South China and Southeast Asia. NPC incidence is generally found at the age of 40 to 50 years, but in some cases, it is also found at the age of 10 to 20 years. NPC is rarely found in children and represents less than 1% of all childhood cancers (1, 2). Childhood NPC is different from adulthood NPC. Childhood NPC is associated with Epstein-Barr virus (EBV) infection, undifferentiated histological type, and is frequently found at an advanced stage with a higher metastatic rate (3). Like any other rare malignant case in other childhood cancers, the strategy for treating childhood NPC is still adopted from adult patient guidelines, which mainly consist of combined radiotherapy and chemotherapy. Although undifferentiated NPC is highly sensitive to radiation therapy, a five-year overall survival (OS) rate, ranging from 30% to 60%, has been reported with radiotherapy

alone. The main problem with this approach is treatment failure due to systemic spread and late radiation effects. Therefore, to achieve better clinical outcomes, combination therapy, radiotherapy and chemotherapy, is recommended (4).

Case Report

In this case series, five patients were diagnosed with locally advanced NPC at the time of first diagnosis, the median age of the patients was 13 years. The patient's complaints were lumps in the neck, nasal obstruction, bleeding and discharge, diplopia, and tinnitus. Diagnoses were made using nasopharyngeal biopsy; three patients had undifferentiated NPC, and two had non-keratinizing NPC. Before treatment, evaluation was done for all the patients in the form of history taking, physical examination, laboratory examination, dental and oral examination, head and neck imaging, chest X-ray, and bone scan if necessary. Disease staging is

classified following the American Joint Committee on Cancer (AJCC), 8th edition. All patients received induction chemotherapy with a regimen of cisplatin (100 mg/m², day 1) and fluorouracil (1000 mg/m², days 1-5) every four weeks for four cycles followed by concurrent chemoradiation. After induction chemotherapy, patients were evaluated using Computed Tomography (CT) scan or Magnetic Resonance Imaging (MRI). For radiotherapy, the patient was immobilized in a supine position with the head extended using a thermoplastic head and neck mask that covered from the head to the shoulders. Then, a contrast-enhanced CT simulation from the vertex to 2 cm below the sternoclavicular joint, with a slice thickness of 2 mm, was performed. Gross Tumor Volume (GTV) was defined as the primary tumor or lymph nodes found on head and neck CT scans or MRI with contrast-enhanced diffusion imaging on the CT simulation. Clinical Target Volume (CTV) 1 included the GTV plus a margin of 5 mm or 10 mm to the lymph nodes (LN) with extracapsular extension (ECE), the entire nasopharynx, and all involved LN levels. CTV2 encompassed CTV1 with an additional 5 mm margin, extension of the primary tumor before induction chemotherapy, high-risk areas (LN levels II, III, V, VII, and Ib in specific cases). CTV3 included cervical lymph nodes at level IV and Vb. Planning Target Volume (PTV) 1, PTV2, and PTV3 encompassed CTV1, CTV2, and CTV3 plus a 5 mm margin, taking into account setup margin and patient movement considerations. All patients received definitive radiotherapy using Helical Tomotherapy (Accuray, TomoHD™) with Intensity-Modulated Radiation Therapy (IMRT) Simultaneous Integrated Boost (SIB) technique. PTV1 received a dose of 70 Gy, while PTV2 and PTV3 were respectively given doses of 60-63 Gy and 54-56 Gy, delivered in 33-37 fractions. This treatment was combined

with concurrent cisplatin with a weekly dose of 40 mg/m². Dose constraints for healthy tissues were based on normal tissue tolerance from Quantitative Analysis of Normal Tissue Effects in the Clinic (QUANTEC). During chemoradiation, patients experienced acute toxicity in the form of Grade 1 dermatitis (100%), Grade 1 xerostomia (80%), Grade 1 oral mucositis (100%), and Grade 2 pharyngeal mucositis (20%). Overall, patients experienced minimal acute side-effects within tolerance limits. Therapeutic response evaluation was done using radiological examinations, including contrast-enhanced CT scans or MRI of the head and neck, accompanied with clinical assessments (Figure 1). A follow-up after 2 years revealed good locoregional control in four patients and residual disease in one patient's neck lymph nodes. However, one patient was found to have bone metastasis one year after treatment completion. Additionally, further side-effects, including chronic sinusitis, Grade 1 xerostomia (dry mouth), and grade 1 skin fibrosis, were observed.

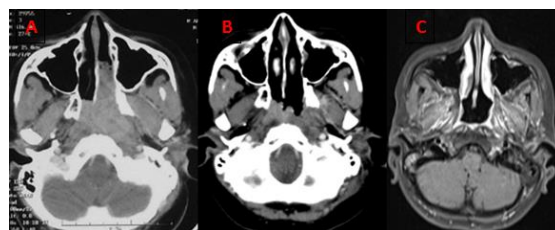


Figure 1. CT scan and MRI of the Nasopharynx with contrast before and after treatment A. CT scan before treatment, B. CT scan after induction chemotherapy, C. Contrast-enhanced T1-weighted MRI of the Nasopharynx for a two-year follow-up after chemoradiation treatment with complete response

Discussion

The incidence rate of childhood NPC is found to be 1 in 100,000 people per year. The median age of cases of childhood NPC is 13 years, and the highest incidence is observed in males (with a male-to-female ratio of 8:1) (1, 5). The most common histopathological type in children is World Health Organization (WHO) Type III, found in over 90% of cases in children under the age of 16 (4). The classification of childhood NPC is the same as that used in adults, with the most commonly used system based on AJCC, 8th edition. More than 80% of childhood NPC cases are diagnosed at stage IV (locally advanced stage), with a few patients (less than 10%) presenting with distant metastasis (5). The optimal treatment modalities for pediatric patients are not yet well-understood, as children are often excluded from previous clinical trials that have primarily involved adult patients. In stages I and II (N0), although rare, radiation therapy alone can be administered, with a 10-year survival rate reaching up to 98% (6). On the other hand, various retrospective and prospective studies have shown that combined radiotherapy and chemotherapy can lead to favorable outcomes in case of children with locally advanced stage (7-9). Patients in stage IVB may receive treatment using a multimodal approach, which includes chemotherapy, locoregional radiation, and, in certain cases, treatment for local metastasis and supportive care. Platinum-based chemotherapy is the standard-of-care treatment, but a chemotherapy regimen depends on the timing of chemotherapy administration, whether neoadjuvant, or concurrent, or adjuvant, following radiotherapy. NPC is a malignancy that is highly sensitive to radiation, particularly undifferentiated NPC. Therefore, radiation therapy is the primary modality in the management of

NPC (1, 3). A large retrospective study comparing platinum-based induction chemotherapy plus concurrent chemoradiotherapy versus concurrent chemoradiotherapy alone (10) showed that induction chemotherapy yielded a better five-year OS rate (83.7% vs. 74.6%, $p=0.153$) and Progression-Free Survival (PFS) (79.2% vs. 73.4%, $p=0.355$). However, induction chemotherapy was also associated with an increased incidence rate of severe neutropenia. The optimal type of induction chemotherapy is still needed to be established, but some studies have reported a favorable response with regimens involving cisplatin and 5-FU for three to four cycles (7, 8). Over the past few decades, radiation therapy for NPC, using 2D-RT techniques, has provided satisfactory disease control outcomes but it is accompanied with a high probability of toxicity. Subsequently, Three-Dimensional Conformal Radiation Therapy (3D-CRT), aided by CT or MRI for better tumor target delineation, has reduced toxicity in healthy tissues. IMRT is an advanced form of 3D-CRT that has had a significant impact on the management of NPC, particularly in the field of radiation therapy. IMRT can offer a more conformal dose distribution to the target volume and is better at reducing dose spread to the surrounding healthy tissues (11, 12). Proton therapy can reduce dose spread to healthy tissues outside the target volume. Various dosimetric and cohort studies have shown that proton therapy planning, in comparison to photon-based IMRT planning, can lower radiation doses to organs at risk, especially the parotid glands, cochlea, maxilla, and larynx. However, longer follow-up studies are still needed to assess late complications and clinical outcomes (12, 13). The most frequently encountered acute radiation toxicities include grade 2-3 skin reactions, mucositis, dysphagia, and weight loss. The high survival rate in pediatric

nasopharyngeal cancer patients has led to a significant number of survivors who are at risk of experiencing late toxicities as a result of their treatment (7-10).

Conclusion

NPC in children is a rare malignancy, which is often diagnosed at an advanced local tumor stage. However, it, as compared to NPC in adults, has a better prognosis. Treatment strategies involving induction chemotherapy for locally advanced disease followed by concurrent chemoradiation using IMRT-SIB techniques, in comparison to 2D/3D-CRT techniques, can lead to more favorable clinical outcomes and lower radiation toxicity.

Acknowledgements

I would like to acknowledge everyone who has contributed to these patients' treatment.

Author's contributions

JO performed the conceptualization, data collection and writing the initial draft of manuscript. IR designed the methodology and provided critical feedback. EN review and edited the manuscript. All authors reviewed and approved the final version of the manuscript.

Funding

None

Conflict of interest

The authors declare that there is no conflict of interest.

References

1. Wei, William I, Sham JS. Nasopharyngeal carcinoma. *Lancet* 2005; 365(9476):2041-2054.

2. Sung H, Ferlay J, Siegel RL, Laversanne M, Soerjomataram I, Jemal A, Bray F. Global cancer statistics 2020: GLOBOCAN estimates of incidence and mortality worldwide for 36 cancers in 185 countries. *CA cancer J* 2021; 71(3):209-249.
3. Rouge ME, Brisse H, Helfre S, Teissier N, Freneaux P, Orbach D. Undifferentiated nasopharyngeal carcinoma in adolescent and children. *B Cancer* 2011; 98(3):337-345.
4. Ayan I, Kaytan E, Ayan N. Childhood nasopharyngeal carcinoma: from biology to treatment. *Lancet Oncol* 2003; 4(1):13-21.
5. Sultan I, Casanova M, Ferrari A, Rihani R, Rodriguez-Galindo C. Differential features of nasopharyngeal carcinoma in children and adults: a SEER study. *Pediatr Blood Cancer* 2010; 55(2):279-284.
6. Chua DT, Sham JS, Kwong DL, Au GK. Treatment outcome after radiotherapy alone for patients with stage I-II nasopharyngeal carcinoma. *Cancer* 2003; 98(1):74-80.
7. Qiu WZ, Peng XS, Xia HQ, Huang PY, Guo X, Cao KJ. A retrospective study comparing the outcomes and toxicities of intensity-modulated radiotherapy versus two-dimensional conventional radiotherapy for the treatment of children and adolescent nasopharyngeal carcinoma. *J Cancer Res Clin* 2017; 143(8):1563-1572.
8. Rodriguez-Galindo C, Krailo MD, Krasin MJ, Huang L, McCarville MB, Hicks J, et al. Treatment of childhood nasopharyngeal carcinoma with induction chemotherapy and concurrent chemoradiotherapy: results of the children's oncology group ARAR0331 study. *J Clin Oncol* 2019; 37(35):3369-3372.
9. Mertens R, Granzen B, Lassay L, Bucsky P, Hundgen M, Stetter G, et al. Treatment of nasopharyngeal carcinoma in

children and adolescents: definitive results of a multicenter study (NPC-91-GPOH). *Cancer* 2005; 104 (5):1083-1089.

10. Sun Y, Li WF, Chen NY, Zhang N, Hu GQ, Xie FY, et al. Induction chemotherapy plus concurrent chemoradiotherapy versus concurrent chemoradiotherapy alone in locoregionally advanced nasopharyngeal carcinoma: a phase 3, multicentre, randomised controlled trial. *Lancet Oncol* 2016 ;17(11):1509-1520.

11. Sahai P, Mohanti BK, Sharma A, Thakar A, Bhasker S, Kakkar A, et al. Clinical outcome and morbidity in pediatric patients with nasopharyngeal cancer treated with chemoradiotherapy. *Pediatr Blood Cancer* 2017; 64(2):259-266.

12. Claude L, Jouglar E, Duverge L, Orbach D. Update in pediatric nasopharyngeal undifferentiated carcinoma. *Brit J Radiol* 2019; 92(1102):20190107-20190110.

13. Uezono H, Indelicato DJ, Rotondo RL, Sandler ES, Katzenstein HM, Dagan R, et al. Proton therapy following induction chemotherapy for pediatric and adolescent nasopharyngeal carcinoma. *Pediatr Blood Cancer* 2019 ;66(12):e27990-e27992.