

## Clinical and Laboratory Findings of Cup-Like Nuclei in Blasts with FLT3 Mutation in Pediatric Acute Myeloid Leukemia: A Case Report

Kimberly Fe Joibi MD<sup>1</sup>, Salfarina Ibrahim MPath<sup>1</sup>, Nor Fadhilah Shafii MPath<sup>1</sup>, Siti Asmaa Mat Jusoh PhD<sup>1</sup>, Rapiaah Mustaffa MPath<sup>1</sup>, Muhammad Farid Johan PhD<sup>1</sup>, Wan Zaidah Abdullah MPath<sup>1,\*</sup>

1. Department of Hematology & Transfusion Medicine Unit, School of Medical Sciences, Universiti Sains Malaysia Health Campus, 16150 Kubang Kerian, Kelantan, Malaysia.

\*Corresponding author: Dr Wan Zaidah Abdullah, Department of Hematology, School of Medical Sciences, Universiti Sains Malaysia, Health Campus, 16150 Kubang Kerian, Kelantan, Malaysia. Email: [wzaidah@usm.my](mailto:wzaidah@usm.my). Orchid ID: 0000-0002-4008-6772

Received: 25 April 2019

Accepted: 05 August 2019

### Abstract

Biologically, Acute myeloid leukemia (AML) is highly heterogenous. AML with cup-like blast morphology variant has been reported to have important role in risk group stratification and treatment implications. In pediatric age group, this morphology and its clinical implication is rarely discussed. Although this morphology variant is not stated in World Health Organization (WHO) classification of Tumours of Haematopoietic and Lymphoid Tissues, it is associated with poor outcome from the association with other features. A 10-year old girl diagnosed to have AML with this morphology variant is reported in this study. Her laboratory features were hyperleucocytosis, high D-dimer, and blasts morphology of cup-like cells and few mimic the bilobed features of acute promyelocytic leukemia (APML). Further investigation showed clinical and laboratory features similar to what had been reported before in adults, including the presence of adverse marker of Fms-like tyrosine kinase 3 (FLT3) mutation. She was treated with chemotherapy, following which the bone marrow examination documented marrow in remission. Unfortunately, she succumbed to the disease complication from sepsis and marrow failure after few months of diagnosis. Haemato-morphologists might consider this unique morphological recognition and correlate it with other findings, including molecular testing for proper clinical evaluation. The blast feature and haematological findings could predict the clinical behaviour of this type of AML and guide the patient management. This morphological variant serves an important role especially if molecular testing is not available in some parts of the world or at the time of presentation when the result is still pending.

**Key words:** Acute myeloid leukemia, Blast, FLT3, Mutation

### Introduction

Acute myeloid leukemia (AML) is characterised by proliferation of blast cells of myeloid lineage and is highly both phenotypically and genotypically heterogeneous (1). Different subtypes of AML have different morphologies and certain morphological types are associated with certain typical clinical presentation, laboratory findings, immunophenotypic expressions, and cytogenetics and molecular findings. Distinct 'cup-like' nuclei morphology of blast cells had been reported in a number of AML cases worldwide. 'Cup-like' nuclei AML have

been described as blasts with distinctive nuclear invagination or indentation resembling 'cup' or 'fish mouth' encompassing at least 25% of the diameter of the nucleus with involvement of at least 10% of the blast cells (2). Based on the study under electron microscope by Kamoda et al., many mitochondria were concentrated within that nuclear pocket (3). This unique morphological entity; however, was not described in the latest World Health Organization (WHO) classification of tumours of haemopoietic and lymphoid tissues (2016) (4). The

clinical presentation and laboratory parameters of this case were compared with the cases reported in the literature.

### **Case report**

This was a case report presenting a pediatric patient diagnosed as AML with cup-like nuclear morphology of the blast cells. The patient was a 10-year old girl who presented with persistent fever associated with bilateral ear pain for 2 weeks. Physical examination revealed hepatosplenomegaly but no lymphadenopathy was detected. Her initial full blood count (FBC) showed anemia with hemoglobin level of 7.2 g/dl, thrombocytopaenia, platelet count of  $25 \times 10^9/l$ , and hyperleucocytosis with white cell count was  $107 \times 10^9/l$ . Her peripheral blood smear using Wright stain showed 80% blasts with distinct cuplike nuclear invagination involving more than 10% of the blasts. Few blasts demonstrated folded and clefted nuclei giving the appearance of bilobed-like features (Figure 1).

Using May-Grunwald Giemsa (MGG) staining, bone marrow aspirate showed hypercellular fragments and cell trails occupied by sheets of homogenous population of mononuclear cells. The blasts were moderate to large in size, with bluish cytoplasm and occasionally showed small granules. No Auer rods were found in the blast cells. In contrast, only few blast cells showed 'cuplike' features as compared to the finding in peripheral blood. There was very minimal differentiation of granulocytic lineage beyond blast stage. Cytochemistry staining for myeloperoxidase (MPO) was positive within the nuclear indentation, which was in agreement with previous studies (3, 5). In addition, cytochemical staining of the blast cells such as Periodic Acid Schiff (PAS) showed diffuse granular positivity, chloroacetate esterase was positive, and acid phosphatase staining showed pseudo-polar positivity.

Bone marrow trephine biopsy showed homogenous population of mononuclear

cells (blasts) occupying the marrow spaces (Figure 2). The flow cytometry (BD FACS CANTO II, BD Bio Sciences, San Jose, CA, USA) results showed positivity towards MPO and CD33, and heterogeneous positivity for CD13 and CD56. They were negative for CD34, HLA-DR, CD117, CD14, CD16, CD64, CD11b, and CD7 and notably negative for B and T cell markers (Figure 3).

A final diagnosis of AML-M1 was given based on French American British (FAB) classification. Her D-dimer levels were markedly increased with a level of more than  $20 \mu\text{g/mL}$ . Unfortunately, cytogenetic testing was failed as no metaphase spread was observed. Molecular tests for PML/RARA t (15;17), inversion 16, AML 1/ETO t (8;21) transcripts were all negative according to multiplex polymerase chain reaction (PCR). Internal tandem duplication (ITD) of Fms-like tyrosine kinase 3 (FLT3) was detected by Conformational Sensitive Gel Electrophoresis (CSGE) (Figure 4A) as described previously (6). DNA sequence analysis revealed in frame duplications of 66 base pairs in the region of exon 14 predicted to result in the tandem duplication of adjacent amino acid residues (Figure 4B).

In view of increasing total white cell count after admission from  $107 \times 10^9/L$  to  $224 \times 10^9/L$  within short time, she was initially planned for urgent leucopheresis. However, the procedure was not done as she underwent chemotherapy using AML protocol as soon as the diagnosis was established. She received 3 courses of chemotherapy for AML and among the drugs included in the regiment were IV cytarabine, IV daunorubicin, IV etoposide and triple intrathecal (IT) combination i.e. methotrexate, cytarabine and hydrocortisone. The first bone marrow examination (bone marrow aspirate) post induction chemotherapy was reported marrow in remission with blast count of 2%. Unfortunately, she succumbed to the

disease complication after few months of diagnosis from sepsis and marrow failure.

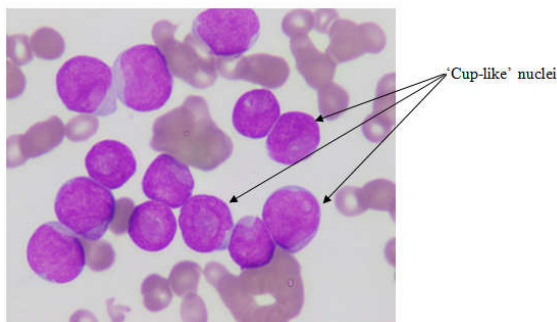


Figure 1. 'Cup-like' Nuclei Blasts in Peripheral Blood Smear (40X magnification)

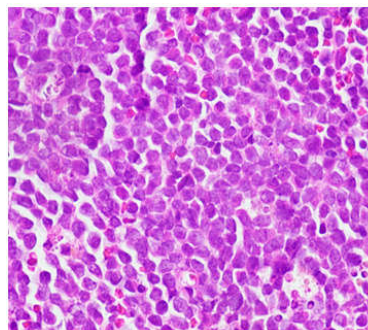


Figure 2. Bone marrow trephine biopsy (H and E staining) showing homogenous population of immature abnormal mononuclear cells (10X magnification)

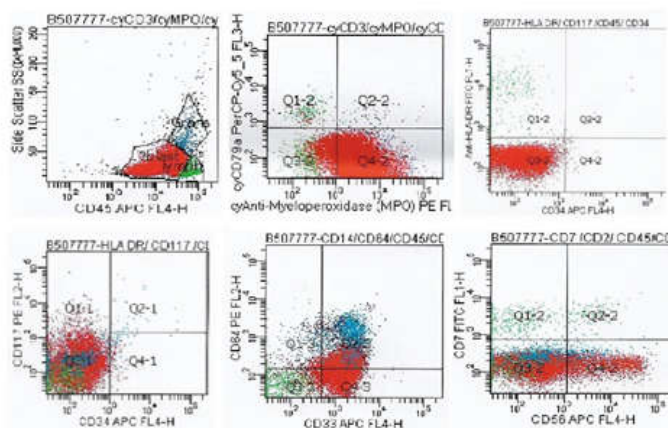


Figure 3: Flow cytometry findings of the 'cup-like' nuclei blasts showing positivity for CD33, CD56, and MPO, indicating myeloid lineage blasts

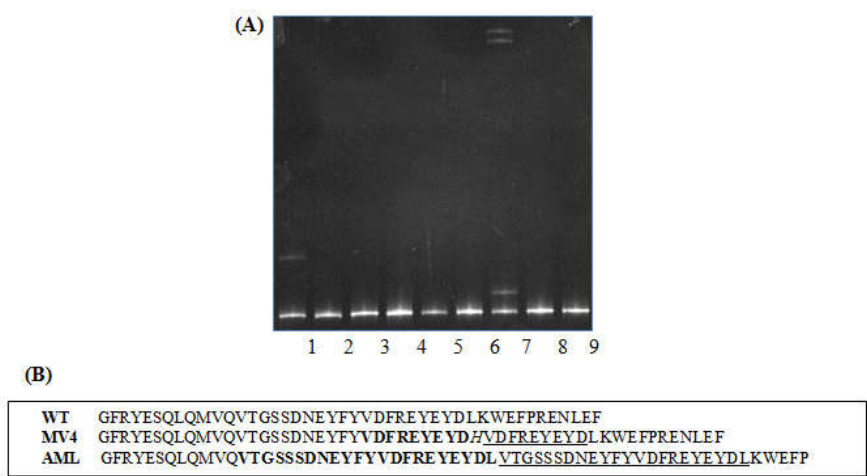


Figure 4. (A) Polyacrylamide gel illustrating profiles obtained following CSGE of AML patient with a *FLT3*-ITD (lane 1), AML negative *FLT3*-ITD (lanes 2-6), MV4-11 cell line (lane 7) and lanes 8 and 9 represent the wild-type *FLT3*. (B) Alignment of *FLT3* wild-type encoded sequence (WT) and mutant amino acid sequences in MV4-11 cell line, a *FLT3*-ITD positive AML cell line (MV4) and this patient

with *FLT3*-ITD (AML). The original wild-type and derivative ITD sequences are shown in bold and underlined texts, respectively. Italicized text indicates the addition of amino acid in MV4-11 cell line.

## Discussion

Several case reports have shown the association of 'cup-like' morphology with certain clinical, laboratory, and molecular findings, which could possibly address this morphology feature as a unique entity of AML. This peculiar morphology has been reported to have correlation with *FLT3*-ITD mutation and/or *NPM1* mutation (2,7). This case showed many similarities to laboratory features that have been reported associated with this particular morphology. Interestingly, the cup-like morphology was reported to occur more amongst female (2). In this case report, a female child was also involved.

Cup-like AML is typically associated with high total white count, in which this girl showed hyperleucocytosis, and was initially planned for urgent leucopheresis. It is associated with high blast count and *AML-M1* FAB classification (7,8), similar to the findings seen in this patient.

In this study, the cup-like nuclei was easily seen in peripheral blood smear; however; they were not obvious in this patient's bone marrow aspirate. This finding was also discussed in another report (7). This is perhaps due to different staining methods for bone marrow aspirate and peripheral blood smear that were used. Deep invaginations produce clefted nuclei giving a bilobed appearance. This may resemble a microgranular *AML-M3* (APML) by FAB classification. In addition APML may be wrongly considered as the blast cells of cup-like morphology were also negative for CD 34 and HLA-DR on flow cytometry, similar to the pattern encountered in APML cases. Moreover, D-dimer level was significantly elevated in this morphology variant. Cup-like AML has been reported to be associated with high D-dimer and low expression of both CD34 and HLA-DR (2). Excluding APML is imperative and urgent because of the

grave complication of disseminated intravascular coagulation (DIC), which is often present in APML. Molecular test for *PML/RARA* t(15;17) was done urgently, which turned out negative for this case thus excluding APML. *FLT3*-ITD was detected in this patient, and the morphology has a strong association with *FLT3*-ITD and *NPM1* mutations according to previous studies (2).

It was shown that *FLT3*-ITD especially in adults was linked with a generally poorer prognosis with higher risk of relapse, also worse disease-free survival and reduced overall survival (9). The emergence of targeted therapy towards *FLT3*, such as sorafenib can offer a better outcome in future (10). Sorafenib is part of many clinical trials for the treatment of *FLT3*/ITD AML, but there are only two drugs (i.e. midostaurin and gilteritinib (relapsed disease)) that are currently approved by Food and Drug Administration (FDA) for the treatment of *FLT3*/ITD AML in 2018. It is important to stress that genetic testing indication for *FLT3* and other mutations in AML is recommended irrespective of the blast morphology.

This article highlighted cup-like morphology in a pediatric AML patient with *FLT3*-ITD mutation, and to demonstrate the laboratory features in this case were found similar to the adult AML cases reported in the literatures. These features include hyperleucocytosis, high D-dimer levels, high blast cell count of *AML-M1* features (by FAB clarification) with low expression of CD34, and HLA-DR associated with *FLT3*-ITD and/or *NPM1* mutations. Noteworthy, *FLT3*-ITD and *NPM1* are key molecular findings for risk stratification in AML and hence their testing is recommended in all AML cases at the time of diagnosis irrespective of the blast morphology. This is probably the reason why WHO classification does not specifically describe this morphology

variant. FLT3 inhibitor such as midostaurin and Gilteritinib are indicated for AML patients harbouring a FLT3 mutation.

### Conclusion

FLT3-ITD and NPM1 mutations are associated with cup-like blasts morphology in AML cases. The morphology and genetic association as described in this paediatric patient showed similar clinical behaviour with adult cases. Although not exclusive for these genetic mutations, this morphology variant as a recognised entity of AML could alert the haemato-morphologists and clinicians on this association. However, performing genetic testing and other investigation modalities as recommended in WHO classification is still the mainstay in diagnosing and prognosticate AML and other hematopoietic malignancies.

### Acknowledgement

Acknowledgments are due to Hospital Universiti Sains Malaysia for allowing this case to be presented and providing the necessary data.

### Conflicts of interest

The authors declare no conflicts of interest for this manuscript.

### References

1. Hoffbrand AV, Moss PAH. Essential Haematology. 6th ED. United Kingdom: Wiley-Blackwell; 2011; 179-190.
2. Chen W, Konoplev S, Medeiros LJ, Koeppen H, Leventaki V, Vadhan-Raj S, et al. Cuplike nuclei (prominent nuclear invaginations) in acute myeloid leukemia are highly associated with FLT3 internal tandem duplication and NPM1 mutation. *Cancer* 2009; 115(23): 5481-5489.
3. Kamoda Y, Shimomura D, Tsuda K, Hayashida M, Fukutsuka K, Izumi K, et

- al. Acute myeloid leukemia with “cup-like” nuclear morphology, highlighting the electron microscopic features. *Tenri Medical Bulletin* 2017; 20(1): 26-37.

4. WHO classification of haematopoietic and lymphoid tissues (Revised 4th Edition) 2016.

5. Okano A, Inaba T. Acute Myeloid Leukemia—Cuplike: Characteristic Peroxidase Staining Pattern. *Int J Hematol* 2007; 85(3): 185-185.

6. Yunus NM, Johan MF, Ali Nagi Al-Jamal H, Husin A, Hussein AR, Hassan, R. Characterisation and clinical significance of FLT3-ITD and non-ITD in Acute Myeloid Leukaemia patients in Kelantan, Northeast Peninsular Malaysia. *Asian Pac J Cancer Prev* 2015; 16(12): 4869-4872.

7. Park BG, Chi HS, Jang S, Park CJ, Kim DY, Lee JH, et al. Association of cup-like nuclei in blasts with FLT3 and NPM1 mutations in acute myeloid leukemia. *Ann Hematol* 2013; 92(4): 451-457.

8. Kroschinsky FP, Schäkel U, Fischer R, Mohr B, Oelschlaegel U, Repp R, et al. Cup-like acute myeloid leukemia: New disease or artificial phenomenon? *Haematologica* 2008; 93(2): 283-286.

9. Ziai JM, Siddon AJ. Pathology consultation on gene mutations in acute myeloid leukemia. *Am J Clin Pathol* 2015; 144(4): 539-554.

10. Antar A, Otrrock ZK, El-Cheikh J, Kharfan-Dabaja MA, Battipaglia G, Mahfouz R, et al. Inhibition of FLT3 in AML: a focus on sorafenib. *Bone Marrow Transplant* 2017; 52(3): 344-351.