

Metastatic Melanoma (Secondary Malignancy) after Recovery from Acute Lymphoblastic Leukemia in a 10-year-old Girl: a case report

Saeed Yousofian MD¹, Ghasem Miri-Aliabad MD², Tahere Rostami MD³, Mitra Mehrazma MD⁴, Pardis Nematollahi MD^{5,*}

1. Children and Adolescent Health Research Center, Isfahan University of Medical Sciences, , Isfahan, Iran

2. Children and Adolescent Health Research Center, Zahedan University of Medical Sciences, Zahedan, Iran.

3. Tehran University of Medical Sciences and Health Services, Tehran, Iran.

4. Oncopathology Research Center, Tehran University of Medical Sciences, Tehran, Iran.

5. Cancer Prevention Research Center, Isfahan University of Medical Sciences, Isfahan, Iran.

*Corresponding author: Dr Pardis Nematollahi, Fellowship of hematopathology at Shiraz university of medical science, Assistant professor of pathology, Cancer Prevention Research Center, Isfahan University of Medical Sciences, Isfahan, Iran. Email: pardis.nematolahy@med.mui.ac.ir. Orchid ID:0000000276684280

Received: 23 July 2016

Accepted: 22 September 2018

Abstract

Acute lymphoblastic leukemia is the most common malignancy in children with a 5-year survival rate, accounting for 80% of cases. Melanoma is rare in children and has been reported as a sporadically occurring secondary malignant neoplasm in children with acute lymphoblastic leukemia. This study presented a 10-year-old Iranian child with pre-B-cell acute lymphoblastic leukemia that was diagnosed at age 6. She was fully recovered after 2 years of treatment. One year and six months after cessation of treatment, she was referred with a 1×2 cm mass in her right parietal region of scalp. Biopsy of the lesion confirmed the diagnosis of malignant melanoma. Computed tomography scan of the chest and abdomen also confirmed extensive liver metastasis which was corroborated by liver biopsy. Bone scan also revealed bone metastases. Early diagnosis and treatment of these tumors is extremely important and these patients should be closely monitored and undergo regular physical examination.

Key words: Precursor Cell Lymphoblastic Leukemia-Lymphoma, Melanoma, Cutaneous Malignant, Child, Cutaneous Malignant Melanoma, Precursor Cell Lymphoblastic Leukemia-Lymphoma

Introduction

Ever-increasing advances in the treatment of pediatric malignancies have improved patients' prognosis and increased their survival rate. Improvement in survival of these patients and increase of malignancy survivors population put these children at risk of late effects and secondary malignant neoplasm(1). Acute lymphoblastic leukemia (ALL) is the most common malignancy in children and now its overall survival rate is more than 80% (2). However, late consequences arising from the disease and its treatment, including secondary malignant neoplasm is also increasing in these patients. The most common secondary malignant neoplasm includes central nervous system tumors, sarcomas, thyroid and parathyroid

carcinomas, and acute myeloid leukemia (3). Malignant melanoma is uncommon as a secondary malignant neoplasm in children. Annual incidence of melanoma in healthy children of ages 10 to 14 years and 15 to 19 years are 0.4 and 1.7; respectively, per 100,000 people (4). However, as a secondary neoplasm, melanoma is more common in children with hereditary retinoblastoma, and 10% of mortality associated with secondary malignant neoplasm is caused by this tumor (5).

In Lutz Loning et al.'s study on 5006 children with acute lymphoblastic leukemia, it was found that secondary malignant neoplasm occurred in 52 children, and melanoma was observed only

in one case(2). This paper introduced a 10-year-old Iranian girl with metastatic melanoma who developed ALL one year after the cessation of treatment.

Case report

A 10-year-old Iranian girl was diagnosed with pre-B-cell ALL at age 6 in 2011, and underwent chemotherapy in Ali Asghar Hospital, Pediatric Oncology Department, Tehran, Iran. She was treated with BFM2002 protocol without radiotherapy. She was fully recovered after 2 years of treatment. Bone marrow examination, cerebrospinal fluid cytology, and abdomen and pelvis ultrasound were normal and without skin lesion at admission. Physical examinations and laboratory tests were completely normal during monthly follow-ups. One year and six months after cessation of treatment, she was referred with a 1×2 cm mass in her right parietal region of her scalp. Biopsy of the lesion and immunohistochemistry staining confirmed the diagnosis of malignant melanoma (Figure 1, 3, 4). At that time, complete blood cell count, erythrocyte sedimentation rate, liver and kidney function tests, biochemistry, and coagulation tests were normal except for a lactate dehydrogenase (LDH) rise (LDH: 1970 IU/dl). Computed tomography scan of the chest and abdomen confirmed extensive liver metastasis (Figure 2) which was corroborated by liver biopsy. Bone scans also confirmed bone metastases. Observation of metastatic cells and flowcytometry of bone marrow did not show leukemia recurrence. The patient was advised to perform chemotherapy in the center, but she did not come back for follow-up.

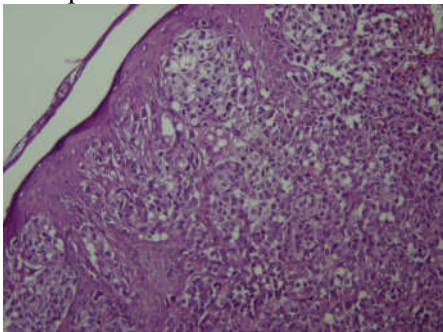


Figure-1. Malignant Melanoma , skin nodule. Atypical nests of melanocytes in dermis and basal layer with adjacent intraepithelial spread (H&E, 400X).

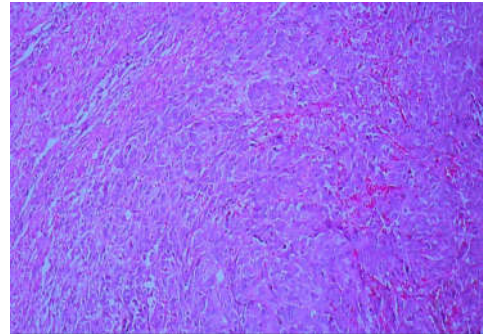


Figure-2. Metastatic Melanoma in liver. Large cells with vesicular nuclei, prominent nucleoli and eosinophilic cytoplasm. Normal liver is in upper left part of the figure. (H&E, 400X).

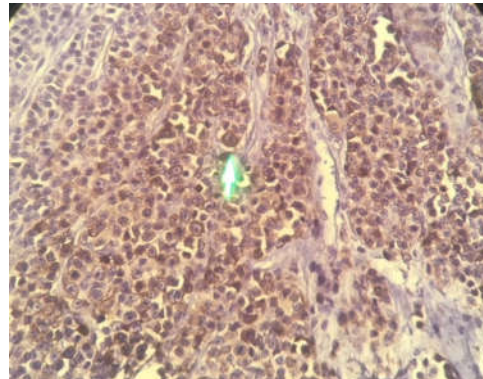


Figure-3. Immunohistochemical staining for HMB45 .show positive results (400X).

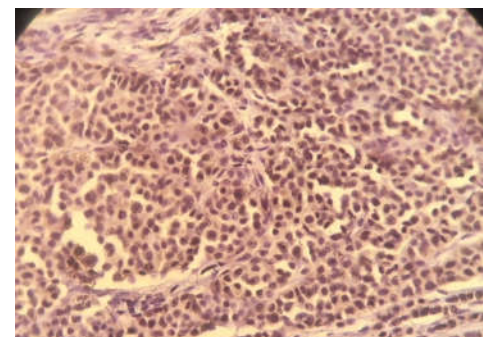


Figure-4. Immunohistochemical staining for S100 .show positive results (400X).

Discussion

Growing population of cancer survivors is associated with delayed consequences, which some are related to the occurrence

of secondary neoplasm as extremely serious event following treatment of the primary cancers. However, other factors such as age, genetics, type of the primary carcinoma, and environmental factors are involved in its occurrence (1). The risk of secondary malignant neoplasm is increased 10 times in these individuals, compared with the general population (6). Primary malignancies that may be associated with secondary malignant neoplasm include leukemia, lymphoma, retinoblastoma, medulloblastoma, craniopharyngioma, and neuroblastoma. Genetic predisposition and factors associated with treatment, including chemotherapy and radiation therapy, are the major risk factors in the pathogenesis of secondary malignant neoplasm (3). Malignant melanoma consists of 1-3% of the total children cancers and almost 2% of all malignant melanoma before the age of 20. Risk factors for melanoma occurrence include a positive family history, xerodermapigmentosum, increased number of acquired melanocytic nevi, atypical nevus, excessive sun exposure, giant congenital nevus, and immunodeficiency (7). Metastases raised from these malignancies can involve any organ, including lungs, lymph nodes, subcutaneous tissue, liver, and brain. High LDH in these patients is a poor prognosis factor (8). Kimball Dulton et al., studied 1,597 patients with ALL and found only 13 cases with secondary malignant neoplasm, of which 8 cases were caused by radiation (5). In a study on secondary malignancies in survivors of cancerous children by Corporn CA et al., only 11 of 172 cases were melanoma, of them 6 cases had distant or lymphatic metastases at diagnosis and 4 cases occurred in the radiation field (9). Neglia et al., studied 13,581 survived cancerous children and found 298 cases with secondary neoplasm, of them 64 cases occurred in leukemic children while only 5 cases were due to melanoma. In aforementioned study, the estimated cumulative incidence of

secondary neoplasms, 20 years after diagnosis, was 3.2% (1). Karlsson et al., showed that out of 134 children with cutaneous malignant melanoma, only 2 cases were less than 12 years. They also found that the cutaneous malignant melanoma had occurred in the head and neck region of in only 3% of girls, and higher mortality was observed in patients less than 16 years old (10). In a systemic review, Braams et al., showed that 2.6% of cancer survivors developed secondary malignant neoplasm, 5.3% of all neoplasm was due to melanoma, and melanoma occurs in 0.14% of all cancer survivors (4). Despite the rarity of melanoma in children, this tumor is aggressive in adults. Although there is no predisposing factor in the majority of children and adolescents with melanoma, any suspicious skin lesion should be immediately evaluated. Informing patients, parents, physicians, and health care providers about secondary malignant neoplasm and its risk factors, preventive measures, and early diagnosis of these cases in all cancer survivors are of tremendous importance, so careful and long-term follow-up is recommended. In addition, in children who are genetically predisposed or have a risk factor for the incidence of secondary neoplasms, treatment protocols should be modified individually without affecting the performance of the initial treatment.

Conclusion

Early diagnosis and treatment of these tumors is extremely important and these patients should closely be monitored and undergo regular physical examination.

Conflicts of interest

The authors declare no conflicts of interest for this manuscript.

References

1. Neglia JP, Friedman DL, Yasui Y, Mertens AC, Hammond S, Stovall M, et al. Second malignant neoplasms in five-

year survivors of childhood cancer: childhood cancer survivor study. *J Natl Cancer Inst* 2001;93(8):618-29.

2. Loning L. Secondary neoplasms subsequent to Berlin-Frankfurt-Munster therapy of acute lymphoblastic leukemia in childhood: significantly lower risk without cranial radiotherapy. *Blood* 2000;95:2770-5.

3. Vázquez E, Castellote A, Piqueras J, Ortuño P, Sánchez-Toledo J, Nogués P, et al. Second malignancies in pediatric patients: imaging findings and differential diagnosis. *Radiographics* 2003;23(5):1155-72.

4. Braam K, Overbeek A, Kaspers GJ, Ronckers CM, Schouten-van Meeteren AY, Dulmen-Den Broeder V, et al. Malignant melanoma as second malignant neoplasm in long-term childhood cancer survivors: A systematic review. *Pediatr Blood Canc* 2012;58(5):665-74.

5. Kimball Dalton V, Gelber RD, Li F, Donnelly MJ, Tarbell NJ, Sallan SE. Second malignancies in patients treated for childhood acute lymphoblastic leukemia. *J Clin Oncol* 1998;16(8):2848-53.

6. Pizzo PA, Poplack DG. Principles and practice of pediatric oncology: Lippincott Williams & Wilkins; 2015.

7. Abbott MB, Vlasses CH. Nelson textbook of pediatrics. *JAMA* 2011;306(21):2387-8.

8. Neier M, Pappo A, Navid F. Management of melanomas in children and young adults. *J Pediatr Hematol Oncol* 2012;34:S51-S4.

9. Corpron CA, Black CT, Ross MI, Herzog CS, Ried HL, Lally KP, et al. Melanoma as a second malignant neoplasm after childhood cancer. *Am J Surg* 1996;172(5):459-62.

10. Karlsson P, Boeryd B, Sander B, Westermarck P, Rosdahl I. Increasing incidence of cutaneous malignant melanoma in children and adolescents 12–19 years of age in Sweden 1973–92. *Acta Derm Venereol* 1998;78(4):289-92.