

An Unfavorable Metastatic Site at Initial Diagnosis in a 2-year-old Boy with Neuroblastoma

Saeed Yousofian MD¹, Mohammad Zolfaghari MD^{2*}, Maryam Baghbeheshti MD², Shadrooz Moazzam MD³

1. Child Growth and Development Research Center, Research Institute for Primordial Prevention of Non-communicable Disease, Isfahan University of Medical Sciences, Isfahan, Iran

2. Student Research Committee, Shahid Sadoughi University of Medical Sciences, Yazd, Iran.

3. Student Research Committee, Faculty of Medicine, Shahrekord University of Medical Sciences, Shahrekord, Iran.

*Corresponding author: Dr. Mohammad Zolfaghari, Student Research Committee, Shahid Sadoughi Hospital, Ebn-e-Sina Ave, Shahid ghandi Blvd, Yazd, Iran. E-mail: mhmzolfaghari89@gmail.com. ORCID ID: 0000-0002-8695-2357

Received: 12 October 2019

Accepted: 25 June 2022

Abstract

Neuroblastoma (NB) is considered one of the malignant tumors of the nervous system which originates from primordial neural crest cell and is known as the most common extra-cranial solid tumor in childhood. This tumor which is often intra-abdominal, metastases in various sites including the skull, long bones, liver, bone marrow and lymph nodes, but lung metastasis at initial diagnosis is rare (0.2-3.7%). Here, the authors reported a two-year-old boy who referred to Imam Hussein Children's Hospital affiliated to Isfahan University of Medical Sciences, Iran in April 2017 with complaint of abdominal pain and distension along with diarrhea, vomiting and fever. In physical examination, a palpable mass was observed at the right side of the abdomen, that in further studies, NB with lung metastasis along with poorly differentiated, low MKI, positive MYCN amplification was reported. This is the first documented case report of NB with lung metastasis from Iran. In conclusion, although lung is considered as an unfavorable metastatic site for NB, in high grade and poor prognosis cases, this organ should also be examined in metastatic site examinations. Therefore, lung High-resolution computed tomography (HRCT) is introduced as the gold standard modality for this work.

Keywords: Lung, Metastasis, MYCN Protein, Neuroblastoma

Introduction

With progress in the treatment of pediatric Neuroblastoma (NB) is considered one of the malignant tumors of the nervous system which is known as the most common extra-cranial solid tumor in childhood (1). This poorly differentiated tumor is created from embryonic cells which originate from the sympathetic nervous system and are known as primordial neural crest cell (2). The annual incidence of NB is about 10 per million live births that forms about 10 percent of total cancers in childhood and leads to about %15 of their mortality in this period (3). Diagnosis is done according to the patient's history, physical examination, as well as various imaging methods including Magnetic Resonance Imaging (MRI),

Computerized Tomography (CT) scan, Ultrasound (US) scan, Meta-Iodo Benzyl Guanidine (MIBG) scan. Presence of Catecholamines such as Vanillylmandelic Acid (VMA) and Homovanillic Acid (HVA) in the patient's urine along with the increase of Serum Neuron-Specific Enolase (NSE) level can also be helpful (4). Although a large number of this malignant tumor is intra-abdominal, it may exist anywhere in the neural system, among which skull, long bones, liver, bone marrow and lymph nodes can be mentioned (5-7). Although this disease has previously been reported with metastasis in bone and other common sites, but lung metastasis has been rare and this is the first documented case report of NB with lung metastasis from Iran.

Case Report

A 21-month-old boy with healthy past medical history referred to Imam Hussein Children's Hospital affiliated to Isfahan University of Medical Sciences, Iran in April 2017, complaining from abdominal pain and distension along with diarrhea and vomiting which had started 3-4 days ago and then had intensified. In physical examination, there was a 38.5 °C fever, and a palpable mass could be touched at the right side of the abdomen to 6 cm under costal margin, which was completely firm and painless; and had no tenderness in touching. Other vital signs and examinations of the patient were normal. Full results of these tests along with the next complementary tests are indicated in Table I. In abdomino-pelvic Ultrasound, the image of a hypoechoic mass with an approximate size of 112×93 mm containing echogenic focus (in favor of calcification) and outstanding internal vascularity from the upper and mid pole of the right kidney was seen that had caused replacement of hepatic parenchyma upward. Other findings of bladder, liver, kidneys, and gallbladder were normal, and there was no evidence of hepatosplenomegaly. After complementary imaging, abdomino-pelvic CT scan was conducted in which there was a large mass with heterogeneous enhancement with approximate diameter of 145 mm in right pararenal space (retroperitoneal) with extension to the kidney at the same side, that had crossed mid-line, and vascular encasement was seen in it but there was no obvious calcification (Figure 1-A). Retroperitoneal lymphadenopathy was also observed which was accompanied by a little mild free fluid in pelvis. No other pathologic finding was observed in bladder, liver, kidneys, gallbladder, spleen and pancreas. Also, the evidence of two nodules with a diameter of 12 mm was obvious in right lung that were in favor of metastatic lesion of the mass (Figure 1-B). All the above clinical, laboratory and imaging findings put Wilm's tumor and

NB invading the right kidney at the top of differential diagnosis list.

Due to tense abdomen and change in defecation state of the patient, abdominal X-ray was requested, and according to the surgeon's opinion, due to compressive effect of the mass on colon and existence of excessive gas inside the colon, the patient became candid for surgical debulking of the tumor. A mass with an approximate size of 145×85 mm with estimated weight of 430gr was pulled out along with the right kidney of the patient. After right nephrectomy, pathologic examinations showed poorly differentiated NB with calcification that was a low mitotic-karyorrhectic index (<100 per 5000 Cells, <2%) (Figure2). Then further Immunohistochemistry (IHC) studies were done on the tumor and Neuron-Specific Enolase (NSE) and Chromogranin (tumor) markers were positive, and WT1, Desmin, LCA and CD99 were negative. Therefore, Wilm's tumor as a differential diagnosis was removed, and NB with lung metastasis was confirmed as the main disease.

Bone Marrow Aspiration was conducted for the patient that trilineage hematopoiesis with maturation without evidence of metastasis was reported. Whole Body Bone scan was also conducted for him that the study was highly suspicious for metastatic involvement of distal left femur and proximal right tibia, also less likely lumbar vertebrae and anterior arch of the almost left 6th rib. Moreover, genetic examinations showed that genomic amplification of gene MYCN was positive in this patient. Nonetheless, according to Children's Oncology Group (COG) Risk Group Assignment for NB (8), patient is categorized in High Risk Group. Chemotherapy according to the Children's Cancer Group (CCG) protocol-3891 was started including the cytotoxic drugs cyclophosphamide, etoposide, doxorubicin, and cisplatin.

After four periods of chemotherapy and passage of about four months since the start

of clinical manifestations of the patient, CT scan was again conducted that the mass size had been reduced to 98×6 mm, but vascular encasement and compressive effect on adjacent organs could still be observed. The patient was transferred to the operation room for the second time for mass resection, but due to inferior vena cava (IVC) invasion, there wasn't the possibility of complete removal of the mass. So, the patient was admitted to the hospital for further chemotherapy and is currently continuing chemotherapy.

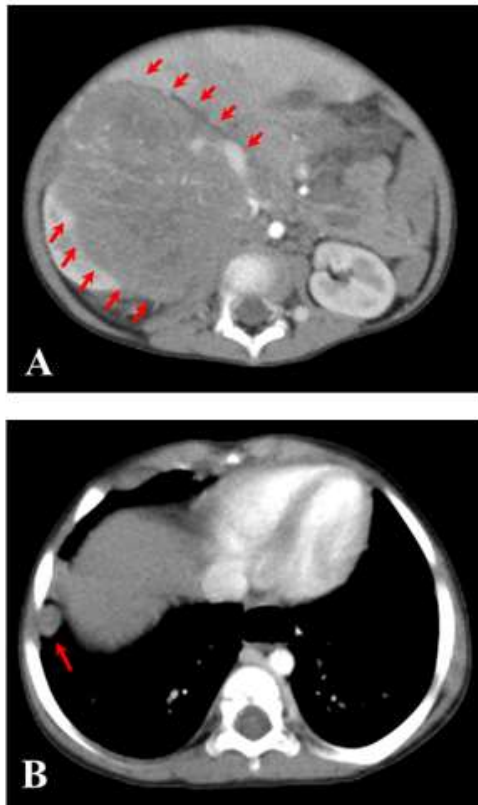

Figure 1. Axial CT Scan of the chest and abdomen without contrast-enhanced. (A): Right heterogeneous enhancing mass lesion with extension to the kidney at the same side, that had crossed mid-line with no obvious calcification. (B): Two nodules with a diameter of 12 mm in right lung showing secondary pulmonary metastatic lesions of mass.

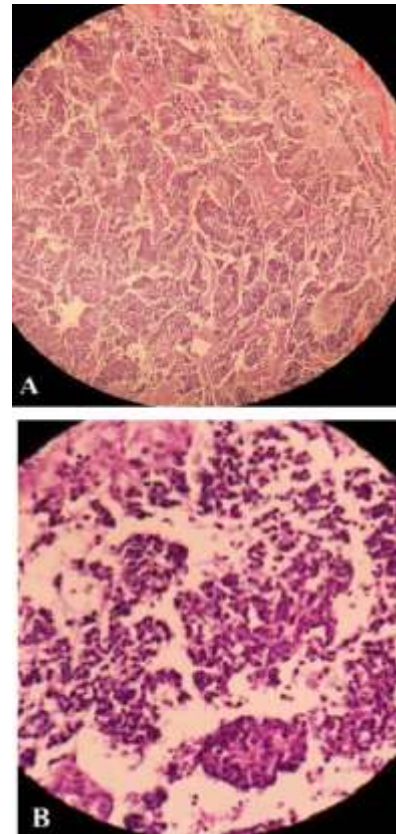


Figure 2. Photomicrograph showing histological section from tumor. (A): The thin fibrous septa separate the solid packed tumor cells. (B): The tumor cells having scanty eosinophilic cytoplasm and small round dark nuclei. (H&E stain, 100x, 400x)

Table I. Results of laboratory tests of patient

Test	Result	Reference
WBC	8200	5.0 - 14.5 ($\times 10^3/\mu\text{L}$)
Hb	8.6	11.5 - 14.5 (g/dl)
PLT	349,000	150,000 - 450,000 ($/\mu\text{L}$)
ESR	4	0 - 20 (mm/h)
CRP	neg.	Qualitative
LDH	2447	500-920 (U/L)
Ferritin	1178	36-84 (ng/ml)
Urine HVA	pos.	Qualitative
Urine VMA	pos.	Qualitative

WBC: White blood cell, Hb: Hemoglobin, PLT: Platelet, ESR: Erythrocyte sedimentation rate, CRP: C-reactive protein, LDH: Lactate dehydrogenase, HVA: Homovanillic Acid, VMA: Vanillylmandelic Acid, pos: positive, neg: negative

Discussion

Usually, NB is manifested by a palpable abdominal mass, and there may be non-specific sign and symptoms such as abdominal pain, bone pain, intractable diarrhea, fever, orbital ecchymosis, cerebellar ataxia (9). In other extra-cranial solid cancers in children, including Ewing sarcoma, osteosarcoma, and Wilm's tumor, lung metastasis is common but in NB, which is known as the first common malignant tumor in childhood and metastases in various sites in the body such as bones, liver, bone marrow and lymph nodes is common but lung metastasis is rare, and only a few cases have been reported (3, 4, 10, 11). The incidence of lung metastasis in NB is so uncommon and something about 0.2-3.7% (3). However, considering that lung was not examined as an involved organ in patients with NB, routinely so far, thus its true incidence rate cannot be reported definitely. But it must be noted that lung metastasis can represent the tumor's being aggressive at the first diagnosis. Lung metastases exist in various forms including pleural effusion and thickening, parenchymal metastasis, and pleural-based nodules; that in this patient according to CT scan report, a 12 mm nodule was observed in the right lung.

In 2012, Tokmak H et al. (12) introduced a 3.5-year-old boy complaining of fever and cough and in physical examination he had a mass with the size 9*7 cm in right upper quadrant of the abdomen. In CT scan, NB with lung metastasis had been reported. Also in another report from Austria, Bauchinger S. et al. (4) in 2014 introduced a nine-year-old girl with diagnosis of primary renal NB metastasizing into lungs and liver. Given that 65% of NBs initially refer by a mass in kidney, adrenal glands, or abdomen, its differentiation with Wilm's tumor is so important, such that in the study by Bauchinger S et al, considering thrombus formation and existence of kidney mass, initially the patient was undergone chemotherapy with

diagnosis of Wilm's tumor, and after non response to Wilm's tumor therapy, the patient was examined again and through biopsy, NB with lung metastasis was diagnosed. Therefore, this misdiagnosis must be paid much attention. In the present case also, given the mentioned ultrasound and CT scan reports, Wilm's tumor was at the top of differential diagnosis list, but with further examinations and biopsy, NB diagnosis was confirmed.

The success rate in NB treatment depends on the stage of the disease at diagnosis time. Bone marrow transplantation, multi-agent chemotherapy, and surgical excision are the methods used in NB treatment. Although this patient was undergone surgery, the surgeon could not remove the whole tumor due to IVC invasion, and debulking surgery was done. After that, the patient was undergone chemotherapy.

One of the biological risk factors introduced in 1985 for the first time showed that MYCN gene amplification which is located on Chromosome 2, increases the probability of metastasis to unfavorable sites such as brain and lung and worsens the prognosis of this tumor (10, 13). So, given that MYCN amplification was positive in this patient, lung metastasis was not unexpected. Dubois SG et al. (14) showed that aggressive tumors increase LDH serum level and these tumors often have positive MYCN gene amplification and adrenal origin; all these were observed in the present case.

In conclusion, given that lung is considered as an unfavorable metastatic site for NB, therefore, in routine examinations, doctors do not pay attention to the lung. Although in this study also the existence of lung metastases was recognized accidentally, this organ should not be considered as an imaginable site in metastatic site examinations, especially in high-grade cases. Given that proving small lesions seems difficult in the ordinary graph, so lung High-resolution computed tomography (HRCT) is introduced as the

gold standard modality. Also, the presence of a primary mass in the abdomen and around the kidneys may cause the therapeutic team to make a mistake in differentiation between Wilm's tumor and NB; thus, differentiation of these two diseases is very important. Considering that NB incidence is often as an intra-abdominal mass, therefore, using ultrasound as a screening tool can be helpful. Performing further examinations such as measuring VMA and HVA level in all patients who are going to undergo treatment with a possible diagnosis of Wilm's tumor seems important. Biopsy of the lung (if possible) helps definite diagnosis of the disease very much.

Conclusion

In conclusion, although lung is considered as an unfavorable metastatic site for NB, in high grade and poor prognosis cases, this organ should also be examined in metastatic site examinations. Therefore, lung High-resolution computed tomography (HRCT) is introduced as the gold standard modality for this work.

Conflicts of Interest

The authors declare that there is no conflict of interests regarding the publication of this article.

References

1. Tsubota S, Kadomatsu K. Origin and mechanism of neuroblastoma. *Oncoscience* 2017; 4(7-8):70-72.
2. Zheng T, Ménard M, Weiss WA. Neuroblastoma Metastases: Leveraging the Avian Neural Crest. *Cancer Cell* 2017; 32(4):395-397.
3. Ödek Ç, Kendirli T, Pekpak E, Yaman A, Adaklı-Aksoy B, Dinçaslan H, et al. An unusual case of neuroblastoma: a 17-year-old adolescent presented with bilateral diffuse lung metastasis at initial diagnosis. *Turk J Pediatr* 2016; 58(1):86-89.
4. Bauchinger S, Lackner H, Schwinger W, Sovinz P, Benesch M, Sorantin E, et al. Primary renal neuroblastoma metastasizing into liver and lungs with tumor thrombus extension into the right atrium. *Klin Padiatr* 2014; 226(6-7):369-371.
5. Abbasi MR, Rifatbegovic F, Brunner C, Ladenstein R, Ambros IM, Ambros PF. Bonemarrow from neuroblastoma patients: an excellent source for tumor genome analyses. *Mol Oncol* 2015; 9(3):545-554.
6. Morgenstern DA, London WB, Stephens D, Volchenboum SL, Hero B, Di Cataldo A, et al. Metastatic neuroblastoma confined to distant lymph nodes (stage 4N) predicts outcome in patients with stage 4 disease: A study from the International Neuroblastoma Risk Group Database. *J Clin Oncol* 2014; 32(12):1228-1235.
7. Lee S, Qiao J, Paul P, O'Connor KL, Evers MB, Chung DH. FAK is a critical regulator of neuroblastoma liver metastasis. *Oncotarget* 2012; 3(12):1576-1587.
8. Henderson TO, Bhatia S, Pinto N, London WB, McGrady P, Crotty C, et al. Racial and ethnic disparities in risk and survival in children with neuroblastoma: a Children's Oncology Group study. *J Clin Oncol* 2011; 29(1):76-82.
9. Schulte JH, Eggert A. Neuroblastoma. *Crit Rev Oncog* 2015; 20(3-4): 245-270.
10. Farmakis SG, Siegel MJ. Intrarenal neuroblastoma with pulmonary metastases mimicking a Wilms tumor. *J Pediatr Surg* 2014; 49(12):1864-1866.
11. Menager N, Quarello E, Capelle M, Lacroze V, Coze C, De Lagausie P, et al. Prenatal diagnosis of atypical adrenal neuroblastoma with pulmonary metastases is possible: Impact on the assessment of prenatal prognosis. *Diagn Interv Imaging* 2012; 93(7-8):632-634.
12. Tokmak H, Kebudi R, Gümüş T, Demirkol O. Pulmonary metastasis in neuroblastoma at initial diagnosis. *J Pediatr Hematol Oncol* 2012; 34(7):581-582.
13. Olsen RR, Otero JH, García-López J, Wallace K, Finkelstein D, Rehg JE, et al. MYCN induces neuroblastoma in primary neural crest cells. *Oncogene* 2017; 36(35):5075-5082.

14. Dubois SG, London WB, Zhang Y, Matthay KK, Monclair T, Ambros PF, et al. Lung metastases in neuroblastoma at initial diagnosis: A report from the International Neuroblastoma Risk Group (INRG) project. *Pediatr Blood Cancer* 2008; 51(5):589-592.