



Tehran University of Medical
Sciences Publication
<http://tums.ac.ir>

Iran J Parasitol

Open access Journal at
<http://ijpa.tums.ac.ir>



Iranian Society of Parasitology
<http://isp.tums.ac.ir>

Case Report

Endoscopic Recognition and Management of *Trichuris vulpis* Induced Colitis in Three Dogs: A Case Report

*Sandhya Bhavani Mohan¹, Kavitha Santhanakumar², Abid Ali Bhat³

1. Department of Clinics, Madras Veterinary College, Tamil Nadu Veterinary and Animal Sciences University, Chennai -7, Tamil Nadu, India
2. Department of Veterinary Clinical Medicine, Madras Veterinary College, Tamil Nadu Veterinary and Animal Sciences University, Chennai -7, Tamil Nadu, India
3. Department of Veterinary Clinical Medicine, College of Veterinary Medicine and Animal Sciences, University of Gondar, Ethiopia

Received 20 Nov 2021
Accepted 11 Jan 2022

Keywords:
Haematochezia;
Tenesmus;
Colitis;
Whipworms;
Endoscopy;
Therapy

***Correspondence
Email:**
sanjuri02@gmail.com

Abstract

Trichuris vulpis is a relatively common cause of canine large bowel disease leading to chronic diarrhea. Faecal analysis is negative most of the times due to long prepatent period and eggs may be shed intermittently. This case study done at Madras Veterinary College, Chennai, Tamil Nadu, India from 2014 to 2018 describes the usefulness of endoscopy in diagnosing the colitis due to presence of *T. vulpis* worms. Three dogs presented with haematochezia and tenesmus were subjected to detailed clinical examination. As the faecal examination was negative and there was no improvement on initial therapy endoscopy was performed. Numerous *T. vulpis* whipworms were found attached to the colon mucosa on endoscopic examination. Multiple bleeding ulcerated sites were observed throughout the colon. The dog was treated with oral febantel, praziquantel and pyrantel combination tablets (Drontal Plus). Clinical improvement was observed within a week.

Introduction

Trichuris vulpis infections are usually asymptomatic, but the presence of high worm burdens in the large bowel

may cause the occurrence of haemorrhagic colitis due to the continuous damage to the mucosa as the head of the worm is embedded



Copyright © 2022 Bhavani Mohan et al. Published by Tehran University of Medical Sciences.
This work is licensed under a Creative Commons Attribution-NonCommercial 4.0 International license.
(<https://creativecommons.org/licenses/by-nc/4.0/>). Non-commercial uses of the work are permitted, provided the original work is properly cited

into the mucosa and moves in search of blood and fluid (1). As the faecal examination is negative in most of the *Trichuris vulpis* infections Gastrointestinal (GI) endoscopy can be used for direct visualising (2).

This case study describes the usefulness of endoscopy in diagnosing the colitis due to presence of worms.

Case Reports

The following dogs were brought to the Small Animal Outpatient Unit of Madras Veterinary College, Chennai, Tamil Nadu, India during the year 2014 to 2018 with predominately lower gastrointestinal signs.

Dog 1: A one year old male German shepherd weighing 23 kg was brought with the history of hematochezia, tenesmus after defecation, intermittent vomiting and diarrhoea for past 15 days. Faeces were scanty, mucoid mixed with blood. It was treated by field vet with antibiotics with no improvement in the condition.

Dog 2: A two year old male Doberman weighing 28 kg had tenesmus and haematochezia for past one month.

Dog 3: A one year old female German shepherd weighing 20 kg was presented with haematochezia and tenesmus.

All the three dogs were active and alert on the day of presentation and the physical examination revealed normal vital signs. Haematological investigation revealed anaemia and Serum biochemistry had no remarkable changes. Faecal examination by floatation technique was negative for parasites. Since there was no marked improvement with initial treatment with metronidazole (15 mg /kg body weight), pantaprazole (1 mg /kg body weight) and fluid therapy, the dogs were referred for endoscopic investigation. Since the dogs were client owned, prior written consent from the owners were obtained for the performance of endoscopic procedures.

Colonoscopy was performed with a flexible video endoscope under general anaesthesia. The dogs were fasted for 36 to 48 hours and received enemas before the procedure (3). Local Ethics Committee approved the study.

On endoscopic visualisation numerous *T. vulpis* whipworms were found attached to the colon mucosa (Fig. 1).

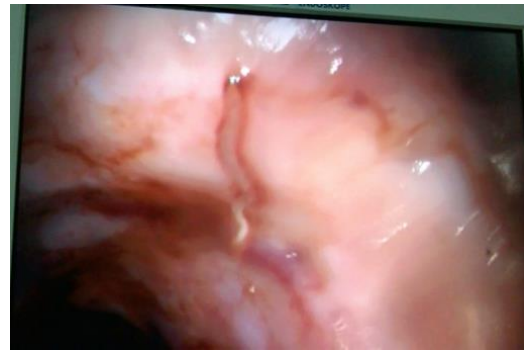

Fig. 1: *Trichuris vulpis* worms

Multiple bleeding ulcerated sites were observed throughout the colon (Fig. 2). The dogs were treated with oral febental, praziquantel and pyrantal combination tablets (Drontal Plus®).

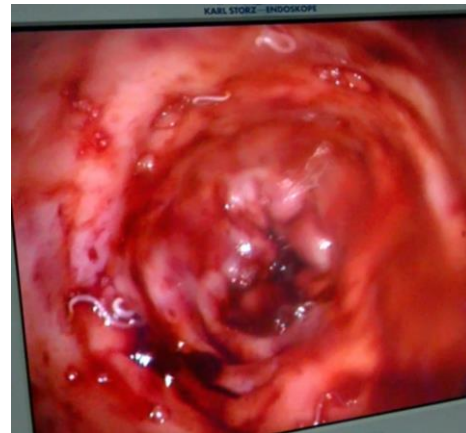


Fig. 2: *Trichuris vulpis* worms attached to mucosa and bleeding ulceration in colon

The dosage was repeated again after three weeks. Along with deworming treatment for

colitis was done with metronidazole, pantoprazole and prednisolone (1 mg/kg body weight). Clinical improvement was observed within a week. Bleeding reduced and dogs defecated normally. Treatment for colitis was continued for four weeks for healing of colon mucosa.

Discussion

T. vulpis (Whipworm), a parasite of the cecum and colon is a common cause of colitis like signs in dogs. In case of light infections, the worms are restricted to the cecum, but as the parasite number increases, worms spread more distally into the colon.

Whipworm infestation usually presents no clinical signs. The factors such as number and physical presence of worms, degree of inflammation produced by the worms, level of anemia or hypoproteinemia contribute to the development of clinical signs (4). In heavy infections episodes of diarrhoea with large amounts of mucus and blood on the faeces alternating with periods of voiding normal faeces are seen. Abdominal pain, vomiting, inappetence, weight loss and anaemia can also be observed (5). Definitive diagnosis of whipworm infection is done by identification of the characteristic brown coloured, bipolar operculated barrel shaped ova. Floatation methods are optimal for the concentration and detection of eggs in faeces (6). However, it was interesting to observe in the present case study that three dogs which were negative to faecal examination for any parasites were found to have *T. vulpis* infestation only after endoscopy. Faecal analysis is negative most of the times due to the long prepatent period and eggs may be shed intermittently (7). Further, whipworms produce eggs in low numbers. This may lead to a high risk of missed diagnosis (8). It is estimated that up to 50 percent dogs with whipworm infestation have ova negative or occult infections (8).

The diagnosis can be done by direct colonoscopic observation of adult worms in bowel lumen (9). A flexible endoscope allows the entire colon to be inspected for worms, hyperaemia, thickening, serrations, folds and ulcers. Since most lesions are in the descending colon and rectum a much cheaper rigid endoscope is generally adequate. In our study, the worms were found attached to entire wall and there were ulcerations due to the attachment. The male and female whipworms can be found with their anterior thin, whip-like stichosome esophageal portion of the body threaded within the surface epithelium of the cecum or colon wall. This tunneling of the thin anterior portion of the adult worm into the epithelium produces localized inflammation, mucosal hyperplasia, and in some cases focal granulomatous reactions (10).

In general, the canine whipworm is a ubiquitous parasite and has zoonotic potential (8). Hence proper treatment and management is necessary. A combination of oral praziquantel, febantel and pyrantel pamoate (@25 mg/kg febantel once) or fenbendazole (@50 mg/kg q24 h for three days) can be used for treating whipworm infestation (11,12). Treatment should be repeated after three weeks and again after three months as anthelmintic administration will remove the adult worms and larvae will still develop into adult parasites and re-establish infestation (13). Further, frequent disposal of faeces will help reduce the risk of reinfection.

Conclusion

Colonoscopy is generally a very safe and effective tool in the diagnosis of *T. vulpis* infection when fecal analysis result is negative.

Negative faecal results of diarrhoeic dog do not exclude infection and therefore other diagnostic modalities such as colonoscopy should be used when there is persistent gastrointestinal signs and no response to antibiotic therapy. Colonoscopy is a cheap and

easy method which can be employed in diagnosis of *T. induced colitis*.

Acknowledgements

The authors wish to thank the authorities of TANUVAS for the facilities provided.

Conflict of interest

The Authors declare that there is no conflict of interest.

References

1. Venco L, Valenti V, Genchi M Grandi G. A dog with pseudo-addison disease associated with *Trichuris vulpis* infection. *J Parasitol Res.* 2011, 682039.
2. Moore LE. The advantages and disadvantages of endoscopy. *Clin Tech Small Anim Pract.* 2003; 18(4): 250-253.
3. Willard MD. Colonoscopy, proctoscopy, and ileoscopy. *Vet Clin North Am Small Anim Pract.* 2001; 31: 657-669.
4. Carter GR. *A Concise Guide to Infectious and Parasitic Diseases of Dogs and Cats.* Ithaca, NY, International Veterinary Information Service. 2001. <https://www.ivis.org/>
5. Nemzek JA, Lester PA, Wolfe AM, Myers Jr DD. *Biology and diseases of dogs.* In: *Laboratory animal medicine.* Fox, J. (Ed) 3rd edition, Academic Press, USA. 2015; p:528
6. Dryden MW, Payne PA, Ridley R, Smith V. Comparison of common fecal flotation techniques for the recovery of parasite eggs and oocysts. *Vet Ther.* 2005; 6: 15–28.
7. Nolan T. *Diagnosis of Veterinary Endoparasitic Disease.* Philadelphia, PA, University of Pennsylvania: Computer Aided Learning Project. 2003.
8. Traversa D. Are we paying too much attention to cardiopulmonary nematodes and neglecting old-fashioned worms like *Trichuris vulpis*? *Parasit Vectors.* 2011; 4:32
9. Birchard SJ, Sherding RG. Digestive system. In: Birchard SJ, Sherding RG, eds. *Saunders Manual of Small animal practice.* 3rd ed. St. Louis, MO: Saunders Elsevier; 2006, p: 715-716.
10. Kirkova Z, Dinev I. Morphological changes in the intestine of dogs experimentally infected with *Trichuris vulpis*. *Bulgarian J Vet Med.* 2005; 8: 239-243.
11. Coles TB, Lyn RC. Drugs for the treatment of helminth infections: anthelmintics. In: Boothe DM, ed. *Small Animal Clinical Pharmacology and Therapeutics.* 2nd ed. St. Louis, MO: Saunders Elsevier; 2012, p:451-468.
12. Plumb DC. Fenbendazole. In: Plumb DC, ed. *Plumb's Veterinary Drug Handbook.* 8th ed. Wiley-Blackwell, Ames, Iowa. 2015; p:243.
13. Keyte S. Differential diagnosis and management of Haematochezia in dogs and cats. *In Pract.* 2018; 40: 326-333.