



Tehran University of Medical  
Sciences Publication  
<http://tums.ac.ir>

## Iran J Parasitol

Open access Journal at  
<http://ijpa.tums.ac.ir>



Iranian Society of Parasitology  
<http://isp.tums.ac.ir>

### Original Article

## Clinicopathological Review of Human Coenurosis in Kwazulu-Natal, South Africa: A Retrospective Single Center Study

\*Gamalenkosi Bonginkosi Nhlonzi<sup>1,2</sup>, Absalom Mwazha<sup>1,2</sup>

1. Department of Anatomical Pathology, National Health Laboratory Service, Inkosi Albert Luthuli Central Hospital, KwaZulu-Natal, South Africa
2. School of Laboratory Medicine and Medical Sciences, University of KwaZulu-Natal, Durban, KwaZulu-Natal, South Africa

Received 10 Aug 2021  
Accepted 15 Oct 2021

**Keywords:**  
Coenurosis;  
Taeniasis;  
Histopathology;  
South Africa

**\*Correspondence  
Email:**  
[Nhlonzigb@gmail.com](mailto:Nhlonzigb@gmail.com)

### **Abstract**

**Background:** To describe the clinicopathological features of human coenurosis diagnosed at a single center in an academic Anatomical Pathology Laboratory, KwaZulu-Natal, South Africa.

**Methods:** This was a 10-year retrospective laboratory based study, from 2011-2020, which reappraised the clinical presentation, histomorphological tissue reaction patterns and outcomes in patients diagnosed with coenurosis.

**Results:** Five cases of coenurosis and 19 cases of cysticercosis were diagnosed during the study period. Following re-appraisal of the slides, 6 cases of coenurosis were confirmed and included in the study cohort. The anatomical distribution of disease was as follows: brain (1), liver (1), eye (1) and soft tissue (3). There were 3 males and 3 females and the patients' age ranged from 2 to 46 (mean 22.2) yr. Three patients were HIV positive whilst the clinical history of the infection was not available for the other 3 patients. All patients presented with mass effect related symptoms, ranging from headache to a painful soft tissue swelling. Two cases displayed synovial metaplasia in addition to characteristic chronic subacute inflammation and fibrosis. One case had supportive inflammation. Two cases comprised of coenuri exclusively and therefore it was not possible to assess tissue reaction.

**Conclusion:** We describe the first cases of human coenurosis in HIV positive patients and for the first time report synovial metaplasia as one of the reaction patterns of coenurosis. Whenever cysticercosis and hydatidosis are considered clinically, a negative serology should prompt clinicians to consider coenurosis in addition to the neoplastic diagnostic considerations.



## Introduction

Coenurosis is a major zoonotic parasitic infection caused by metacestode larval stage of coenurus forming *Taenia* species (1). Cases in humans have been reported in sheep farming communities from Africa, North America, Europe and Asia (2-3). Human infections follow ingestion of water or food contaminated by faeces with ova or gravid proglottids (3). The causative parasites for coenurosis include *T. multiceps*, *T. serialis*, *T. brauni* and *T. glomeratus* (2).

The clinical presentation is organ dependent with central nervous system (brain), eyes and muscles being the most reported locations (3-4). The major mechanism of disease is secondary to mass effect, however toxic and hypersensitivity reactions contribute to the disease process. The viable organisms induce little tissue reaction pattern however necrotic coenuri induce inflammatory responses including suppurative and granulomatous types (3).

The microscopic anatomy of coenurosis and cysticercosis shows marked overlap in small biopsies with poor representation of scolices. The only distinguishing feature is multiple scolices in coenurosis (5).

Herein we describe the clinical presentation, tissue reaction patterns and outcome in six human cases of coenurosis diagnosed at a single center in KwaZulu-Natal, South Africa.

## Methods

This retrospective descriptive study involved the retrieval and re-evaluation of all biopsies diagnosed and coded, using the SNOMED word and code search system, as 'coenurosis' and 'cysticercosis' from 01 Jan 2011 to 31 Dec 2020.

The study was approved by the Biomedical Research Ethics Committee of the University

of KwaZulu-Natal (Study number: BCA535/16).

Departmental archival slides were retrieved or recut from archival blocks and independently reappraised by two pathologists (GN & AM). The routine and special stains were performed using accepted standard protocols. Immunoperoxidase stains were performed using an automated immunostainer (Ventana Benchmark Ultra, Tucson, AZ) according to the standard protocol. The following stains and immunoperoxidase stains were reviewed: Haematoxylin and eosin, Ziehl-Neelsen, von Kossa, CD163, CD68 and vimentin.

The following clinical information was extracted from the departmental and/or clinical records: patient's age, sex, HIV status, CD4 count, site of lesion, presenting complaint, treatment and the outcome. The microscopic features that were evaluated included the tissue reaction adjacent to the parasite and the morphology of the parasite to either confirm or rule-out coenurosis.

## Results

Five cases of coenurosis and 19 cases of cysticercosis were diagnosed during the study period. Archival material was available to review for all the cases. Following re-appraisal of the slides, 6 cases of coenurosis were confirmed and included in the study cohort. One case of coenurosis was initially misdiagnosed as cysticercosis. Eighteen cases of cysticercosis were confirmed and excluded from the study. The age range of patients was 2 to 46 (mean 22.2) yr (Table 1).

Three patients were HIV positive and on antiretroviral therapy, whilst the HIV status for the other 3 patients was unknown. Echinnococcal and neurocysticercosis serology was negative for two patients, whilst no data was

available for the other four. All the patients presented with symptoms related to mass lesion. One patient presented with sudden onset of neurological symptoms including sudden onset of left sided weakness and headache.

Magnetic resonance imaging (MRI) of the brain with contrast revealed a right high parie-

tal lobe multiloculated cystic lesion measuring 4.4cm x 4.7cm x 4.4cm. Ring enhancement of the lesion was noted. Mild scalloping of the inner table of the skull vault was present. No mural nodules were identified.

**Table 1:** Summary of the clinical history and pathologic findings in 6 patients in this study

<i>Case</i>	<i>Year</i>	<i>Age (Yr)</i>	<i>Sex</i>	<i>HIV status</i>	<i>CD4 (Cells/mm<sup>3</sup>)</i>	<i>Location</i>	<i>Presenting symptoms</i>	<i>Outcome</i>	<i>Tissue reaction</i>
1	2013	11	F	U	N/A	Left eye	Painful mass	L/FU	N/A
2	2015	29	F	U	N/A	Neck (IM)	Mass	L/FU	S/L/E/P
3	2015	10	M	+	246	Right lobe of liver	Liver dysfunction	Alive at 2 years	SI/L/P/N/E/H
4	2017	2	M	U	N/A	Abdominal wall (IM)	Mass	L/FU	S/L/P/E/H
5	2017	35	M	+	U	Chest wall (IM)	Mass	L/FU	F/L/P/E
6	2019	46	F	+	30	Right parietal lobe of cerebrum	6 months of headache & progressive left hemiparesis	Deceased	N/A

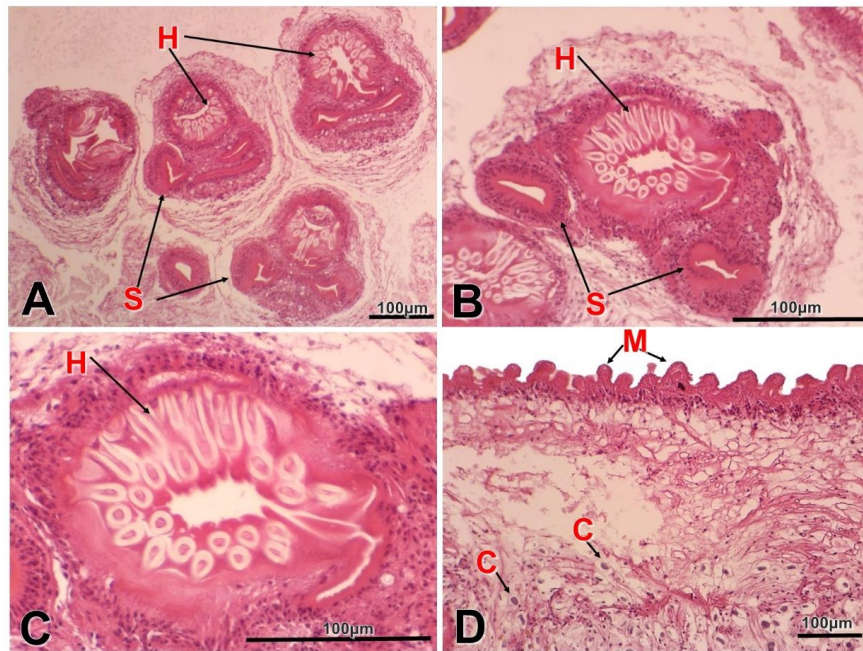
Key: F=female, M=male, +=positive, U=unknown, IM=intramuscular, L/FU=lost to follow up, S=synovial metaplasia, L=lymphocytes, E=eosinophils, P=plasma cells, SI=suppurative inflammation, N=neutrophils, H=histiocytes, F=fibrosis, N/A=not applicable

The microscopic sections of all the cases confirmed the described morphology of coenurus including the presence of coenurus with double row of hooklets, multiple scolices and an eosinophilic tegument with microvilli (Fig. 1 A-D). Two cases exclusively comprised parasite material (Fig. 1 A-D).

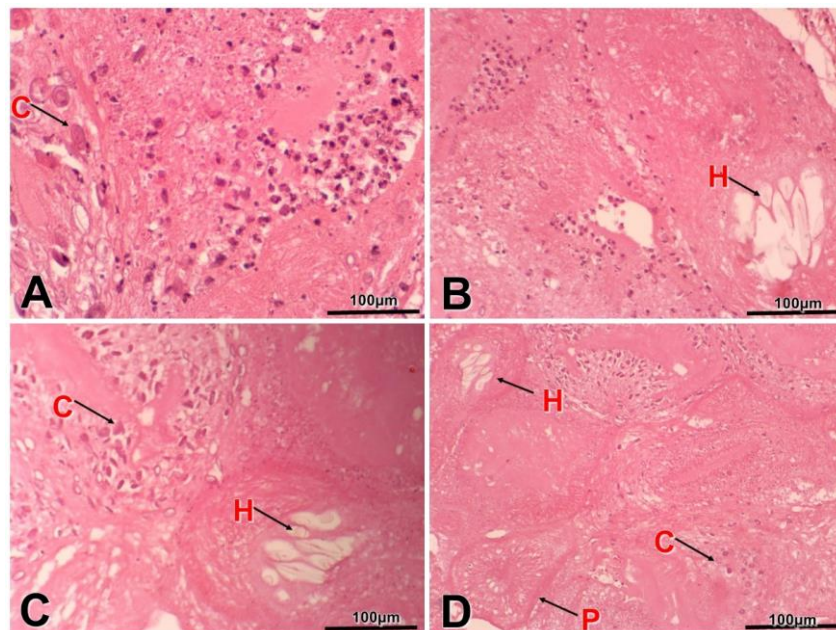
Four cases displayed variable inflammatory responses including suppurative inflammation, subacute and chronic inflammation comprising eosinophils, lymphocytes, plasma cells and histiocytes (Fig. 2).

Two cases with synovial metaplasia as evidenced by pseudocyst were lined by luminal

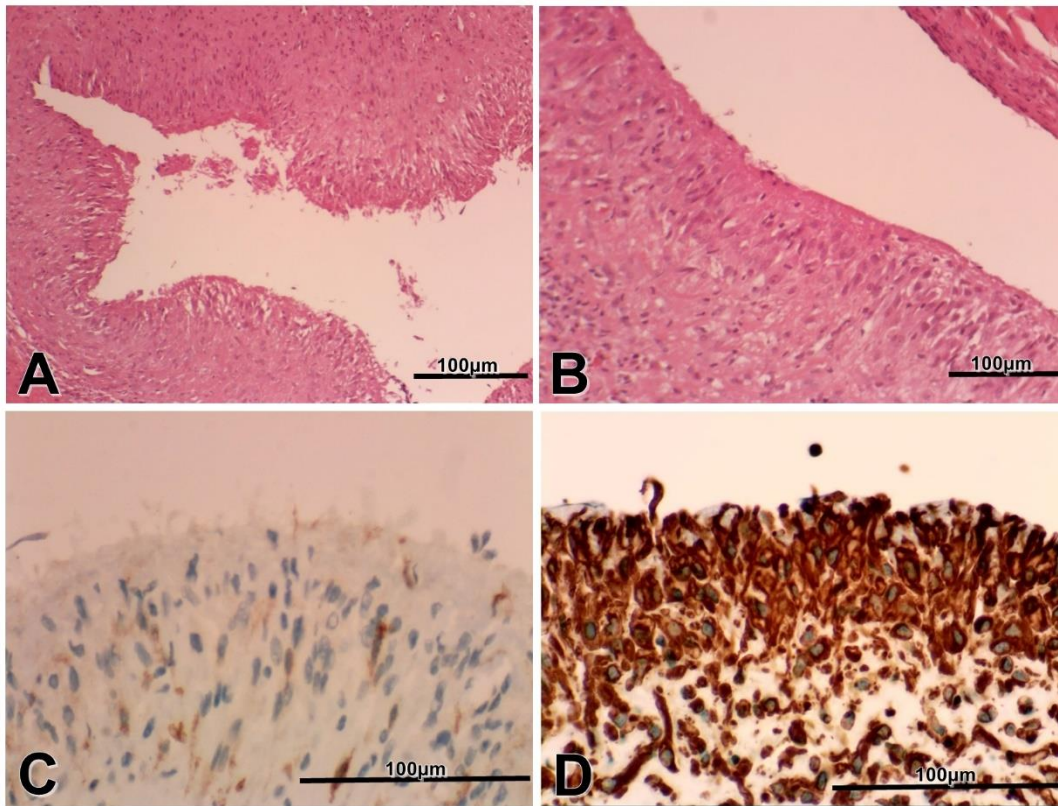
fibrin, multilayered spindle cells, oval cells and scattered admixed inflammatory cells. Negative CD163 and CD68 and strong positive vimentin expression profile confirmed the synovial metaplasia (Fig. 3). Fibrin accumulation, fibrosis and granulation tissue response were seen in one case. Granulomatous inflammation was not identified in any of the biopsies. Ziehl-Neelsen stain was negative in cases of synovial metaplasia and suppurative inflammation. Von Kossa stain confirmed calcification process in the calcareous bodies.



**Fig. 1:** The characteristics of protoscolex of coenurus cross section (A– D, H&E). (A) Sectional view of coenurus showing multiple scolices; arrows indicate hooks, suckers and calcareous bodies (x10); (B) Sectional view of head of scolex showing the principal anatomic details (see arrows) (x20); (C) High power view of a proto-scolex showing rostellar hooks (x40); (D) Tegument with microvilli, subtegumental cyton and myxoid stroma with scattered calcareous bodies (x20). Abbreviation: H: Hooks; M: Microvilli; C: Calcareous bodies; S: Suckers



**Fig. 2:** Suppurative inflammation and degenerate coenurus (A– D, H&E x20). (A) Suppurative inflammation, necrosis and calcareous bodies; (B) Suppurative inflammation, necrosis and residual hooks; (C-D) Degenerate procolex, hooks, calcareous bodies and necrosis. Abbreviation: H: Hooks; C: Calcareous bodies; P: Degenerate protoscolex



**Fig. 3:** Synovial metaplasia in coenurosis. (A-B, H&E; C-D, immunohistochemistry). (A&B) Synovial metaplastic capsule facing the coenurus, showing that the 75–100-µm thick pseudosynovial membrane lined by spindle-shaped cells (synovial cells) and a subintimal fibrovascular layer populated by numerous blood vessels; (C) Vimentin highlights the spindle lining the pseudocyst in synovial metaplasia (x40); (D): CD163 highlights isolated macrophages on the wall (x40)

The patient with liver coenurosis was treated with albendazole and was alive at 2 yr follow-up, with a persistent liver mass measuring 4.02 x 4 cm, a decrease from the initial size of 8.7 x 7.0 cm. The patient with cerebral coenurosis demised 11 days-post craniotomy for removal of the cyst. An autopsy was not requested by the attending physician. Follow-up information was not available for the other 4 patients.

## Discussion

Human coenurosis was first described by Brumpt in 1913 and the first South African case was reported in 1940 by Cluver following

an autopsy (4-6). Whilst coenurosis occurs worldwide, the majority of cases have been reported in sheep farming communities from regions such as Africa, the Mediterranean, and the Middle East (5-9). Despite the fact that KwaZulu-Natal is not a sheep-rearing community, we described six coenurosis instances from 3 HIV-positive patients and 3 patients with unknown HIV status.

Coenurosis has been described in various human body parts including brain, soft tissue, eyes and visceral organs (4, 9, 10). The current study re-affirms that coenurosis can involve different areas of the body (Table 1). In a North American human coenurosis study, 6 cases from 6 patients were described, from which, 50% (3) cases occurred in the nervous

system and the other 3 were found in the skeletal muscles (4). This is in contrast to the current study in which 1 case occurred in the CNS, 1 in a visceral organ (liver), 3 in the soft tissue/skeletal muscle and 1 case involved the eye. In the current and the North American study by Ing et al (4), the *Taenia* species were not subtyped. The majority of cases have previously been described in adults (11), and in this study 50% (3/6) of the cases occurred in children. Fain described 8 cases of cutaneous coenurosis, among which, 7 cases occurred in children (12). Thus, the age predilection varies in different studies and a full epidemiological study of human coenurosis may be necessary to clarify this question.

In the present study, three patients were HIV positive while the HIV status was not available for the other three patients. PubMed and Google scholar search for 'HIV/AIDS and coenurosis' yielded isolated case reports on cysticercosis and HIV/AIDS (13). To the authors' experience, the correlation between HIV/AIDS and coenurosis remains undescribed and the three cases are the first to be described in HIV positive patients. Two patients in the study cohort were on anti-retroviral therapy (ART), and both presented with large masses that measured over 4 cm in greatest dimension. One of the HIV positive patients had cerebral coenurosis and the biopsy material did not contain any residual tissue for evaluation of tissue reaction patterns. The exact mechanism of death was not ascertained, as an autopsy was not undertaken. The other HIV positive patient had liver coenurosis and the biopsy showed suppurative inflammation, fibrin and granulation tissue response. Granulomatous reaction was not present. The lesion showed to be shrinking in size on follow-up ultrasonography imaging over a two-yr period. The lack of granulomatous inflammation may be due to the low CD4 count and impaired cell-mediated immune response (13). The progressive decrease in the size of the liver mass in this case would indicate that, the medical

treatment was effective in controlling the disease.

The microscopic features of coenuri are well described. The coenurus comprises multiple scolices and tegument composed of amorphous eosinophilic outer membrane, muscle layer and loose stroma containing calcified bodies (3). Vaughan and Connor indicated that intact coenuri induce little tissue reaction while the degenerative coenuri induce suppurative and granulomatous inflammatory response (3). The liver case showed an admixture of viable and degenerated coenuri with associated suppurative inflammation as described; however, there was no granulomatous inflammatory response.

In two cases, the adjacent tissue displayed synovial metaplasia, granulation tissue, fibrosis, subacute and chronic inflammation. The histologic sections mimicked granulomatous inflammation hence CD163, CD68 and vimentin immunoperoxidase stainings were undertaken. The cells lining the pseudocyst were mesenchymal in nature and the granulomatous response was ruled-out in view of negative CD163 and CD68, and positive vimentin (Fig. 3). Synovial metaplasia has been described in association with trauma, surgery, breast implants, joint prosthesis, neoplastic and connective tissue diseases (14-16). This is the first description of synovial metaplasia occurring in the background of coenurosis. The pathogenesis of synovial metaplasia in coenurosis may be similar to that seen in breast implants and joint prosthesis. The coenuri may induce break in connective tissue with potential to induce synovium-like tissue as per the embryological process in the development of synovium (16).

Despite the fact that granulomatous inflammation is one of the typical reaction patterns in coenurosis in both human and animal studies, none of the cases in the current study cohort demonstrated this tissue response (3, 17). While three cases were HIV positive, the HIV status was unknown in the other three

patients (Table 1) and thus, the absence of granulomatous inflammation may have been due to intact coenuri or impaired T-cell mediated responses. It is uncertain to the authors that how HIV/AIDS in the 3 cases might have influenced tissue reaction pattern. However, Delobel et al described giant cysticercosis in a patient with HIV/AIDS, and postulated that HIV/AIDS may cause uncontrolled parasitic growth due to an impaired cell-mediated immune response (13). Our patients with available CD4 results, had counts consistent with AIDS and therefore impaired cell-mediated immune response would be expected. All patients with represented resident tissue displayed infiltrate of eosinophils as expected in parasitic infestations.

The clinical diagnosis of coenurosis remains an enigma as evidenced in this study. Whilst parasitic infections such as neurocysticercosis and hydatidosis were considered, negative serology results ruled-out these possibilities and neoplastic diseases were entertained. On light microscopy, the diagnosis is straightforward; however, the similarities with more common and well-recognized neurocysticercosis may lead to an incorrect diagnosis as demonstrated in one of our cases. It is therefore essential that pathologists familiarize themselves with light microscopic diagnostic features of coenurosis.

## Conclusion

The first cases of human coenurosis in HIV positive patients have been described. For the first time, synovial metaplasia has been described as one of the reaction patterns to coenurosis in addition to established reaction patterns. Whenever cysticercosis and hydatidosis are considered clinically, negative serology should prompt clinicians to consider coenurosis in addition to the neoplastic diagnostic considerations. May this study stimulate more research on this rare parasitic infection and

increase the awareness of salient diagnostic features.

## Acknowledgements

We thank the National Health Laboratory Service for the support, our mentors, Dinesh Sookhdeo and Sadiki Kabala for patient data collection and Manto Mzizi-Mkize for slides and blocks retrieval.

## Conflict of interest

The authors declare that there is no conflict of interest.

## References

1. Rahsan Y, Nihat Y, Bestami Y, Adnan A, Nuran A. Histopathological, Immunohistochemical, and Parasitological Studies on Pathogenesis of *Coenurus cerebralis* in Sheep. J Vet Res. 2018;62(1):35-41. Published 2018 Mar 30. doi:10.1515/jvetres-2018-0005.
2. Yamazawa E, Ohno M, Satomi K, et al. First case of human neurocoenurosis caused by *Taenia serialis*: A case report. Int J Infect Dis. 2020;92:171-174. doi:10.1016/j.ijid.2020.01.004.
3. Vaughan PJ, Connor DH. Coenurosis. In Pathology of infectious diseases. Vol. 1. Stamford, Connecticut: Appleton and Lange; 1997; 1361-1364.
4. Ing MB, Schantz PM, Turner JA. Human coenurosis in North America: case reports and review. Clin Infect Dis. 1998; 27(3):519-523. doi:10.1086/514716.
5. Ali SM, Reddy PS, Venugopal S, Chhabra M, Mahadevan A. Cerebral Coenurosis Masquerading as Malignancy: A Rare Case Report from India. J Neurosci Rural Pract. 2019;10(2):367-370. doi:10.4103/jnrp.jnrp\_296\_18.
6. Watson KC, Laurie W. Cerebral coenurosis in man. The Lancet. 1955; Dec24:1321-1322.
7. El-On J, Shelef I, Cagnano E, Benifla M. *Taenia multiceps*: a rare human cestode infection in Israel. Vet Ital. 2008; 44(4):621-631.
8. Michal A, Regli F, Campiche R, et al. Cerebral coenurosis. Report of a case with arteritis. J

- Neurol. 1977; 216(4):265-272. doi:10.1007/BF00314050.
9. Wilson VC, Wayte DM, Addae RO. Human coenurosis--the first reported case from Ghana. *Trans R Soc Trop Med Hyg.* 1972; 66(4):611-623.
  10. Malomo A, Ogunniyi J, Ogunniyi A, Akang EE, Shokunbi MT. Coenurosis of the central nervous system in a Nigerian. *Trop Geogr Med.* 1990; 42(3):280-282.
  11. Lescano AG, Zunt J. Other cestodes: sparganosis, coenurosis and *Taenia crassiceps* cysticercosis. *Handb Clin Neurol.* 2013; 114:335-345. doi:10.1016/B978-0-444-53490-3.00027-3.
  12. FAIN A. Coenurus of *Taenia brauni* Setti parasitic in man and animals from the Belgian Congo and Ruanda-Urundi. *Nature.* 1956; 178(4546):1353. doi:10.1038/1781353a0.
  13. Delobel P, Signate A, El Guedj M, et al. Unusual form of neurocysticercosis associated with HIV infection. *Eur J Neurol.* 2004; 11(1):55-58. doi:10.1046/j.1351-5101.2003.00696.x.
  14. Kermani H, Dehghani N, Dehghani S, et al. Cutaneous Metaplastic Synovial Cyst: A Case Report and Literature Review. *Iran Red Crescent Med J.* 2015; 17(12):e22467. Published 2015 Dec 28. doi:10.5812/ircmj.22467.
  15. Kim BC, Choi WJ, Park EJ, et al. Cutaneous metaplastic synovial cyst of the first metatarsal head area. *Ann Dermatol.* 2011; 23(Suppl 2):S165-S168. doi:10.5021/ad.2011.23.S2.S165.
  16. Ramdial PK, Singh Y, Singh B. Metaplastic synovial cyst in male breast. *Ann Diagn Pathol.* 2005; 9(4):219-222.
  17. Amrabadi O, Oryan A, Moazeni M, Shari-Fiyazdi H, Akbari M. Histopathological and Molecular Evaluation of the Experimentally Infected Goats by the Larval Forms of *Taenia multiceps*. *Iran J Parasitol.* 2019; 14(1):95-105.