



Tehran University of Medical
Sciences Publication
<http://tums.ac.ir>

Iran J Parasitol

Open access Journal at
<http://ijpa.tums.ac.ir>



Iranian Society of Parasitology
<http://isp.tums.ac.ir>

Case Report

Isolated Renal Hydatid Cyst in a 6-Year-Old Boy: A Case Report

*Mehmet Demir, İsmail Yağmur

Department of Urology, Faculty of Medicine, Harran University, Şanlıurfa, Turkey

Received 10 Apr 2021
Accepted 19 Jun 2021

Keywords:
Hydatid cyst;
Kidney;
Children;
Echinococcus granulosus;
Turkey

***Correspondence**
Email:
drdemir02@gmail.com

Abstract

Hydatid cyst (HC) is a parasitic infection transmitted by oral ingestion of *Echinococcus granulosus* eggs. Isolated kidney involvement is extremely rare. It is even less common in children. We present a case of isolated renal HC in a 6-year-old boy from Şanlıurfa, southeast Turkey who complained of abdominal pain and distension. Cystectomy was performed with a flank incision using the extraperitoneal approach. No recurrence was detected in the postoperative 6-month follow-up. There are not enough data about the efficacy of medical treatment in renal HC. Therefore, medical treatment should be considered pre- and post-operatively to prevent dissemination, rather than being used as a primary treatment. Kidney-sparing surgery should be the first choice in patients with isolated renal HC. However, nephrectomy is recommended for nonfunctioning kidneys, large cysts thought to be connected with the collecting system, and cysts with suspicious tumor. In societies where HC disease is endemic, renal HC should be considered in children with cysts located in kidney, even if the indirect hemagglutination test is negative.

Introduction

Hydatid cyst (HC) is a parasitic infection transmitted by oral ingestion of *Echinococcus granulosus* eggs. It is endemic in parts of the Mediterranean Basin, South America, the Middle East, Australia, and South Africa (1). While 70% of the patients have liver involvement, 25% have lung involvement and 2%–4% have kidney involvement.

Isolated kidney involvement (1.9%) is extremely rare (2) and even less common in children (2,3). Kidney involvement usually occurs in the form of a single cyst in the renal cortex. Clinical symptoms vary depending on the cyst's size, location, and extension. Since the growth of the cyst takes years, patients can be asymptomatic for a long time. Sometimes they may present with flank pain, hematuria,



Copyright © 2021 Demir et al. Published by Tehran University of Medical Sciences.
This work is licensed under a Creative Commons Attribution-NonCommercial 4.0 International license.
(<https://creativecommons.org/licenses/by-nc/4.0/>). Non-commercial uses of the work are permitted, provided the original work is properly cited.

hydatiduria, and abdominal mass. (4,5). Furthermore, they can clinically and radiologically mimic cystic kidney tumors (6).

We present a case of isolated renal HC in a 6-year-old boy who was presented with an abdominal mass.

Case Report

A 6 year-old boy presented to a health care center with abdominal pain and distension. Physical examination revealed a mass in the right quadrant. Abdominal ultrasonography (US) detected a 116×95×100-mm cystic lesion with a thick wall in the lower pole of the right kidney; the patient was then referred to our clinic. Physical examination revealed abdominal asymmetry and a palpable mass in the right quadrant (Fig. 1).

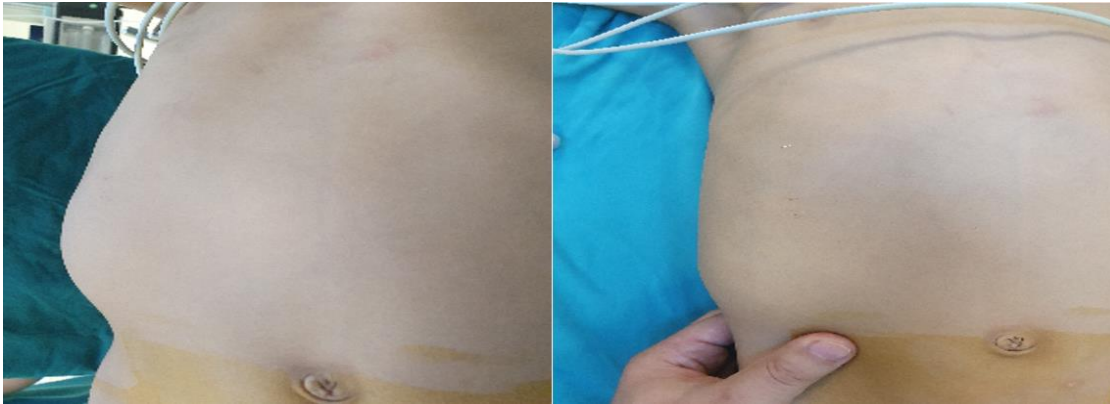


Fig. 1: Asymmetry in the abdomen and a palpable mass in the right lower quadrant

Other body parts were normal on physical examination; patient had a normal temperature of 36.8°C. Laboratory test results, including liver and kidney function tests, complete blood count, complete urinalysis, and urine microscopy, were normal. Contrast-enhanced abdominal tomography (CT) was performed

for differential diagnosis. CT revealed a 107×102×94-mm, hypodense cyst with suspected germinal membrane appearance in the right kidney inferoposterior area. Grade 3 hydronephrosis was observed in the right kidney (Fig. 2).

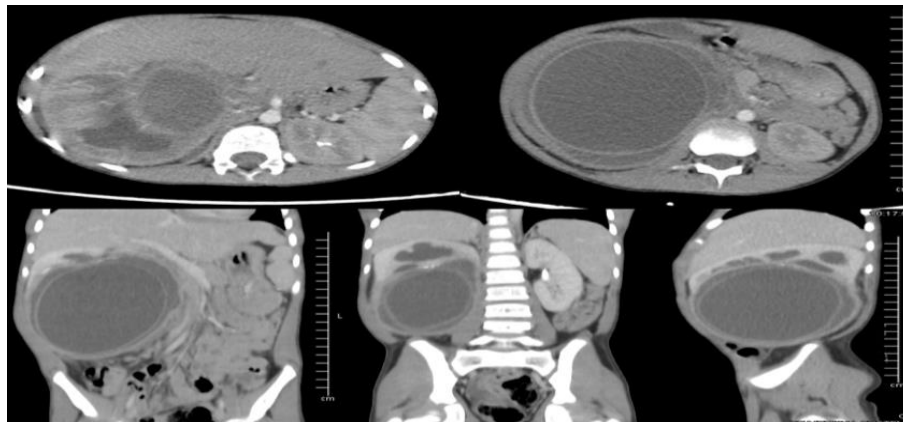


Fig. 2: Abdominal tomographic image; cyst with germinal membrane causing dilatation in the right kidney

Apart from that in the kidney, there were no other cysts in the thorax and abdomen. He underwent HC indirect hemagglutination test (IHA); the result ($\geq 1/160$) was negative. Based on radiological findings, we made a preliminary diagnosis of isolated renal HC and planned exploration and cystectomy. Albend-

azole 10 mg/kg/day, divided in two equal doses, was started preoperatively. After 3-week treatment and pre-exploration, retrograde pyelography was performed to check whether the cyst opened into the collecting system. Pyelography showed no connection of the cyst with the collecting system (Fig. 3).

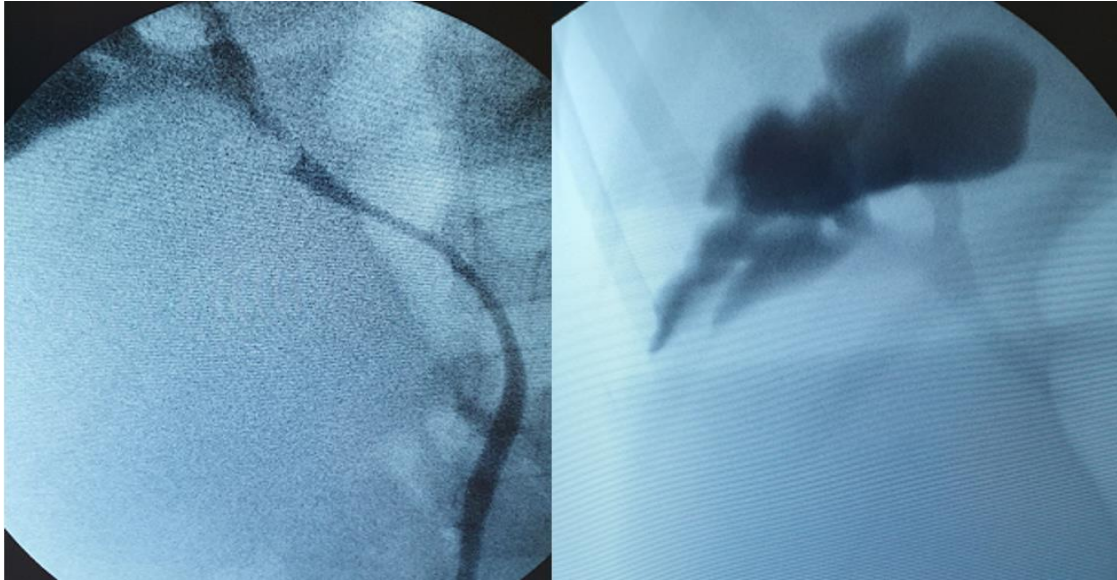


Fig. 3: Retrograde pyelography; the cyst does open into the collecting system

Afterward, exploration was performed with a flank incision using the extraperitoneal approach. To prevent intraoperative dissemination, povidone iodine gauze was placed on the surrounding tissues. After the cyst content

was aspirated, hypertonic sodium chloride was injected as a scolical agent into the cyst; 10 min later, the cyst was opened, daughter vesicles and germinal membrane were removed, and the cyst wall was excised (Fig. 4).

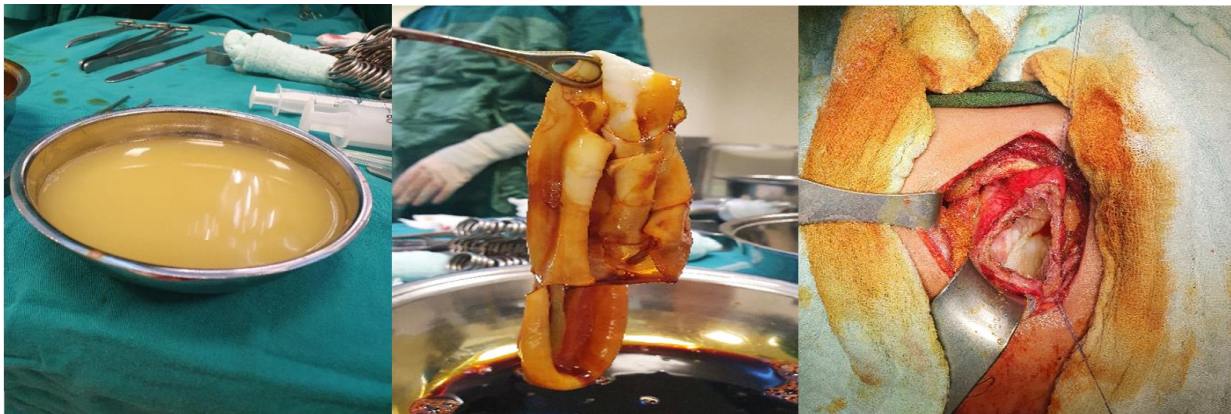


Fig. 4: Intraoperative image; aspiration of cyst contents and removal of germinal membrane

There were no intraoperative or postoperative complications. Histopathological examination revealed HC. Postoperative albendazole treatment was continued for 3 months. No recurrence was detected in the postoperative 6-month follow-up.

Discussion

Isolated renal HC is an extremely rare condition; 44% of patients with kidney involvement have other concurrent diseases (5). Renal HC can cause serious complications such as vascular compression, cyst infection, shock, sepsis, and death (7). Kidney involvement is unilateral in 85% and bilateral in 15% of patients. Since the cyst grows in the kidney over the years, the average age at diagnosis is 30 years (2). However, it can also be seen rarely in young age, as in our case.

Renal HC is a difficult disease to diagnose. The most common complaint is flank pain due to cyst compression. Abdominal mass can be palpated in the presence of enlarged cysts (2,8). Although hydatiduria is a pathognomic finding of HC, it is extremely rare. The cyst opens into the collecting system when the scolex passes into the urine. In only 10%–20% of the patients, the cyst opens into the collecting system. It is usually accompanied by renal colic (5,7,8).

There are many options such as medical treatment, percutaneous intervention, open surgery, and minimally invasive surgery for the treatment of renal HC. There are not enough data on the efficacy of medical therapy in renal HC (9). Therefore, medical treatment should be considered pre- and post-operatively to prevent dissemination, rather than as a primary treatment (8). PAIR (puncture-aspiration-injection-reaspiration) technique, which is a percutaneous intervention, can be successfully used in 70% of patients. However, this treatment does not eliminate cysts, and it can be safe only in high-risk pa-

tients with symptomatic HC (2). In surgical treatments, the aim is to remove the cyst without contaminating the patient. HC may lead to anaphylactic shock and death due to allergic reactions. Therefore, caution should be exercised. Before cystectomy, carefully evacuating the cyst contents and washing with a scolicidal (hypertonic sodium chloride, 0.5% silver nitrate, 2% formalin, 1% iodine) solution reduces the risk of allergic reaction and inoculation (5). Kidney-sparing surgery should be the first choice in patients with isolated renal HC. However, nephrectomy is a better option for nonfunctioning kidneys, large cysts thought to be connected with the collecting system, and cysts with suspicious tumor (2,10).

Although our patient had quite a large cyst, we found that the middle pole and upper pole parenchyma of the kidney was preserved, and the cyst did not open into the collecting system. Therefore, we performed cystectomy with a kidney-sparing approach.

Conclusion

Although HC most often affects the liver and lung, it may also involve other organs, particularly the kidney. Isolated kidney involvement is extremely rare. In societies where HC disease is endemic, such as Turkey, HC should be considered in children with cysts located in the kidney even if the IHA test is negative. Kidney-sparing surgery is the primary treatment for isolated renal HC.

Acknowledgements

The authors would like to thank sincerely Dr. Mehmet Emin Güldür for his cooperation especially on Parasitologic assessments. No financial support was received for the study.

Conflicts of interest

The authors have no competing interests.

References

1. Ravanbakhsh N, Rabiee N, Ahmadi J. Primary solitary hydatid cyst of brain in a 12-year-old boy: A Case Report. *Iran J Parasitol.* 2019;14(4):668-673.
2. Cankorkmaz L, Korğalı E, Atalar MH, et al. Case Report: isolated renal hydatid cyst in a boy. *Türkiye Parazitol Derg.* 2019; 43(2):89-91.
3. Tryfonas GJ, Avtzoğlu PP, Chaidos C, et al. Renal hydatid disease: diagnosis and treatment. *J Pediatr Surg.* 1993; 28(2):228-31.
4. Moscatelli G, Moroni S, Freilij H, et al. A five-year-old child with renal hydatidosis. *Am J Trop Med Hyg.* 2013; 89:554-556.
5. Efesoy O, Tek M, Erdem E, et al. İzole böbrek hidatik kistlerinin kistektomi ve omentoplasti ile tedavisi. *Turkish Journal of Urology.* 2010;36(2):176-181.
6. Singh V, Devana SK, Gorski U, et al. Isolated renal hydatid cyst masquerading as cystic renal tumor. *Urology.* 2019; 133: e11–e12.
7. Soares AT, Couto C, Cabral MJ, et al. Renal hydatid cyst: medical treatment. *J Bras Nefrol.* 2016;38(1):123-6.
8. Raxiati M, Mutalifu A, Azhati B, et al. Diagnosis and surgical treatment of renal hydatid disease: a retrospective analysis of 30 cases. *PLoS One.* 2014; 9(5): e96602.
9. Aggarwal S, Bansal A. Laparoscopic management of renal hydatid cyst. *JSLS.* 2014; 18(2):361–366.
10. Razzaghi MR, Mazloomfard MM, Bahrami-Motlagh H, et al. Isolated renal hydatid cyst: diagnosis and management. *Urol J.* 2012; 9(4):718-20.