



Tehran University of Medical  
Sciences Publication  
<http://tums.ac.ir>

## Iran J Parasitol

Open access Journal at  
<http://ijpa.tums.ac.ir>



Iranian Society of Parasitology  
<http://isp.tums.ac.ir>

### Case Report

## Pulmonary Cryptosporidiosis in HIV Infected Patients at Imam Khomeini Complex Hospital in Tehran, Iran: A Case Series

Saghi Rashidifar <sup>1</sup>, \*Mohammad Javad Gharavi <sup>2</sup>, Naser Harzandi <sup>1</sup>, Zohreh Momeni <sup>1</sup>, Malihe Hasan Nezhad <sup>3</sup>

1. Department of Microbiology, Karaj Branch, Islamic Azad University, Karaj, Iran

2. Department of Parasitology, School of Allied Medicine, Iran University of Medical Sciences, Tehran, Iran

3. Department of Infectious Diseases and Tropical Medicine, Imam Khomeini Hospital Complex, Tehran University of Medical Sciences, Tehran, Iran

Received 15 Nov 2024  
Accepted 10 Jan 2025

#### Keywords:

HIV;  
*Cryptosporidium*;  
Pulmonary cryptosporidiosis;  
Opportunistic infection

\*Correspondence Email:  
[mjgharavi@gmail.com](mailto:mjgharavi@gmail.com)

#### Abstract

*Cryptosporidium* species are a significant cause of persistent untreatable diarrhea in HIV-positive patients, especially in developing countries; however, extra-intestinal instances are rarely documented. Herein, we present three cases of pulmonary cryptosporidiosis in HIV patients at Imam Khomeini Hospital, Tehran, Iran. Despite the combination treatment with antiretroviral therapy, azithromycin, and paromomycin, the death of all 3 patients occurred due to severe complications. These cases highlight the importance of early diagnosis and management of respiratory cryptosporidiosis in HIV patients with low CD4 counts.

### Introduction

*Cryptosporidium* species are important intestinal protozoa, primarily responsible for intracellular infections in the intestinal epithelium, leading to persistent diarrhea in immunocompromised individuals

like HIV patients (1). Although instances of extra-intestinal *Cryptosporidium* infections are rare, they can spread to sites like the gallbladder, biliary tract, pancreas, and lungs (2, 3).

Transmission is typically fecal-oral, through contaminated food, water, or oocyst inhalation (4). Cases of respiratory cryptosporidiosis



Copyright © 2025 Rashidifar et al. Published by Tehran University of Medical Sciences.

This work is licensed under a Creative Commons Attribution-NonCommercial 4.0 International license.

(<https://creativecommons.org/licenses/by-nc/4.0/>). Non-commercial uses of the work are permitted, provided the original work is properly cited

have been reported, especially in HIV-infected patients (5). Herein, we present a case series of pulmonary cryptosporidiosis in patients diagnosed with HIV.

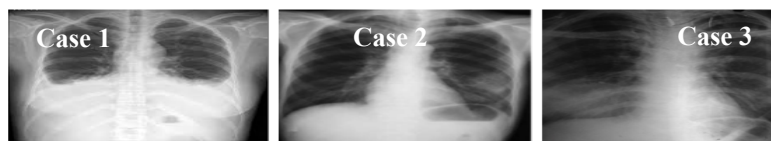**Case report**

**Case 1:** A 28-year-old woman, recently diagnosed with HIV, was hospitalized four months after starting antiretroviral therapy. She presented with acute diarrhea, chronic dyspnea, night sweats, intermittent fever, and a persistent cough. Examination revealed she was febrile, dehydrated, undernourished, and pallid. Chest X-ray showed mild fluid accumulation in both lungs and irregular opacities in the upper right lung (Fig. 1). Microscopic examination of sputum showed *Cryptosporidium* oocysts, confirmed as *C. parvum* by nested-PCR-RFLP (primers listed in Table 1). She was investigated thoroughly (Table 2) then, the diagnosis of respiratory cryptosporidiosis was established. Despite treatment, non-adherence to care led to fatal outcomes. Details of the medications used are listed in Table 3.

**Case 2:** A 34-year-old HIV-positive man was admitted for persistent watery diarrhea, dry cough, weight loss, shortness of breath,

and mild fever, ongoing for one month. He was febrile but conscious, cooperative, and oriented. A chest X-ray showed alveolar infiltrates in the left lower lobe (Fig. 1). *C. hominis* oocysts were detected in the sputum, confirmed by nested-PCR-RFLP (primers listed in Table 1). After thorough investigations (Table 2), respiratory cryptosporidiosis was diagnosed. Despite receiving treatment and supportive care, the patient died from an electrolyte disorder seven days after admission (Table 3).

**Case 3:** A 25-year-old HIV-positive man presented with a wet cough, constant fever with chills, dyspnea, watery diarrhea, nausea, and weight loss. Physical examination was unremarkable, and Chest X-ray revealed consolidation in the right lower lobe (Fig. 1). Microscopic examination revealed the presence *C. parvum* using nested-PCR-RFLP (primers listed in Table 1). Respiratory cryptosporidiosis was diagnosed after thorough investigations (Table 2). Also, a diagnosis of concurrent infection with disseminated MAC infection was established based on laboratory and clinical findings. Despite treatment, his condition rapidly deteriorated, leading to death (Table 3).



**Fig. 1:** (Case 1). Chest radiograph revealed mild fluid accumulation in both lungs and irregular opacities in the upper right lung, (Case 2). X-ray chest revealed an alveolar infiltrate in the left lower lobe, (Case 3). Chest X-ray revealed consolidation in the right lower lobe

**Table 1:** Primers used in this study

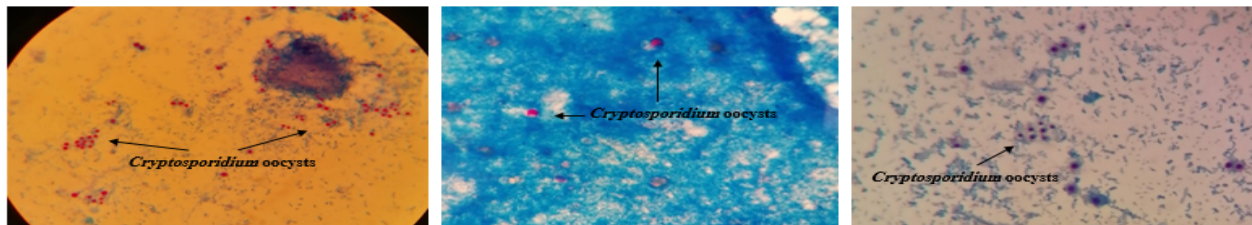
Primer Name	Amplicon size	Oligo sequences 5'→3'	Reference
Primer sets used for the primary PCR	860	TTCTAGAGCTAATACATGCG CCCTAATCCTTCGAAACAGGA	(6)
Primer sets used for the secondary PCR	860	TTCTAGAGCTAATACATGCG CCCATTTTCCTTCGAAACAGGA	(6)

**Table 2:** Laboratory findings and complications of the patients

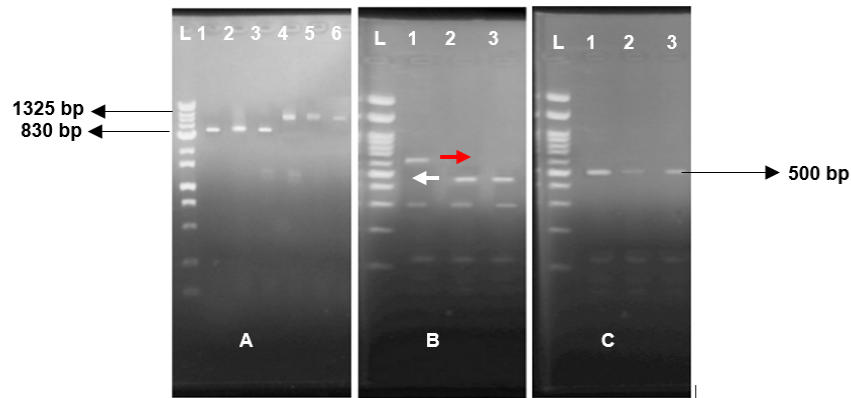
Indices	Patient 1	Patient 2	Patient 3
CD4 count (cells/mm <sup>3</sup> )	47	26	14
Total leukocyte count	4300	6200	1500
Hemoglobin (g/dl)	6.9	7.5	4.5
ESR (mm 1st hour)	100	85	110
SGPT (IU/L)	15	220	210
Alkaline phosphatase (IU/L)	175	130	2000
Viral load (copies/ml)	34500	559000	678000
Complications	Death	Death	Death

**Table 3:** Therapeutic regimens in each case

Case	Antiretroviral Drugs	Antibiotics
Case 1	Tenofovir, Emtricitabine, Dolutegravir	Azithromycin, Paromomycin
Case 2	Emtricitabine, Dolutegravir, Lamivudine	Azithromycin, Paromomycin
Case 3	Emtricitabine, Tenofovir, Efavirenz	Azithromycin, Paromomycin, Ethambutol



**Fig. 2:** Oocysts of *Cryptosporidium* measure 4–6  $\mu\text{m}$  long, have an irregular round or oval shape stained by Ziehl-Neelsen, modified blue trichrome and acid-fast trichrome methods, magnification 1000x



**Fig. 3:** Gel electrophoresis of nested PCR-RFLP based on the small subunit (SSU) rRNA gene of *Cryptosporidium*. The species of *Cryptosporidium* was determined by digestion with endonuclease, *SspI* (B) or *VspI* (C), of nested PCR products (A). Most of the isolates had both *C. hominis* and *C. parvum* patterns (B, C). The white arrowhead (ca. 448 bp) is *C. parvum*-specific and the red arrowhead (ca. 635 bp) indicates *C. hominis*-specific bands obtained by *SspI* (B) digestion

### Ethics approval

Ethical approval for the investigation was granted by the Ethical Committee of the Islamic Azad University of Karaj, Iran (ethical code: IR.IAU.K.REC.1402.123). Written informed consent was obtained from the patient.

### Discussion

Cryptosporidiosis is a leading cause of diarrhea in AIDS patients and can be life threatening in immunocompromised individuals (7, 8). While intestinal infections are common, respiratory cryptosporidiosis is rare, especially in immunocompetent individuals (9). Pulmonary cryptosporidiosis often presents with symptoms like persistent coughs, fever, and dyspnea with chest radiographs showing opacities (4). Diarrhea is a commonly associated symptom in respiratory cases, and a strong correlation exists between cryptosporidiosis and low CD4+ counts, particularly below 200 cells/mm<sup>3</sup> (2, 10).

In the present study, all patients had simultaneous intestinal and pulmonary cryptosporidiosis, with CD4+ counts below 50 cells/mm<sup>3</sup>, consistent with findings from India and Thailand, where opportunistic infections rise as CD4+ counts decline below 200 cells/mm<sup>3</sup> (11, 12). The pathogenesis of respiratory cryptosporidiosis remains uncertain, though possible routes include inhalation of oocysts or hematogenous spread (5). Regardless of the infection route, disseminated cryptosporidiosis causes severe, treatment-resistant, and fatal outcome (8).

This study found no discernible difference in detection and identification rates among staining techniques (Ziehl-Neelsen, modified acid-fast, modified trichrome) (Fig. 2). A recent study emphasizes the increased sensitivity of molecular techniques, which effectively complement traditional staining methods (13). Therefore, in the present study, respiratory cryptosporidiosis was diagnosed by nested

PCR in evaluated patients (primers listed in Table 1). RFLP using *Ssp1*, *Vsp1* and sequence analysis of the *18S rRNA* subunit led to the identification of *C. hominis* (n=1) and *C. parvum* (n=2) (Fig. 3).

Currently, cryptosporidiosis lacks a definitive treatment, particularly in immunocompromised patients like those with HIV (14). HIV patients with cryptosporidiosis require supportive care, including fluid and electrolyte management, along with antiretroviral therapy (7). Combination antiretroviral therapy should include a boosted protease inhibitor for its potential anticryptosporidial activity, enhancing the effects of paromomycin and azithromycin (3). Nitazoxanide has been reported as an effective alternative but is unavailable in our country (14, 15). In reported cases, combined therapy with paromomycin and azithromycin failed due to low CD4 counts and treatment nonadherence, leading to fatal outcomes.

### Conclusion

Pulmonary cryptosporidiosis is a rare but often deadly complication in HIV-positive patients with low CD4 counts. Early detection and proactive treatment are critical for better outcomes. Due to the high mortality rate and limited treatment options, pulmonary cryptosporidiosis should be considered in HIV patients with respiratory symptoms, especially in the presence of diarrhea and severe immunosuppression.

### Acknowledgements

Our thanks go to all the study participants, Dr. Saeed Hosseini, Mr. Esmail Sharifi, Dr. Parviz Shayan, Ms. Fereshte Shahmari, and the staff at Ferdis Central Laboratory and Imam Khomeini Hospital's Infectious Disease Department.

## Data availability

The sequences were submitted to GenBank under accession numbers PP716858.1 (*C. hominis*) and PP716761.1 (*C. parvum*).

## Conflict of Interest

The authors declare that there is no conflict of interests.

## References

1. O'connor RM, Shaffie R, Kang G, Ward HD. Cryptosporidiosis in patients with HIV/AIDS. *AIDS*. 2011; 25(5):549-60.
2. Hunter PR, Nichols G. Epidemiology and clinical features of *Cryptosporidium* infection in immunocompromised patients. *Clin Microbiol Rev*. 2002; 15(1):145-54.
3. Meamar AR, Rezaian M, Rezaie S, Mohraz M, Kia EB, Houpt ER, Solaymani-Mohammadi S. *Cryptosporidium parvum* bovine genotype oocysts in the respiratory samples of an AIDS patient: efficacy of treatment with a combination of azithromycin and paromomycin. *Parasitol Res*. 2006; 98(6):593-5.
4. Sponseller JK, Griffiths JK, Tzipori S. The evolution of respiratory Cryptosporidiosis: evidence for transmission by inhalation. *Clin Microbiol Rev*. 2014; 27(3):575-86.
5. Albuquerque YM, Silva MC, Lima AL, Magalhães V. Pulmonary cryptosporidiosis in AIDS patients, an underdiagnosed disease. *J Bras Pneumol*. 2012; 38:530-2.
6. Park JH, Guk SM, Han ET, Shin EH, Kim JL, Chai JY. Genotype analysis of *Cryptosporidium* spp. prevalent in a rural village in Hwasun-gun, Republic of Korea. *Korean J Parasitol*. 2006; 44(1):27-33.
7. Pantenburg B, Cabada MM, White AC Jr. Treatment of cryptosporidiosis. *Expert Rev Anti Infect Ther*. 2009; 7(4):385-91.
8. Sullivan T, Reese L, Huprikar S, Lee M. Pulmonary cryptosporidiosis and immune reconstitution inflammatory syndrome: a case report and review. *Int J STD AIDS*. 2013; 24(4):333-4.
9. Goodstein RS, Colombo CS, Illfelder MA, Skaggs RE. Bronchial and gastrointestinal cryptosporidiosis in AIDS. *J Am Osteopath Assoc*. 1989; 89(2):195-7.
10. Evering T, Weiss LM. The immunology of parasite infections in immunocompromised hosts. *Parasite Immunol*. 2006; 28(11):549-65.
11. Gupta S, Narang S, Nunavath V, Singh S. Chronic diarrhoea in HIV patients: prevalence of coccidian parasites. *Indian J Med Microbiol*. 2008; 26(2):172-5.
12. Wiwanitkit V. Intestinal parasitic infections in Thai HIV-infected patients with different immunity status. *BMC Gastroenterol*. 2001; 1: 3.
13. Adeyemo FE, Singh G, Reddy P, Stenström TA. Methods for the detection of *Cryptosporidium* and *Giardia*: From microscopy to nucleic acid-based tools in clinical and environmental regimes. *Acta Trop*. 2018; 184:15-28.
14. Kumar H, Singh VB, Meena BL, et al. Pulmonary cryptosporidiosis in an immunocompetent host treated successfully with nitazoxanide. *Lung India*. 2016; 33(1):69-71.
15. Gilbert IH, Vinayak S, Striepen B, et al. Safe and effective treatments are needed for cryptosporidiosis, a truly neglected tropical disease. *BMJ Glob Health*. 2023; 8(8): e012540.