



Tehran University of Medical  
Sciences Publication  
<http://tums.ac.ir>

## Iran J Parasitol

Open access Journal at  
<http://ijpa.tums.ac.ir>



Iranian Society of Parasitology  
<http://isp.tums.ac.ir>

### Original Article

# Effectiveness of Miltefosine Nanoemulsion Concerning the Treatment of Acute and Chronic Toxoplasmosis: In Vivo Study

Gholam Reza Valizadeh<sup>1</sup>, Mohammad Mahdi Mahboubian<sup>2</sup>, Amir Hossein Maghsoud<sup>1</sup>,  
Fatemeh Mirzaei<sup>3</sup>, Seyedmousa Motavalli Haghi<sup>1</sup>, Faezeh Foroughi Parvar<sup>1</sup>,  
\*Mohammad Fallah<sup>1</sup>

1. Department of Parasitology and Mycology, School of Medicine, Hamadan University of Medical Sciences, Hamadan, Iran
2. Department of Pharmaceutics, School of Pharmacy, Hamadan University of Medical Sciences, Hamadan, Iran
3. Department of Anatomy, School of Medicine, Hamadan University of Medical Sciences, Hamadan, Iran

Received 23 Mar 2024

Accepted 05 Jun 2024

#### **Keywords:**

Acute; Chronic;  
In vivo;  
Miltefosine;  
Toxoplasmosis

#### **\*Correspondence**

##### **Email:**

[mohfall@yahoo.com](mailto:mohfall@yahoo.com)

#### **Abstract**

**Background:** *Toxoplasma gondii* is one of the most common parasites worldwide. It is of great importance to identify new potential drugs that are effective and less harmful in pregnant women and newborns. We investigated nanoemulsion miltefosine (NEM) in treating experimental acute and chronic toxoplasmosis.

**Methods:** A combination of triacetin, Tween 80, and ethanol (1:2) was used for the development of NEM formulations. The size of NEM was calculated to be 17.463 nm by DLS and TEM. To investigate the performance of miltefosine (MLF), NEM, sulfadiazine (SDZ), and pyrimethamine (PYR) (positive control) in vivo, acute toxoplasmosis was induced in mice by an intraperitoneal injection of RH strain tachyzoites. After five days, the mice were examined for the number and condition of tachyzoites and histopathological changes in the liver and spleen. Chronic toxoplasmosis was investigated in rats and the number and size of brain cysts along with histopathological changes were assessed in different groups.

**Results:** The results of the in vivo assessment of drugs in acute toxoplasmosis showed the following order regarding a decrease in the number of tachyzoites and an increase in survival rate: SDZ&PYR > NEM > MLF. The effects of drugs on chronic toxoplasmosis showed a significant effect of NEM (50%) on reducing the number of cysts compared to SDZ&PYR (10%) and MLF (12%) and reducing the size of NEM brain cysts (21%) compared to SDZ&PYR (5 %) and MLF (8%).

**Conclusion:** Increasing the penetration of NEM through the blood-brain barrier (BBB) and subsequently reducing the number and size of *T. gondii* tissue cysts is a promising new drug in treating chronic toxoplasmosis.



Copyright © 2024 Valizadeh et al. Published by Tehran University of Medical Sciences.

This work is licensed under a Creative Commons Attribution-NonCommercial 4.0 International license.

(<https://creativecommons.org/licenses/by-nc/4.0/>). Non-commercial uses of the work are permitted, provided the original work is properly cited

## Introduction

Toxoplasmosis is a common parasitic disease caused by the protozoan *Toxoplasma gondii*, which affects millions of people worldwide. There are four types of human toxoplasmosis: acquired, congenital, ocular, and toxoplasmosis in immunocompromised individuals. The CNS (central nervous system) is particularly vulnerable as it is less associated with the immune system. After clinical symptoms stop, the cysts formed may last for years (1,2). In individuals with immunodeficiency diseases or treated with immunosuppressive drugs and chronic toxoplasmosis, the parasite may re-emerge and cause CNS lesions with encephalopathy and neurological issues. If the disease is linked to CNS disorders, myocarditis, fever, and skin rashes, prompt treatment is recommended.

Specific care is needed for congenital toxoplasmosis, eye infection, and immunodeficient individuals. Treatment for toxoplasmosis often involves medications such as pyrimethamine, sulfadiazine, doxycycline, minocycline, clindamycin, tetracyclines, atovaquone, macrolides, and azalides. While effective against the fast-replicating form of the parasite (tachyzoites), they may have limited effectiveness against tissue cysts. Managing reactivated toxoplasmosis in immunocompromised patients can be challenging due to low drug absorption and bioavailability (4). Thus, the search for new drugs or improved derivatives is necessary. Nanoemulsions (NEs) offer effective targeted drug delivery, controlling the release and increasing the solubility, providing a safe method for drug delivery (5). Miltefosine (MLF) was originally developed as an anti-cancer drug (6) and has shown therapeutic effects on infectious diseases, including AIDS and parasitic diseases (7,8), as well as being considered for treating Leishmania (9,10). According to the 2023 WHO recommendations, miltefosine is effective in reducing the risk of ocular toxoplasmosis (11). Research in Iran

has shown its therapeutic effects in treating *Leishmania major* (12-15). Our previous study found that nanoemulsion miltefosine (NEM) could combat *T. gondii* in vitro (16).

We aimed to investigate the effect of NEM on acute and chronic toxoplasmosis *in vivo*.

## Materials and Methods

The study used MLF with a molecular weight of 407.576 g·mol<sup>-1</sup> and chemical formula C<sub>21</sub>H<sub>46</sub>NO<sub>4</sub>P from Sigma company (lot# slch7768). SDZ (lot# 0000116925) and PYR (lot# BCBZ7909) were also from Sigma. Triacetin was supplied by Samchun Chemical Co., Ltd, South Korea.

The study used RH strain tachyzoites of *T. gondii* protozoa from mice at Hamadan University of Medical Sciences in Iran. Tachyzoites were collected from the infected mouse's peritoneal area, washed, and counted for subsequent use. A total of 2×10<sup>4</sup> tachyzoites in 1 mL of sterile PBS were used for the study (17).

The composition of triacetin, Tween 80 & ethanol (1:2), and 1.5 mg of MLF were selected to develop NEM formulations. The formulation and characterization of the drug are explained in detail in another article (16).

The SDZ&PYR group received 200 mg/kg of SDZ and 12.5 mg/kg of PYR for in vivo assessment. Miltefosine at 20 mg/kg was given to mice for five days, and rats received a 20 mg/kg dose for 15 d. NEM contained 1.5 mg of MLF per 1 ml, with mice getting 300 $\mu$ l daily and rats getting 3.3 ml. The healthy and patient control group received 0.1 ml of physiological serum orally.

## Ethical considerations

The study protocol with code IR.UMSHA.REC.1400.466 was approved by the Research Ethics Committees of Hamadan University of Medical Sciences.

**Efficacy of drugs in acute infection model**

The study involved assessing acute toxoplasmosis in male mice aged 6-8 wk and weighing 20-25g. They were kept under a 12-hour light/dark cycle at 25±2°C and 55% humidity. Infection was induced by intraperitoneal injection of 1 x 10<sup>4</sup> tachyzoites. Sixty mice were divided into 6 groups and further

divided into two subgroups of 5 each (Table 1). Treatment began on the day of infection and continued for five days. From the fifth day, one subgroup was monitored for survival, while one subgroup from each of the main groups was euthanized and tested for medicinal effects (19).

**Table 1:** Mice grouping in acute and chronic forms of toxoplasmosis

Study Group	Animal model	Age (week)	Weight (gram)	Mice count			Drug Dose/day				
				Total	Group-Mice	Subgroup-Mice	Patient Group	Sham	SDZ&PYR	MLF	NEM
Acute	Mice	6-8	20-25	60	6-10	12-5	0.1 <sup>cc</sup> (Normal saline)	0.3cc	200mg/kg& 12.5mg/kg	20mg/kg	0.3 <sup>cc</sup> (0.44mg MLF load- ed)
Chronic	Rat	8-10	250- 280	30	6-5	-	1 <sup>cc</sup> (Normal saline)	3.3cc	200mg/kg& 12.5mg/kg	20mg/kg	3.3cc(5mg MLF load- ed)

From the second day of treatment to the fifth day, the peritoneum of mice was sampled daily, and a drop of it was placed on a Neubauer slide and the final count was multiplied by 10<sup>4</sup> for calculation in 1 cc (20). During the second to fifth day of treatment, mouse peritoneal samples were taken daily. The samples were placed on a Neubauer slide, and the final count was multiplied by 10,000 for calculation per 1 cc.

The survival periods were recorded daily until all mice died. A part of the spleen and liver removed on the fifth day was slightly pressed between two slides and after drying and Geimsa staining the slides, they were observed by light microscopy through a 100× objective lens. The average number of tachyzoites for each slide was recorded in 10 fields (19).

After overdosing mice with ketamine and xylazine, we examined their abdominal cavities. We isolated the liver and spleen, washed them in normal saline, and preserved them in a 10% formalin buffer. Tissue samples were prepared and stained for histological examination (H&E staining), revealing various pathological changes in the liver and spleen of mice.

To study the effects of drugs on chronic toxoplasmosis, thirty 8-10-week-old male rats

weighing 250-280 g were divided into 6 groups of 5 animals. They were infected with tachyzoites and treated orally 60 d after infection for 15 d. One month after treatment, the rats were euthanized, and their brains were removed and analyzed to assess the drug's impact on reducing tissue cysts in chronic toxoplasmosis (19).

Before initiating treatment in various groups, the patient group underwent autopsies to verify the presence of a brain cyst through cross-section preparation and H&E staining, before the other groups were autopsied (21,22). In chronic toxoplasmosis, cyst burden is higher in the hippocampus (23). We fixed the hippocampus in 10% formalin and prepared pathological slices for studying tissue cysts. The average number of cysts counted in 10 fields was recorded by light microscopy through a 100× objective lens in different groups. The size of tissue cysts in different groups was determined by an ocular micrometer and stage micrometer using an optical microscope (19,24).

**Data Analysis**

The data was analyzed using SPSS 23 (IBM Corp., Armonk, NY, USA), Excel, and Prism 8 software. Results are expressed as mean ±

standard error of the mean at  $P < 0.01$  significance level. One-way ANOVA compared within-group mean differences, while Duncan's post-hoc test compared between-group differences.

## Results

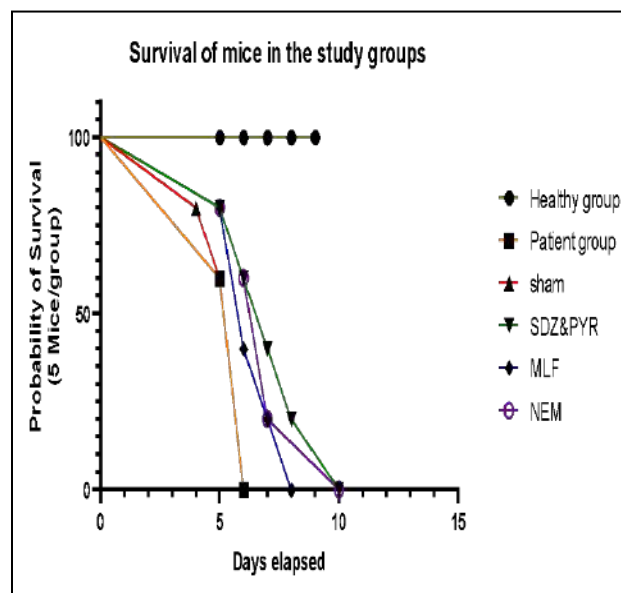
In the healthy control group, all the mice were alive until 70 d of follow-up; however, on the sixth day, all the mice in the patient and

sham groups died. Treated mice in different groups survived up to 10 d after infection. The results of the average survival days in different groups are shown in Table 2. The ANOVA and Duncan test results showed no significant difference in average survival rate between the patient and sham groups ( $P > 0.01$ ), while both these groups differed significantly from the treated groups ( $P < 0.01$ ). The survival rates in order are SDZ & PYR > NEM > MLF (Fig. 1).

**Table 2:** Average days of survival and descriptive Parasite Count (impression smear) of mice with acute toxoplasmosis in treated groups

Study groups	Survival days	Liver		Spleen	
	Reduction%	Mean±S D	Reduction%	Mean±S D	Reduction%
Healthy group	70	-	-	-	-
Patient Group <sup>I</sup>	5.6±0.548	3.4 <sup>b</sup> ±1.14	-	2.4 <sup>b</sup> ±0.54	-
Sham <sup>II</sup>	5.4±0.894	3.4 <sup>b</sup> ±0.89	0	2.6 <sup>b</sup> ±0.89	0
SDZ&PYR <sup>III</sup>	7.2±1.924	0.4 <sup>a</sup> ±0.54	88.2	0.2 <sup>a</sup> ±0.44	91.6
MLF <sup>IV</sup>	6.4±1.140	0.4 <sup>a</sup> ±0.44	88.2	0.6 <sup>a</sup> ±0.54	75
NEM <sup>V</sup>	7.0±1.871	0.2 <sup>a</sup> ±0.44	94.1	0.2 <sup>a</sup> ±0.44	91.6
Sig.	70	<0.001		<0.001	
Duncan	Parasit Count (impression smear) in the organs of infected Mice. Subset for alpha = 0.05				

a: significant with the group I, II at  $P < 0.01$ .  
 b: significant with group III,IV, V at  $P < 0.01$



**Fig. 1:** Comparison of days of survival in the studied groups in acute toxoplasmosis

Table 3 shows the mean daily count of tachyzoites until autopsy. The parasite burden in the peritoneal fluid decreased more in the up to the autopsy. ANOVA results show a significant difference between treatments ( $P < 0.01$ ). Parasite burden reduction rates are

SDZ&PYR positive control group than in the other groups leading

SDZ&PYR > NEM > MLF > Sham = Patient group.

**Table 3:** Descriptive Tachyzoite count in the peritoneal fluid (ml)

<i>Variable</i>	<i>Day2count</i>	<i>Day3count</i>	<i>Day4count</i>	<i>Day5count</i>
	Mean±SD	Mean±SD	Mean±SD	Mean±SD
Patient Group I	22.4 <sup>d</sup> ±1.51	22.8 <sup>d</sup> ±1.30	24.2 <sup>d</sup> ±0.83	26.2 <sup>d</sup> ±0.83
Sham II	22.2 <sup>d</sup> ±1.92	23.6 <sup>d</sup> ±1.14	25.4 <sup>d</sup> ±1.51	25.8 <sup>d</sup> ±1.92
SDZ&PYR III	9.54 <sup>ab</sup> ±0.79	8.4 <sup>ab</sup> ±0.54	5.2 <sup>ab</sup> ±0.83	4.4 <sup>ab</sup> ±0.89
MLF IV	12.6 <sup>ac</sup> ±1.14	11.2 <sup>ac</sup> ±0.83	9.2 <sup>ac</sup> ±0.83	7.2 <sup>ac</sup> ±1.64
NEM V	12.36 <sup>ac</sup> ±1.01	8.6 <sup>ac</sup> ±1.14	7.2 <sup>ac</sup> ±0.83	6.0 <sup>ac</sup> ±1.00

Duncan (Uses Harmonic Mean Sample Size = 5.000) Subset for alpha = 0.05

a: significant with group I,II at  $P < 0.01$ .

b: significant with group IV, V at  $P < 0.01$ .

c: significant with group III at  $P < 0.01$ .

d: significant with group III, IV, V at  $P < 0.01$

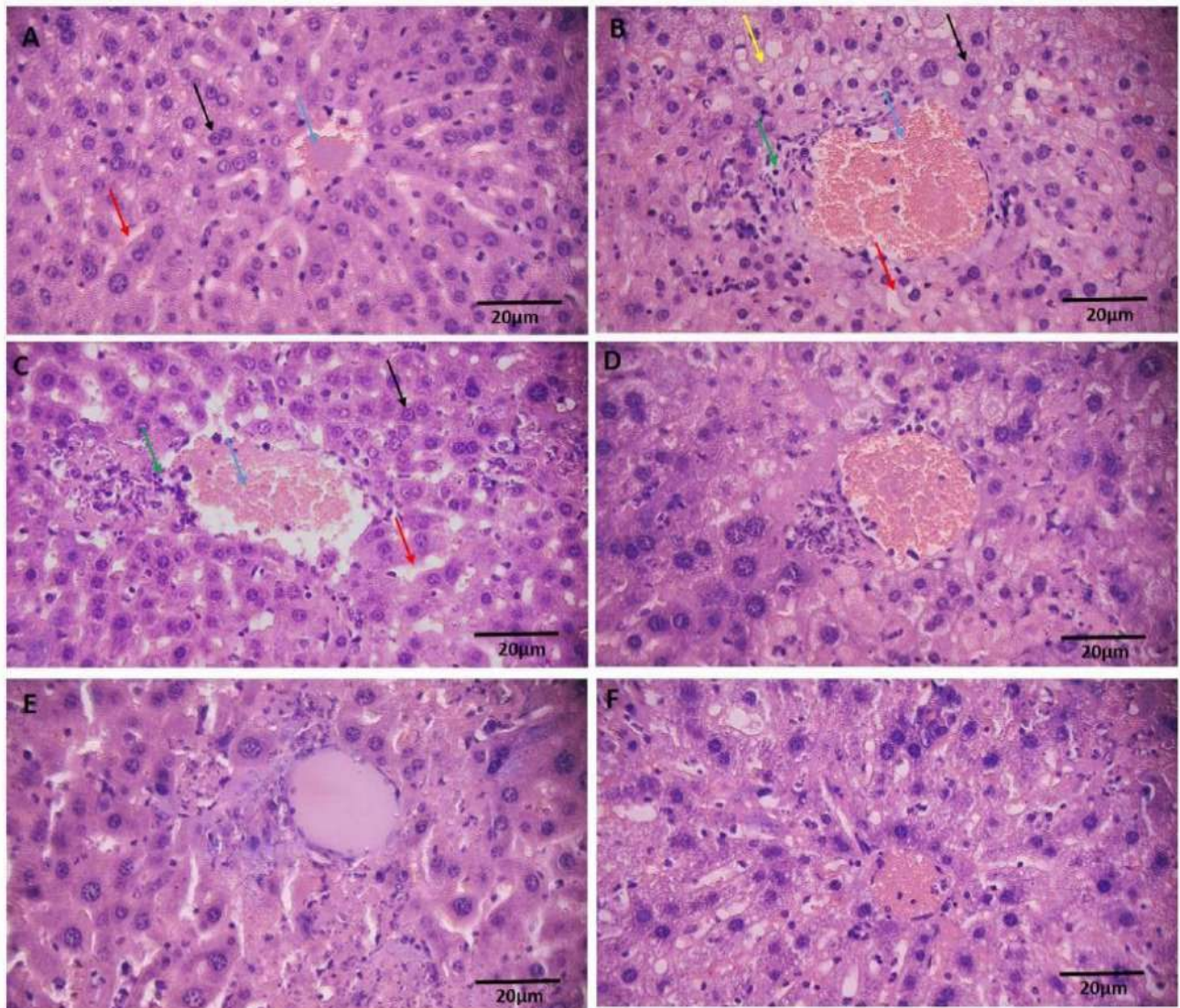
The mean number of tachyzoites in 10 fields per slide was calculated (Table 2). The parasite burden in the liver of the NEM group decreased more than in other groups; however, this rate was the same as the SDZ&PYR group in the spleen. The order of reduction in parasite burden in this stage was as follows: SDZ&PYR = NEM > MLF > sham=patient group. ANOVA results showed a significant difference between the mean number of tachyzoites in different treatments ( $P < 0.001$ ).

***Histopathological changes in the liver and spleen:***

***Liver tissue:***

The healthy group had normal tissue structure (Fig. 2-A), while the patient group showed disrupted tissue structure (Fig. 2-B). The patient group had a disordered hepatic lobule structure, absence of radial hepatocytes,

and a disorganized space of Disse. There was also dilation of the central veins and infiltration of lymph cells around the central vein. The most significant changes included the presence of pyknotic hepatocyte cells with chromatin density and a highly condensed nucleus around the central veins, indicating apoptosis or necrosis in this group. Vacuolation and basal cell formation were significant in this group. No changes in hepatocyte cell size were observed. The sham administration (Fig. 2-C) showed a similar histopathological profile to the patient group. In the SDZ&PYR group, there was an improved radial arrangement of hepatocytes, with reduced squamous cells and lymphoid cell infiltration (Fig. 2-D). Both MLF (Fig. 2-E) and NEM (Fig. 2-F) improved tissue structure, with NEM being more effective, producing a profile similar to the healthy group.

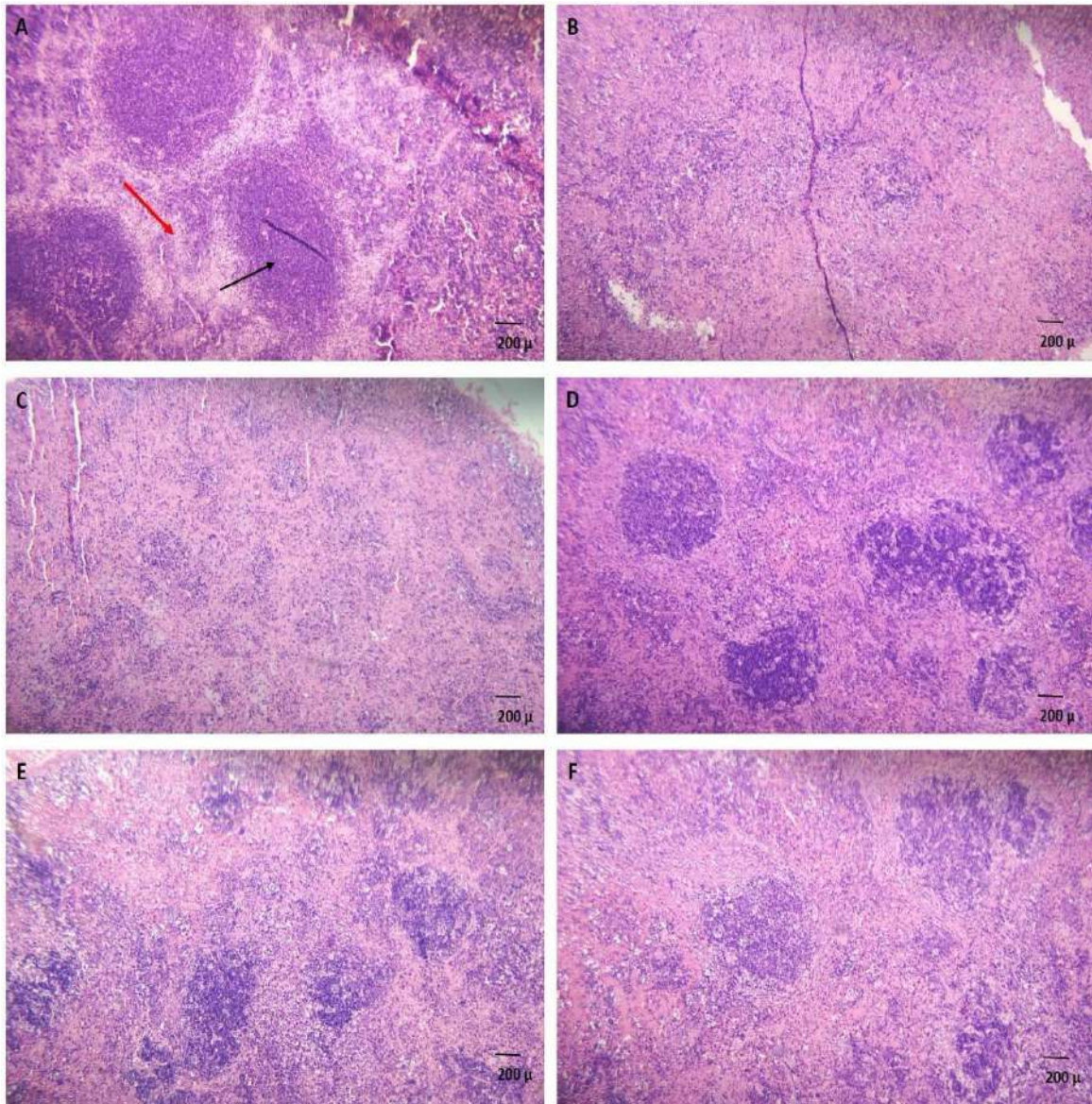


**Fig. 2:** H&E staining of the liver. Healthy group (A), patient group (B), sham (C), SDZ&PYR (D), MLF (E), and NEM (F). Images were taken from the samples at 40x magnification. Blue arrow: central vein. Black arrow: hepatocyte; red arrow: space of Disse; green arrow: pyknotic hepatocytes; yellow arrow: foam cells

### *Spleen tissue*

The healthy group showed normal tissue (Fig. 3-A). In the patient group, (Fig. 3-B), lymph follicles were reduced, and boundaries between the white and red pulps were unclear. Additionally, the white pulp showed diffusion, lymphoid deformation, and giant macrophages. No necrosis or cystic formation was observed in the spleens. In the sham group (Fig. 3-C),

there was no evident healing effect on tissue changes, but in the SDZ&PYR group (Fig. 3-D), the tissue displayed a markedly normal appearance. MLF administration (Fig. 3-E) had a minor effect, while NEM (Fig. 3-F) significantly improved tissue conditions by compressing and organizing the white pulps and restoring the boundary between the red and white pulps.



**Fig. 3:** H&E staining of the spleen. Healthy group (A), patient group (B), Sham (C), SDZ&PYR (D), MLF (E), and NEM (F). Images were taken from the samples at 40x magnification—black arrow: white pulps; red arrow: red pulps

### Chronic infection model

#### *Size and number of brain cysts:*

The mean number and size of cysts were measured in 10 fields using light microscopy with a 100× objective lens in different groups (Table 4). The results of ANOVA and Duncan's post hoc test indicated that the number of brain cysts significantly decreased in the

NEM group compared to the other groups ( $P < 0.01$ ). Similarly, the size of cysts in the NEM group showed a significant decrease compared to other groups ( $P < 0.01$ ). No significant differences were found in the number and size of cysts among the other groups. The cyst number and size reduction in the studied groups were: NEM > MLF > SDZ & PYR > sham = patient group

**Table 4:** Results of counting and size of tissue cysts of crushed rat brain

Method	Groups	Mean±SD	% Reduction	Duncan Subset for alpha:0.05	
				1	2
H&E counting	Patient Group I	3.4 <sup>b</sup> ±1.140	N/D		3.4000
	Sham II	3.2 <sup>b</sup> ±0.447	6%		3.2000
	SDZ&PYR III	2.6 <sup>b</sup> ±1.140	24%		2.6000
	MLF IV	2.6 <sup>b</sup> ±0.547	24%		2.6000
	NEM V	1.4 <sup>a</sup> ±0.547	59%	1.4000	
	Sig.				1.000
F=14.54 /P-value <0.0001 /Significant diff. among means (P<0.05)/ R squared: 0.7518					
H&E Cysts Size	Patient Group I	29.4 <sup>b</sup> ±2.701	N/D		29.4000
	Sham II	29.6 <sup>b</sup> ±4.037	0%		29.6000
	SDZ&PYR III	28.0 <sup>b</sup> ±3.240	5%		28.0000
	MLF IV	27.6 <sup>b</sup> ±2.408	8%		27.6000
	NEM V	23.4 <sup>a</sup> ±1.140	21%	23.4000	
	Sig.				1.000
F=96.09 /P value<0.0001 /Significant diff. among means (P < 0.01)/ R squared: 0.9524					

SD: Standard deviation. N/D: No Data.

Duncan: Means for groups in homogeneous subsets are displayed. Uses Harmonic Mean Sample Size=5.000

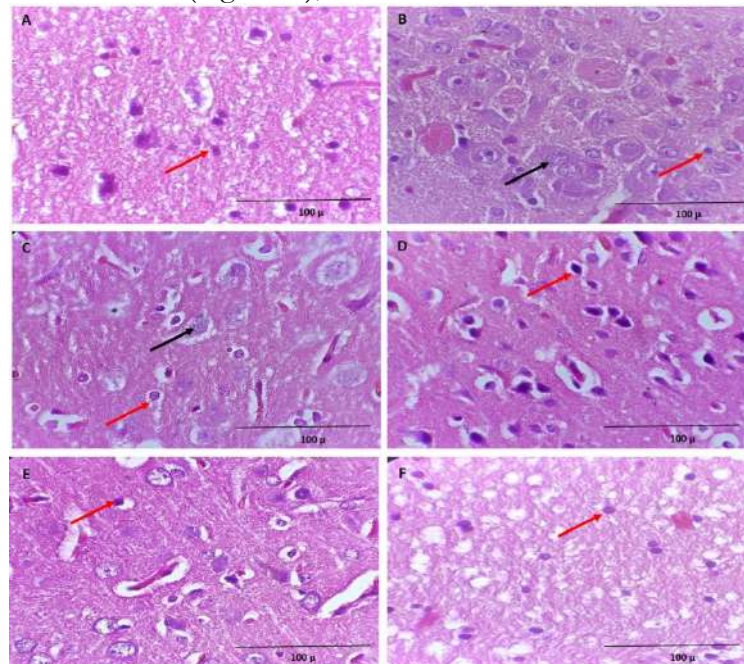
a: significant with group I, II, III, IV at P<0.01.

b: significant with group V at P<0.01

**Histopathological study of brain tissue**

The healthy group (Fig. 4-A) showed normal tissue structure. The patient group (Fig. 4-B) displayed toxoplasmosis cysts and inflammation. Treatment with SDZ&PYR (Fig. 4-D),

MLF (Fig. 4-E), and NEM (Fig. 4-F) reduced cysts and inflammation, with NEM showing the most effective results similar to the healthy group.



**Fig. 4:** H&E staining of the brain tissue. Healthy (A), patient (B), sham(C), SDZ&PYR (D), MLF(E), and NEM(F) groups. Images were taken from the samples at 40x magnification. Red arrow: oligodendrocytes; black arrow: cysts



## Discussion

Limited research has been done on the effects of miltefosine on *T. gondii*, as well as on the impact of miltefosine nanomedicine. We will review relevant studies to discuss the results obtained.

The SDZ&PYR group showed the longest survival rate compared to other groups, followed by the NEM and MLF, respectively. In one study, the average survival rate increased up to 7 d after infection in the MLF group, which is consistent with our results (up to 6 d in the MLF group) (19). NEM could increase the survival rate by up to 10 d. In another study in Germany, researchers observed a significant reduction in infected cells in J774A macrophages after incubation with MLF (30 µg/ml) and *T. gondii* tachyzoites. After 14 d, both the MLF and atovaquone groups showed a significant decrease in brain cysts compared to the control group, with no significant difference between the treatment groups. We found that SDZ&PYR was more effective in reducing the parasite burden. Barakat et al. also used manual calculation of tachyzoites and DNA concentrations of the *Toxoplasma* P29 gene to estimate reduction after treatment (26). It is recommended to use molecular methods for accurate estimation.

### *Histopathological study of the liver and spleen:*

Compared to other medicines, NEM was more effective in improving tissue conditions in comparison to the animals in the test group, and the tissue appearance was very similar to the healthy ones. In a study by Khademvatan et al. (2024), infected mice treated with miltefosine produced significantly more IFN-γ compared to other groups ( $P < 0.001$ ). This, alongside miltefosine's lower cytotoxicity, may be a reason for improving the condition of the liver and spleen of mice with acute toxoplasmosis compared to other groups (27). Some workers could not find significant histopathological changes in any of the treatment groups compared to the patient group (19). In our study, the NEM

performed well in reducing the relative parasite burden and improving liver and spleen tissue in acute toxoplasmosis, which can be considered a promising agent (after further investigations in clinical trials) for the treatment of acute toxoplasmosis (16).

### *Evaluation of the reduction in the size and number of cysts*

MLF reduced cysts by 12%, and NEM by 50%. SDZ & PYR had a 10% decrease and were ineffective in reducing brain cysts. The nanoemulsion without the drug did not significantly reduce cysts compared to the patient group. In a study, the patient group had a brain cyst burden of  $14.40 \pm 2.91$ . The MLF group ( $1.32 \pm 3.20$ ) saw a 77.7% reduction, and the SDZ & PYR group ( $1.48 \pm 2.0$ ) saw an 86% reduction compared to the patient group (19). In another study counted brain cysts based on *T. gondii* MORC gene expression and BCLA as a cyst-specific antigen. Future studies should use more accurate methods for counting cysts (28).

In this study on chronic toxoplasmosis in rats, NEM reduced brain cyst size by 21%, significantly more than MLF's 8% decrease and SDZ&PYR's 5% decrease ( $P < 0.01$ ). Some workers found that miltefosine inhibited parasites spread in the CNS during *N. caninum* infection in mice (29). However, others found that brain cysts treated with MLF had a 41.7% size reduction, compared to 19.7% with SDZ & PYR. MLF-treated cysts were smaller and rounder (19). In terms of brain tissue histopathology, NEM was more effective in reducing tissue inflammation and lymphoid cell infiltration around blood vessels compared to other drugs. MLF and SDZ & PYR were also able to improve tissue conditions and reduce inflammation to some extent. It seems that NEM, with its small size (17.46), effectively passed through the BBB. Some investigators demonstrated that polymer nanoparticles as carriers improved drug delivery to the CNS, effectively controlling infection in animal models (30). Another found that MLF inhibits

phosphatidylcholine synthesis and cytochrome c oxidase. It also activates a specific parasite  $Ca^{2+}$  channel different from its human counterpart and has a positive effect on the host's immune system (31). NEM shows promise in reducing brain cysts and warrants further study.

## Conclusion

NEM has been demonstrated to be effective in treating chronic toxoplasmosis in a mouse model. The small size of nanoemulsions can be an effective strategy to deliver drugs to areas, such as the brain. Improving the intracellular penetration of MLF as a nanoemulsion to fight the intracellular parasite *T. gondii* is promising. NEM's appropriate cytotoxicity (CC50:75.7 $\mu$ g/mL, SI=2.66) and in vitro, performance of the drug in a previous study promises the emergence of a suitable drug candidate for the treatment of chronic toxoplasmosis.

## Acknowledgements

This work was supported in parts financially by the Deputy for Research and Technology, Hamadan University of Medical Sciences who hereby gratefully acknowledged.

## Conflicts of Interest

The authors declare that there is no conflict of interest.

## References

1. Meerburg BG, Kijlstra A. Changing climate-changing pathogens: *Toxoplasma gondii* in North-Western Europe. *Parasitol Res.* 2009;105(1):17-24.
2. Montoya JG, Liesenfeld O. Toxoplasmosis. *Lancet.* 2004;363(9425):1965-76.
3. Montazeri M, Mehrzadi S, Sharif M, Sarvi S, Shahdin S, Daryani A. Activities of anti-*Toxoplasma* drugs and compounds against tissue cysts in the last three decades (1987 to 2017), a systematic review. *Parasitol Res.* 2018;117(10):3045-57.
4. Montazeri M, Sharif M, Sarvi S, Mehrzadi S, Ahmadpour E, Daryani A. A Systematic Review of In vitro and In vivo Activities of Anti-*Toxoplasma* Drugs and Compounds (2006-2016). *Front Microbiol.* 2017; 8:25.
5. Pandey P, Gulati N, Makhija M, Purohit D, Dureja H. Nanoemulsion: A Novel Drug Delivery Approach for Enhancement of Bioavailability. *Recent Pat Nanotechnol.* 2020;14(4):276-293.
6. van Blitterswijk WJ, Verheij M. Anticancer alkylphospholipids: mechanisms of action, cellular sensitivity and resistance, and clinical prospects. *Curr Pharm Des.* 2008;14(21):2061-74.
7. Polat ZA, Obwaller A, Vural A, Walochnik J. Efficacy of miltefosine for topical treatment of *Acanthamoeba keratitis* in Syrian hamsters. *Parasitol Res.* 2012;110(2):515-20.
8. Garg R, Tremblay MJ. Miltefosine represses HIV-1 replication in human dendritic cell/T-cell cocultures partially by inducing secretion of type-I interferon. *Virology.* 2012;432(2):271-6.
9. Dorlo TP, Balasegaram M, Beijnen JH, de Vries PJ. Miltefosine: a review of its pharmacology and therapeutic efficacy in the treatment of leishmaniasis. *J Antimicrob Chemother.* 2012;67(11):2576-97.
10. Kumar, Awanish (2013). *Leishmania* and Leishmaniasis. Springer Science & Business Media. p. 39. ISBN 9781461488699. Archived from the original on 2017-09-10.
11. Advisory Committee on Safety of Medicinal Products (ACSoMP): Measures to minimize the risk of ocular adverse events with miltefosine Internet Document: 12 Apr 2023.
12. Latifi A, Mohebbali M, Yasami S, Soleimani M, Rezaian M, Kazemirad E. Comparing cytotoxicity and efficacy of miltefosine and standard antimicrobial agents against *Acanthamoeba* trophozoites and cyst forms: An in vitro study. *Acta Trop.* 2023;247:107009.
13. Najafian HR, Mohebbali M, Rezayat SM, et al. Nanoliposomal miltefosine for the treatment of cutaneous leishmaniasis caused

- by *Leishmania major* (MRHO/IR/75/ER): The drug preparation and in vitro study. IJPRAS, 2016, 5(3):97-107.
14. Mohebbali M, Fotouhi A, Hooshmand B, et al. Comparison of miltefosine and meglumine antimoniate for the treatment of zoonotic cutaneous leishmaniasis (ZCL) by a randomized clinical trial in Iran. Acta Trop. 2007;103(1):33-40.
  15. Esmaeili J, Mohebbali M, Edrissian GH, et al. Evaluation of miltefosine against *Leishmania major* (mrho/ir/75/er): in vitro and in vivo studies. Acta Med Iran. 1970;46(3):191-196.
  16. Valizadeh GR, Mahboobian MM, Maghsood AH, et al. Development and evaluation of miltefosine-loaded nanoemulsions on in vitro culture of *Toxoplasma gondii*. Nanomed J. 2024;11(2):172-86.
  17. Ebrahimzadeh MA, Taheri MM, Ahmadvan E, et al. Anti-*Toxoplasma* Effects of Methanol Extracts of *Feijoa sellowiana*, *Quercus castaneifolia*, and *Allium paradoxum*. J Pharmacopuncture. 2017;20(3):220-226.
  18. Romand S, Pudney M, Derouin F. In vitro and in vivo activities of the hydroxynaphthoquinone atovaquone alone or combined with pyrimethamine, sulfadiazine, clarithromycin, or minocycline against *Toxoplasma gondii*. Antimicrob Agents Chemother. 1993;37(11):2371-8.
  19. Eissa MM, Barakat AM, Amer EI, Younis LK. Could miltefosine be used as a therapy for toxoplasmosis? Exp Parasitol. 2015;157:12-22.
  20. Al-Zanbagi NA. In vivo effect of some home spices extracts on the *Toxoplasma gondii* tachyzoites. J Family Community Med. 2009;16(2):59-65.
  21. Chew WK, Wah MJ, Ambu S, Segarra I. *Toxoplasma gondii*: determination of the onset of chronic infection in mice and the in vitro reactivation of brain cysts. Exp Parasitol. 2012;130(1):22-5.
  22. Saraei M, Ghaderi Y, Mosavi T, Shahnazi M, Keshavarz H, Shojaee S. Brain cystogenesis capacity of *Toxoplasma gondii*, avirulent Tehran strain in mice. Asian Pac J Trop Dis. 2014;4:S739-S42.
  23. Ma J, He JJ, Wang M, Hou JL, Elsheitkha HM, Zhu XQ. *Toxoplasma gondii* induces metabolic disturbances in the hippocampus of BALB/c mice. Parasitol Res. 2021;120(8):2805-2818.
  24. Nasr ME, Abd El Hamid AH, Aly NSM, et al. Efficacy of azithromycin on experimental toxoplasmosis infected mice. J Egypt Soc Parasitol. 2020;50(2):293-299.
  25. Otto, R.R. The antiparasitic effect of Hexadecylphosphocholine (Miltefosine) against *Toxoplasma gondii* in vitro and in vivo. Department of Medicine Charite University Medicine, Berlin. 2011. doi.org/10.17169/refubium-7485.
  26. Barakat AM, El-Razik KAA, El Fadaly HAM, et al. Parasitological, Molecular, and Histopathological Investigation of the Potential Activity of Propolis and Wheat Germ Oil against Acute Toxoplasmosis in Mice. Pharmaceutics. 2023;15(2):478.
  27. Khademvatan S, Yousefi E, Asadi N, Abasi E. Evaluation of In Vitro Cytotoxic and Apoptotic Effects of miltefosine on the *Toxoplasma gondii* RH Strain. Iran J Parasitol. 2024;19(1):52-60.
  28. Dard C, Swale C, Brenier-Pinchart MP, et al. A brain cyst load-associated antigen is a *Toxoplasma gondii* biomarker for serodetection of persistent parasites and chronic infection. BMC Biol. 2021;19(1):25.
  29. Gondim BLC, da Silva Catarino J, de Sousa MAD, et al. Nanoparticle-Mediated Drug Delivery: Blood-Brain Barrier as the Main Obstacle to Treating Infectious Diseases in CNS. Curr Pharm Des. 2019;25(37):3983-96.
  30. Debache K, Hemphill A. Effects of miltefosine treatment in fibroblast cell cultures and in mice experimentally infected with *Neospora caninum* tachyzoites. Parasitology. 2012;139(7):934-44.
  31. Benaim G, Paniz-Mondolfi A. Unmasking the Mechanism behind Miltefosine: Revealing the Disruption of Intracellular Ca<sup>2+</sup> Homeostasis as a Rational Therapeutic Target in Leishmaniasis and Chagas Disease. Biomolecules. 2024;14(4):406.