



Tehran University of Medical
Sciences Publication
<http://tums.ac.ir>

Iran J Parasitol

Open access Journal at
<http://ijpa.tums.ac.ir>



Iranian Society of Parasitology
<http://isp.tums.ac.ir>

Case Report

Postpartum Spontaneous Rupture of a Primary Splenic Hydatid Cyst: A Case Report

*Aabid Ashraf¹, Ritika Mittal²

1. Department of General Surgery, Gulf Asian Medical Center, Al Jubail, Saudi Arabia
2. MM Medical College and Hospital, Solan, India

Received 16 Feb 2024

Accepted 01 Apr 2024

Keywords:

Hydatid cyst;
Spleen;
Pregnancy;
Rupture;
Splenectomy

***Correspondence Email:**

dr.aabid.ashraf@gmail.com

Abstract

Hydatid disease is endemic in some regions of the world. Even in endemic regions, splenic hydatid cysts are rare, especially in pregnancy. The most serious presentation is intra peritoneal rupture, which is a surgical emergency. Exploration with splenectomy is the favoured management. We present a case of splenic hydatid cyst, detected late in pregnancy, with intraperitoneal rupture in the postpartum period. Cystic lesions located anywhere in the body in endemic regions could be hydatid cysts. Prompt treatment should be planned immediately on detection in order to prevent potentially serious complications like rupture.

Introduction

Hydatid disease is fairly common in endemic areas. The most frequent location of the hydatid cysts is liver (1). Splenic cysts are uncommon (2). Majority of these are hydatid cysts in endemic regions. Splenic cysts are extremely rare in pregnancy

with only few reports of hydatid cyst spleen in pregnancy and negligible data of its presentation in the postpartum period.

Among the varied presentations of primary hydatid cyst spleen, intraperitoneal rupture is the most serious and potentially life threatening (3,4). Although the risk of rupture is more during pregnancy but it can occur any time,



Copyright © 2024 Ashraf et al. Published by Tehran University of Medical Sciences.

This work is licensed under a Creative Commons Attribution-NonCommercial 4.0 International license.

(<https://creativecommons.org/licenses/by-nc/4.0/>). Non-commercial uses of the work are permitted, provided the original work is properly cited

even in the postpartum period. Management during pregnancy is not standardized but in postpartum period, routine is followed, with the favoured treatment being splenectomy. Antenatal detection should entail a clear plan and if non-operative treatment is decided upon till the termination of pregnancy, surgical treatment should ensue as soon as possible in the postpartum period to avert rupture and its potentially lethal consequences.

Case Presentation

A 23 year old female, home-maker, hailing from rural Kashmir, India, reported in 2018, with complaints of pain in left upper abdomen for one day. The pain was constant, progressively increasing in intensity and distribution and unaccompanied by any other symptom. Patient had a normal vaginal delivery 25 days prior. Just a week before her delivery a USG at some other centre had revealed a cyst measuring 102.5 x 93.1 x 104.6 mm cyst between spleen and left kidney (Fig. 1). Patient underwent normal vaginal delivery at a rural centre and was lost to follow up till she reported to our department. Patient denied any history of trauma or drug intake. Informed consent has been obtained from the patient.

On examination she was found to be conscious, oriented with respect to time, place and person. Her pulse was 104 bpm, regular with a blood pressure of 126/76 mmHg, respiratory rate of 16/min and a temperature of 99° F. Abdominal examination revealed a mildly distended abdomen with tenderness, rigidity and guarding predominantly on left side of the abdomen. Examination of other systems was unremarkable. Digital rectal examination was normal. Gynaecological assessment was also normal. Investigations revealed a total leucocyte count of $9.8 \times 10^3/\mu\text{L}$, with 89.5 % neutrophils, 3 % lymphocytes, haemoglobin of 12.6 G/dL and platelet count of $261 \times 10^3/\mu\text{L}$. Blood glucose was 67 mG/dL, urea 33 mG/dL, creatinine 1.34 mG/dL. LFT was normal except for total protein of 5.5G/dL and albumin of 2.99 G/dL. Serum lipase was 24 U/L. Chest radiograph was unremarkable. USG revealed a cyst in the spleen measuring 82.1 x 51 x 63.8 mm with detached membrane and pelvic ascitis (Fig. 1) . CECT abdomen and pelvis showed Intra-splenic and subcapsular, partially collapsed, ruptured hydatid cyst along the medial aspect with mild pelvic and minimal abdominal ascitis. There was no evidence of any cyst elsewhere (Fig. 2,3).

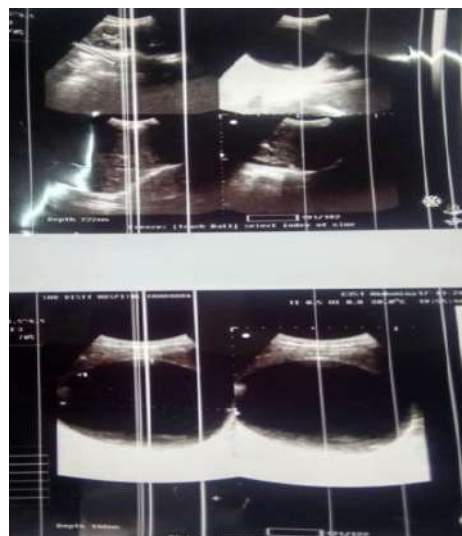

Fig. 1: USG in the ante natal period revealing a large cyst between spleen and left kidney

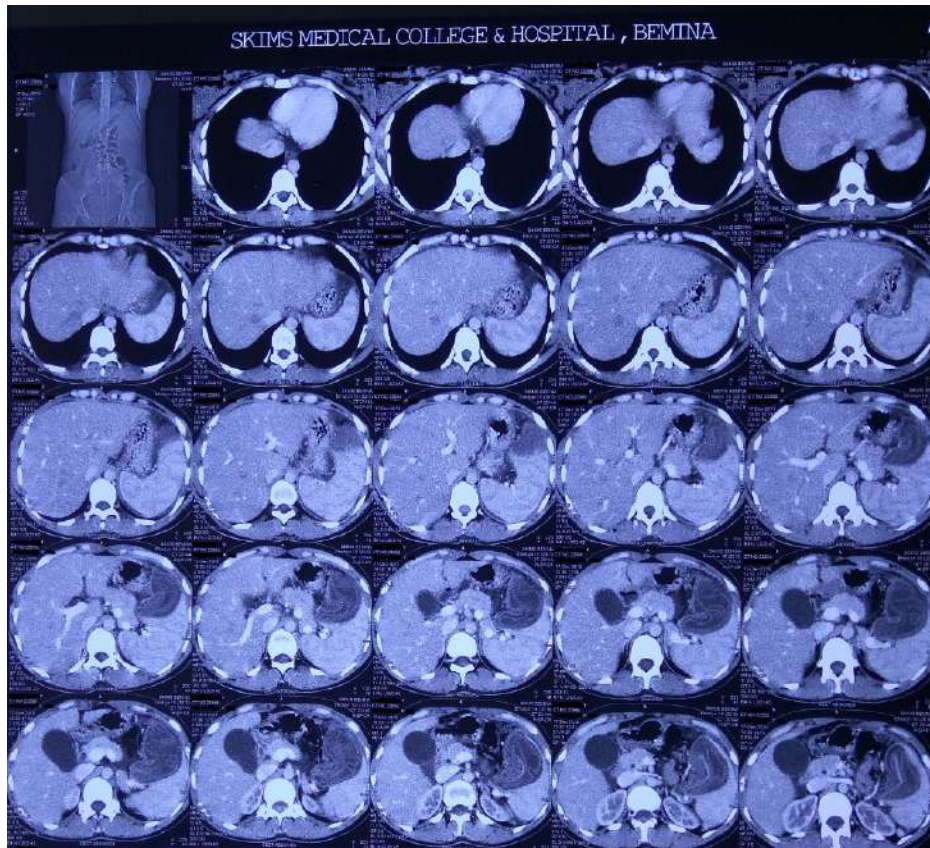


Fig. 2: CT images showing ruptured, partially collapsed hydatid cyst in the spleen

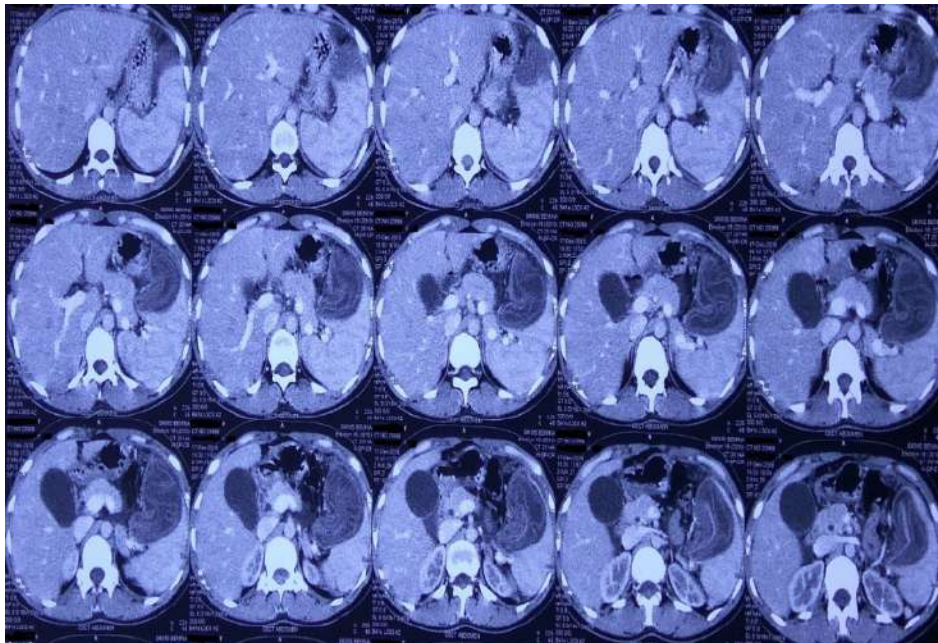


Fig. 3: CT images showing ruptured, partially collapsed hydatid cyst in the spleen

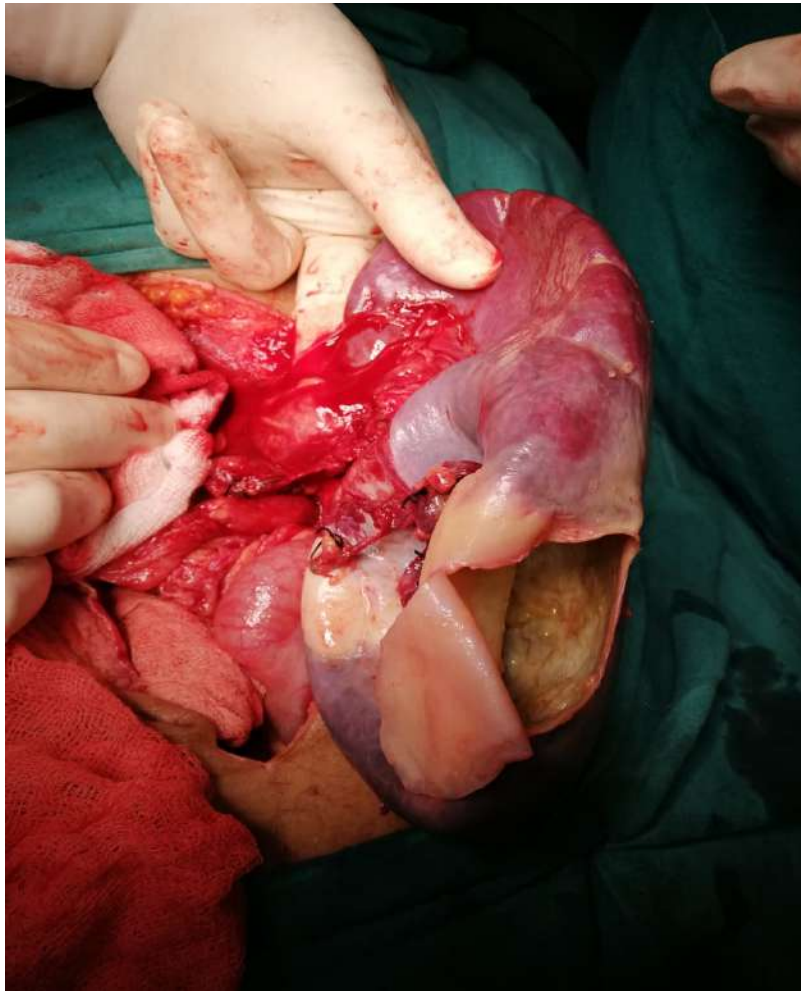

Fig. 4: Mobilised spleen delivered through wound before dividing pedicle showing ruptured cyst

Exploratory laparotomy was done. Intra operative findings were an enlarged spleen with a ruptured cyst, approximately 10 x 8 cm in the inferomedial aspect with membranes seen exuding through the site of rupture (Fig. 4). Dense adhesions were found between cyst, omentum and stomach. About 600 ml off white, turbid fluid was found in abdomen and pelvis. Liver and other intra-abdominal viscera were grossly normal. Splenectomy followed by peritoneal lavage and scolical irrigation was carried out. Drains were placed in splenic fossa and pelvis. Post-operative period was uneventful. On follow up patient is doing well. Follow up USG is unremarkable. Histopathological examination confirmed hydatid cyst of

spleen (*Echinococcus granulosus*) with areas of hemorrhage and inflammation in the surrounding parenchyma. Post splenectomy vaccination was carried out after two weeks.

Discussion

Echinococcosis or Hydatid disease is a zoonotic parasitic disease, endemic in certain regions of the world like Mediterranean, Mid East, South America, Australia, South Asia including India. Canines are the definitive hosts and sheep, goat, cattle are the intermediate hosts. Man is an accidental host with no role in the transmission. Route of transmission is feco-oral, most often from soil or wa-

ter contaminated by dog feces. Cyst is the larval stage of the parasite that develops in man.

Liver is the most common site of these cysts and the infestation is usually caused by *Echinococcus granulosus*. Spleen is rarely involved, more so when it's an isolated site of involvement, accounting for nearly 4% of abdominal hydatid cysts (5-8). Primary splenic hydatid cyst is thought to result either from arterial seeding bypassing liver and lungs or via possible venous reflux through the portal vein. Secondary splenic hydatid cysts result from systemic dissemination or following intraperitoneal rupture of liver hydatid cysts (9,10).

Splenic hydatid cysts may be asymptomatic, detected incidentally (11) or may present with vague abdominal pain, early satiety, dyspepsia, dyspnoea due to pushing up of the diaphragm (12), constipation, local compressive symptoms or as a mass (13,14). Splenic hydatid cyst may present acutely with rupture, which is most commonly due to trauma and less frequently spontaneous (15). Rupture can be into neighboring viscera like colon (16) or into the pleural or peritoneal cavity. Free intraperitoneal rupture can lead to anaphylaxis that can be potentially fatal (3,4). Intraperitoneal rupture can present with clinical features ranging from vague abdominal pain to frank peritonitis with typical signs. Intraperitoneal rupture of splenic hydatid cyst is exceedingly rare (17-19).

Although hydatid disease is found in pregnancy with an incidence of 1 in 20000 to 1 in 30000 (20,21) but liver is the usual site of involvement in pregnancy as well. Splenic cysts in pregnancy are extremely rare (22). Most splenic cysts in endemic areas are hydatid cysts (23). There are very few reports of hydatid cyst of spleen in pregnancy (24,25). Pregnancy increases the risk of rupture owing to raised intra-abdominal pressure. There is a scant account of spontaneous rupture of hepatic hydatid cysts during pregnancy. However, there is hardly any literature documenting spontaneous rupture in the postpartum period as the cysts are more likely to rupture during ante-

natal period or delivery owing to raised intra-abdominal pressures. Thus ante natal detection should be accompanied by meticulous planning and follow up so as to prevent potentially fatal complication like rupture or haemorrhage. Differential diagnoses include epidermoid, pseudocyst, abscess, hemorrhage, neoplasm.

USG and CT are the main stay of diagnosis especially in acute settings to rule out other causes of acute abdomen, with CT being superior (26-28). The characteristic appearance varies as per duration, location, presence of secondary infection or rupture. Serological tests like ELISA, Immunoelectrophoresis, or Indirect Hemagglutination test have limited feasibility in ruptured hydatid cyst, but nevertheless can be used when the diagnosis is in doubt (29). MRI has also been used in cases where USG/CT are inconclusive. Management of the ruptured cyst warrants an urgent laparotomy (19). Splenectomy is the treatment of choice particularly in ruptured cysts (30,31). Owing to post splenectomy complications including sepsis related deaths in 1.9 % of adults and 4 % of children, a number of spleen preserving procedures have come up (32). There appears to be no significant difference between the rates of recurrence following splenectomy and spleen preserving procedures (33,34). Despite this the most feasible option in a ruptured hydatid cyst of spleen continues to be splenectomy. Even though the optimal management of splenic cysts in pregnancy is yet to be established, but the management in postpartum period especially in case of rupture is straightforward (22). A thorough lavage followed by scolicidal irrigation is necessitated to minimize seeding and recurrence. Various scolicidal agents like cetrimide, povidone iodine, hypertonic saline, chlorhexidine can be used. Laparoscopic procedures have been done in splenic hydatid cyst but in elective, uncomplicated cases (35,36). Laparoscopic approach on emergent basis in case of a ruptured cyst remains largely unattempted. Pre-operative medical treatment with albendazole

is not possible in patients who present with ruptured cysts, but should be started postoperatively as soon as possible. Patients should be followed up with USG and serological tests at shorter intervals.

Conclusion

Hydatid cyst should be included in the differential diagnosis of any cystic lesion in a patient from endemic region. In pregnant patients splenic cysts should be meticulously evaluated. A management plan with emphasis on assessment of the risk of rupture should be formulated at the outset of diagnosis even in ante partum detection. Surgical treatment should be done as early as feasible.

Abbreviations

LFT	Liver Function test
USG	Ultrasonography
CT	Computed Tomography
CECT	Contrast Enhanced Computed Tomography
MRI	Magnetic Resonance Imaging
ELISA	Enzyme linked Immuno Sorbent Assay

Acknowledgments

No funding was sought.

Conflict of Interest

Non-declared.

References

1. Khalili N, Iranpour P, Khalili N, Haseli S. Hydatid Disease: A Pictorial Review of Uncommon Locations. *Iran J Med Sci.* 2023;48(2):118-129.
2. Celebi S, Basaranoglu M, Karaaslan H, et al. A splenic hydatid cyst case presented with lumbar pain. *Intern Med.* 2006; 45(17):1023-4.
3. Bitton M, Kleiner-Baumgarten A, Peiser J, Barki Y, Sukenik S. Anaphylactic shock after traumatic rupture of a splenic echinococcal cyst. *Harefuah.* 1992;122(4):226-8.
4. Sedat Belli, Sami Akbulut, Gurcan Erbay, Nazım Emrah Kocer. Spontaneous giant splenic hydatid cyst rupture causing fatal anaphylactic shock: A case report and brief literature review. *Turk J Gastroenterol.* 2014; 25: 88-91.
5. Fernández-Ruiz M, Guerra-Vales JM, Enguita-Valls AB, Vila-Santos J, García-Borda FJ, Morales Gutiérrez C. Splenic hydatid cyst, a rare location of extrahepatic echinococcosis: Report of six cases. *Eur J Intern Med.* 2008;19(7):e51-3.
6. Örmeci N, Soykan I, Palabiyikoğlu M, Idilman R, Erdem H, et al. A new therapeutic approach for treatment of hydatid cysts of the spleen. *Dig Dis Sci.* 2002; 47(9): 2037–44.
7. Durgun V, Kapan S, Kapan M, Karabiçak I, Aydogan F. Primary splenic hydatidosis. *Dig Surg.* 2003; 20(1): 38–41.
8. Manouras AJ, Nikolaou CC, Katergiannakis VA, Apotolidis NS, Golematis BC. Spleen-sparing surgical treatment for echinococcosis of the spleen. *Br J Surg.* 1997; 84: 1162.
9. Safioleas M, Misiakos E, Manti C. Surgical treatment for splenic hydatidosis. *World J Surg.* 1997;21:374–7.
10. Prousalidis J, Tzardinoglou K, Sgouradis L, Katsohis C, Aletras H. Uncommon sites of hydatid disease. *World J Surg.* 1998;22:17–22.
11. Qureshi MA, Hafner CD. Clinical manifestations of splenic cysts: Study of 75 cases. *Am Surg.* 1965;31:605–8.
12. Alfageme I, Martin M, Hernandez J, Huertas C. Rupture of a long-standing splenic hydatid cyst into the bronchial tree. *Clin Infect Dis.* 1994;19:992–4.
13. Mc Manus DP, Zhang W, Li J, Bartley PB. Echinococcosis. *Lancet.* 2003; 362: 1295–304.
14. Rasheed K, Zargar SA, Telwani AA. Hydatid cyst of spleen: a diagnostic challenge. *N Am J Med Sci.* 2013; 5: 10–20.

15. Herrera Merino N, Díaz del Río Botas M, Marinelli Ibarreta A, San José Borreguero A, Abascal Morte J, Colas Vicente A. Acute abdomen caused by spontaneous rupture of splenic hydatid cyst. *Rev Esp Enferm Dig.* 1990;78:102–4.
16. Uriarte C, Pomares N, Martín M, Conde A, Alonso N, Bueno MG. Splenic hydatidosis. *Am J Trop Med Hyg.* 1991;44:420–3.
17. Dirican A, Yilmaz M, Unal B, et al. Ruptured hydatid cysts into the peritoneum: a case series *Eur J Trauma Emerg Surg.* 2010; 36: 375-9.
18. Limas C, Soultanidis C, Kirmanidis MA, et al. Management of abdomen hydatidosis after rupture of a hydatid splenic cyst: a case report. *Cases J.* 2009; 2: 8416.
19. Erel S, Kilicoglu B, Kismet K, Gollu A, Akkus MA. Peritoneal hydatid cyst perforation: a rare cause of emergency abdominal surgeries. *Adv Ther.* 2008; 25: 943-50.
20. Rahman MS, Rahman J, Lysikiewicz A. Obstetric and gynaecological presentations of hydatid disease. *Br J Obstet Gynaecol.* 1982;89:665–670.
21. Ustunsoz B, Alemdaroglu A, Bulakbasi N, Uzar AI, Duru NK. Percutaneous treatment of hepatic hydatid cyst in pregnancy. *Arch Gynecol Obstet.* 1999;262:181–184.
22. Dabrowski W, Luterek K, Szczepanik A, Niedzwiedzka B, Wielgos M. Management of a large splenic cyst in pregnancy – a case report. *Ginekol Pol.* 2012;83:862–4.
23. Gharaibeh KI. Laparoscopic excision of splenic hydatid cyst. *Postgrad Med J.* 2001;77:195–6.
24. Can D, Oztekin O, Oztekin O, et al. Hepatic and splenic hydatid cyst during pregnancy: a case report. *Arch Gynecol Obstet.* 2003; 268:239-240.
25. Menendez-Arzac R, Sanjuan H, Rebolledo G, et al. Splenic hydatid cyst. Case report of a pregnant woman. *Rev Gastroenterol Mex.* 2002; 67:195-198.
26. Dachman AH, Ros PR, Murari PJ, Olmsted WW, Lichtenstein JE. Nonparasitic splenic cysts: a report of 52 cases with radiologic-pathologic correlation. *AJR Am J Roentgenol.* 1986; 147(3):537-42.
27. Caballero P, Ocon E, Robledo AG, Díaz FJ. Splenic hydatid cyst opening. *AJR Am J Roentgenol.* 1986; 147(4):859-60.
28. Safioleas M, Misiakos E, Manti C, Katsikas D, Skalkeas G. Diagnostic evaluation and surgical management of hydatid disease of the liver. *World J Surg.* 1994; 18(6):859-65.
29. Sarkari B, Fatemi Esfedan A, et al. Clinical and Molecular Evaluation of a Case of Giant Primary Splenic Hydatid Cyst: A Case Report. *Iran J Parasitol.* 2016;11(4):585-590.
30. Dar MA, Shah OJ, Wani NA, Khan FA, Shah P .Surgical management of splenic hydatidosis. *Surg Today.* 2002; 32(3):224-9.
31. Arikanoglu Z, Taskesen F, Gumus H, et al. Selecting a surgical modality to treat a splenic hydatid cyst: total splenectomy or spleen-saving surgery? *J Gastrointest Surg.* 2012;16(6):1189-93.
32. Ellison EC, Fabri PJ Complications of splenectomy. Etiology, prevention, and management. *Surg Clin North Am.* 1983; 63(6):1313-30.
33. Atmatzidis K, Papaziogas B, Mirelis C, Pavlidis T, Papaziogas T .Splenectomy versus spleen-preserving surgery for splenic echinococcosis. *Dig Surg.* 2003; 20(6):527-31.
34. Rahmani SH, Mohammadi Tofigh A. Spleen-Preserving surgery versus splenectomy for splenic hydatid cyst. Ten years' experience. *Shiraz E Med J.* 2008-9;2:82–6.
35. Khoury G, Abiad F, Geagea T, Nabout G, Jabbour S. Laparoscopic treatment of hydatid cysts of the liver and spleen. *Surg Endosc.* 2000; 14(3):243-5.
36. Ballaux KE, Himpens JM, Leman G, Van den Bossche MR. Hand-assisted laparoscopic splenectomy for hydatid cyst. *Surg Endosc.* 1997; 11(9):942-3.