



Tehran University of Medical  
Sciences Publication  
<http://tums.ac.ir>

## Iran J Parasitol

Open access Journal at  
<http://ijpa.tums.ac.ir>



Iranian Society of Parasitology  
<http://isp.tums.ac.ir>

### Case Report

## An Unusual Cause of Insidious Back and Shoulder Pain in a Man: A Case Report

\*Oğuz Kaya<sup>1</sup>, Nevzat Gönder<sup>2</sup>

1. Department of Orthopaedics and Traumatology, Health Sciences University Elazığ Fethi Sekin City and Research Hospital, Elazığ, Turkey
2. Department of Orthopaedics and Traumatology, Gaziantep Islam Science And Technology University, Gaziantep, Turkey

Received 16 Oct 2023  
Accepted 18 Jan 2024

#### **Keywords:**

*Echinococcus granulosus*;  
Infraspinatus;  
Surgery;  
Chemotherapy

\*Correspondence Email:  
[oguzkayamd@gmail.com](mailto:oguzkayamd@gmail.com)

#### **Abstract**

Hydatid cyst is an infestation caused by *Echinococcus granulosus*, which is endemic in most countries and most commonly affects the liver and lungs. Isolated muscle involvement is very rare and accounts for 3-5% of all cases. In April 2022, Health Sciences University Elazığ Fethi Sekin City and Research Hospital in Turkey received a referral for a 37-year-old male patient from the physical therapy and rehabilitation outpatient clinic. The patient presented with complaints of chronic pain in his left shoulder and back, which worsened with movement. After the radiological and serological confirmation of diagnosis, the patient underwent wide surgical resection, adjuvant and neoadjuvant anthelmintic chemotherapy. Precise and complete removal of the cyst without infecting the surrounding tissues combined with anthelmintic chemotherapy will not only increase the success of the surgery but will also minimize the possibility of recurrence and distant organ spread. In this study, we aimed to raise awareness by presenting the first reported isolated hydatid cyst in the infraspinatus muscle case from our country, which is extremely rare.



## Introduction

**H**ydatic cyst is one of the most common zoonotic infestations worldwide, mostly caused by *Echinococcus granulosus* in humans. The disease is endemic in India, South America, the Middle East, and Mediterranean countries (1). *E. granulosus* does not normally have humans in its life cycle, and intermediate hosts are animals such as sheep, goats, cattle, and pigs. Parasite eggs, which reach adulthood in the small intestine of dogs, are excreted through the feces. These eggs can infect humans by consuming unwashed and parasite-contaminated raw fruits and vegetables, not washing hands after feeding pets such as cats and dogs. These infective eggs pass into the small intestine, and the embryos released here spread from the small intestine mucosa to the lymphatic and systemic circulation. Due to the capillary filter structure, the organs in which hydatid cysts are most common are the liver (65-75%) and the lung (25-30%) (1).

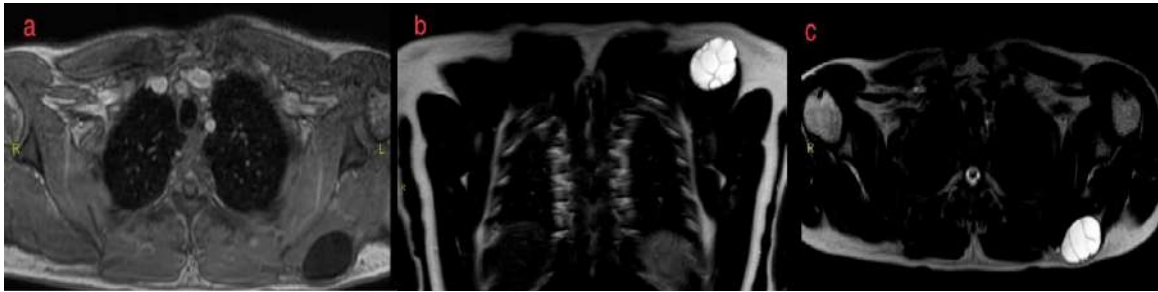
Musculoskeletal hydatid cyst is a rare entity and occurs secondary to spread from a distant organ. Isolated primary muscular (3-5%) hydatidosis is extremely rare (2,3). Cases of intramuscular hydatid cysts on the thigh, shoulder, and cruris have been reported in the literature (4-7). We present a case of an isolated hydatid cyst in the infraspinatus muscle, which was previously reported in 3 cases (7-9).

## Case presentation

A 37-year-old male patient was referred to Health Sciences University Elazığ Fethi Sekin City and Research Hospital in Turkey from the Physical Therapy and Rehabilitation Outpatient Clinic in April 2022. Written informed consent was obtained from the patient. He presented with recurrent left shoulder and

back discomfort that exacerbated with movement. The patient had no history of trauma, previous shoulder surgery, systemic disease, or infection, but lived in a rural area, was engaged in farming. The patient described that he had been in pain for four months and recently felt weakness when turning his shoulder outward and slight swelling in his back. Physical examination revealed weakness in external rotation on the left shoulder of the patient compared to the other extremity. Physical examination revealed a painless, non-fluctuating, rubbery, immobile mass superior to the left scapula that did not cause any discoloration on the skin.

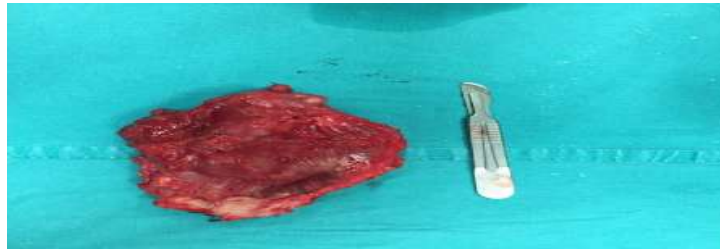
In laboratory evaluation, white blood cell, erythrocyte sedimentation rate (ESR), and C-reactive protein (CRP) values were within normal limits. Eosinophilia was not detected. No space-occupying lesion was observed in the patient's shoulder and chest radiographs. Then, ultrasonography (USG) was performed, and a 5x3 cm anechoic mass with thick walls and cystic structures was detected. After magnetic resonance imaging (MRI), a well circumscribed, 55x34x30 mm cystic lesion with internal mucoid septa was detected in the left infraspinatus muscle (Fig. 1). Serological evaluation with echinococcal indirect hemagglutination (IHA) test yielded positive results. Abdominal and thorax computed tomography (CT) was requested from the patient to exclude liver and lung involvement. No additional organ involvement was detected. Thereupon, wide surgical resection (pericystectomy) was planned for the patient. A written informed consent obtained from the patient. Before surgery, the patient received anthelmintic treatment with 15 mg/kg albendazole divided into two doses for 2 weeks.



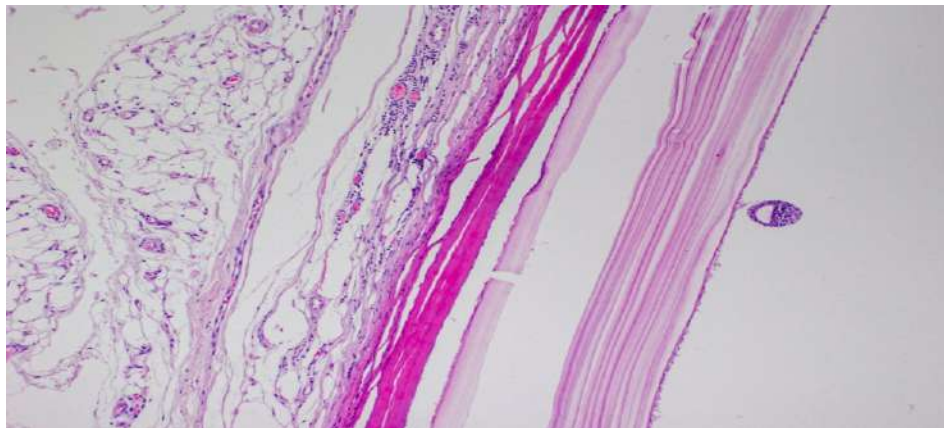
**Fig. 1:** a-c. a. Axial T1-weighted image, b. Coronal T2-weighted image, c. Axial T2-weighted image. The images depict a hydatid cyst located within the infraspinatus muscle

The patient was operated under general anesthesia in the prone position under appropriate sterile and antisepsis conditions. The mass was completely excised en bloc from the surrounding tissues (Fig. 2). After wide surgical resection, the surgical area was washed with 20% saline solution. Pathology preparations showed chronic inflammatory tissue along with protoscolices infecting muscle tissue and germinative membrane (Fig. 3). Adjuvant an-

thelmintic therapy was continued for 2 months in the postoperative period to prevent distant organ spread and local recurrence. Patient was called for an annual control for the first 2 years and every 2 years in the following period. In the follow-ups, the presence of recurrence was evaluated USG and IHA. The patient had no complaints in the 4th year follow-up and no recurrence was detected.



**Fig. 2:** Intraoperative image of the en bloc resected mass with minimum muscle tissue stripping and without damage to the cyst wall.



**Fig. 3:** The Laminar membrane, germinative membrane, and scolex structures of an intramuscular hydatid cyst viewed microscopically (H-E x 100) (Original picture)

## Discussion

Hydatid cysts continue to be an endemic infestation due to the lack of regular public health controls, unauthorized and irregular breeding of small cattle, and the lack of care for stray dogs (4). Muscle tissue contains high blood pressure and lactic acid, which is not suitable for the survival of this parasite (10). In the literature, 3 cases of solitary hydatid cyst in the infraspinatus muscle have been described before (7-9).

Limitation of movement was not the main complaint in any of the previously described cases of solitary hydatid cyst in infraspinatus; only one patient had some limitation in the range of motion in the postoperative period, and this did not pose a problem in the patient's daily life (7-9). However, in our case, unlike the literature, the main complaints were pain, weakness, and limitation in external rotation of the arm. This may be because the mass of the infraspinatus muscle is relatively lower than most muscle groups, and a mass of this size may cause difficulty in performing the normal functions of the muscle. After the surgical excision, our patient did not have any pain and limitation of movement in the first-year follow-up.

Among the serological tests, the IHA test has the highest diagnostic accuracy, with a rate of 83-100% (11). In our case, IHA was used for serological diagnosis and the diagnosis was confirmed with a positive result. Radiologic evaluations alone may not be sufficient for correct diagnosis because pathognomonic findings in liver and lung hydatid cysts may not be detected by USG and CT in cases of intramuscular hydatid cysts. Therefore, in our study, in cases where we suspected a hydatid cyst after USG, together with the anamnesis, we always requested MRI, and the diagnosis was confirmed in this way. In postoperative follow-ups, evaluation was made with USG, as it is inexpensive and easily accessible.

If there is an obstacle to surgical resection, percutaneous drainage followed by washing the surgical area with a scolicedal solution is among the recommended treatment methods (2,12). Even if the mass is completely excised, the remaining scolices may spread distantly or migrate to adjacent muscle compartments, causing secondary infestation. In our case, we completely excised the cyst with a clean surgical margin. In order to inactivate microscopic scolices that may have survived after excision, the potential space formed after excision was washed with 20% saline solution (2,10).

Perhaps the most uncertain and controversial topic in the treatment of muscular hydatid cyst is anthelmintic chemotherapy. There is no definite information about the dose and duration of the treatment, which anthelmintic drug to be used, and neoadjuvant and adjuvant chemotherapy administration. However, studies show that albendazole is the generally accepted anthelmintic agent because it inactivates viable scolices, lowers intracystic pressure, better invades the cyst membrane, and reaches a higher concentration in cyst content (2). In our case, we administered 15 mg/kg albendazole orally for 2 weeks as a neoadjuvant and for 2 months as an adjuvant treatment (13).

## Conclusion

Patients with shoulder and back pain constitute a significant majority of daily outpatient visits. Therefore, if the patient has risk factors for transmission in regions where hydatid cyst is endemic, any soft tissue mass should also be evaluated for hydatid cyst, and hydatid cyst should be excluded. In cases of isolated muscular hydatid cyst, appropriate treatment is wide surgical resection and adjuvant and neoadjuvant chemotherapy with albendazole. Considering the high recurrence rate, a careful intraoperative approach and a delicate surgery without cyst rupture will increase the success rate.

## Acknowledgements

We wish to extend our sincere appreciation to the patient and for their cooperation in voluntarily disclosing the information. No funding was obtained for this study.

## Conflict of Interest

Non- declared.

## References

1. Agudelo Higuaita NI, Brunetti E, McCloskey C. Cystic Echinococcosis. *J Clin Microbiol.* 2016;54(3):518-23.
2. Salamone G, Licari L, Randisi B, Falco N, et al. Uncommon localizations of hydatid cyst. Review of the literature. *G Chir.* 2016;37(4):180-185.
3. Moravvej H, Haghightakhah HR, Abdollahimajd F, Aref S. Primary subcutaneous hydatid cyst of the leg: An unusual location and review of the literature. *Indian J Dermatol Venereol Leprol.* 2016; 82(5):558-62.
4. Sipahioğlu S, Koçarslan S, Zehir S. Primary hydatid cyst in the medial thigh: case report. *Eklemler Hastalıkları Cerrahisi.* 2014; 25(3):168-72.
5. Yilmaz S, Gulcek M, Demirtas Y, Turan S. An unusual cause of mass in the shoulder: A primary hydatid cyst. *Int J Shoulder Surg.* 2014; 8(2):58-60.
6. Seyedsadeghi M, Arabzadeh A, Habibzadeh A. A case of hydatid cyst in biceps femoris. *Int J Surg Case Rep.* 2020; 66:107-109.
7. Erol B, Onay T, Çalışkan E, Okay E. Oncological approach with antihelminthic chemotherapy and wide resection in the treatment of musculoskeletal hydatidosis. A review of 10 cases with mean follow-up of 64 months. *Acta Orthop Belg.* 2015; 81(3):530-7.
8. Gougoulias NE, Varitimidis SE, Bargiotas KA, Dovas TN, Karydakos G, Dailiana ZH. Skeletal muscle hydatid cysts presenting as soft tissue masses. *Hippokratia.* 2010; 14(2):126-30.
9. El-Hammoumi MM, Montasser M, El-Hassane A, Slaoui O, El-Oueriachi F, Kabiri EH. Primary Hydatid Cyst of Infraspinatus Muscle. *Med Cas Rep.* 2016; 2(4):36.
10. Kaya H, Karahan G, Sabah D. Is Hydatid Cyst with Musculoskeletal Involvement a Problem that Causes Morbidity? Long-Term Follow-Up and Functional Results. *Indian J Orthop.* 2021; 17;56(4):680-688.
11. Maleki F, Akhlaghi L, Tabatabaie F. Evaluation of Hydatid Cyst Antigen for Serological Diagnosis. *Med J Islam Repub Iran.* 2023; 14; 87.
12. Agholi M, Heidarian HR, Montaseri Z, Khajeh F. Muscular hydatid cyst in Iran: A case report. *Int J Surg Case Rep.* 2023; 103:107867.
13. Dehkordi AB, Sanei B, Yousefi M, et al. Albendazole and Treatment of Hydatid Cyst: Review of the Literature. *Infect Disord Drug Targets.* 2019;19(2):101-104.