



Tehran University of Medical  
Sciences Publication  
<http://tums.ac.ir>

## Iran J Parasitol

Open access Journal at  
<http://ijpa.tums.ac.ir>



Iranian Society of Parasitology  
<http://isp.tums.ac.ir>

### Case Report

## Isolation of *Schistosoma haematobium* in Bronchoalveolar Lavage in an Immunocompromised Individual: A Case Report

Shailesh Bhanudas Meshram, \*Hiral Gulab Ramnani, Spandana Chaudhury

Department of Respiratory Medicine, Dr D Y Patil Medical College, Hospital & Research Centre  
D Y Patil Vidyapeeth, Pune, India

Received 21 Sep 2023  
Accepted 12 Nov 2023

#### **Keywords:**

Schistosomiasis;  
Bronchoscopy;  
Praziquantel;  
Bronchoalveolar lavage;  
Katayama

\*Correspondence Email:  
[hiralramnani23@gmail.com](mailto:hiralramnani23@gmail.com)

#### **Abstract**

Schistosomiasis is a parasitic disease caused by trematodes (body flukes), affecting millions worldwide. However, its pulmonary manifestations are rare. We report a rare case of a 51-year-old People Living with HIV male, managed in a tertiary care hospital in west India in May 2023, vegetable vendor who was admitted with complaints of dysphagia, odynophagia, fever and chest pain for 3 days, cough and breathlessness for 1 month. Chest x-ray and CT scan were suggestive of hypodense fluid collection with rim enhancement along right lateral and posterior aspect of thoracic esophagus. All routine investigations and urine cultures were sent, which turned to be inconclusive. Upper Gastrointestinal scopy was suggestive of pangastritis. Fiberoptic bronchoscopy was done with no structural abnormality or endobronchial mass. Bronchoalveolar lavage from right lower lobe was sent for CBNAAT, Gram and Ziehl Nelson staining and cultures, acid fast bacilli cultures and cytology which revealed parasitic infection with *Schistosoma haematobium*. The patient was treated with tablet praziquantel P/O 2400 mg in divided doses for 1 day followed up after two weeks when he experienced reduced symptoms. Sputum examination was repeated showed *Schistosoma* on wet mount and hence a repeat dose of tablet praziquantel 3000 mg in divided doses was given and was advised to follow up 2 weeks later, which showed resolution of right lower zone opacities.



## Introduction

Schistosomiasis is also known as bilharziasis (1). Schistosomiasis is endemic in the tropics as recognized by the WHO and it affects 200 million people worldwide, with its epicenter being Africa (2,3). Three main species of schistosomes are *S. mansoni*, *S. haematobium* and *S. japonicum*. Lungs are not end organ for the involvement in schistosomiasis. They can be affected at any stage. Adult trematodes are found in visceral plexus (*S. haematobium*) while others in mesenteric veins (*S. japonicum*, *S. mansoni*). Their eggs are excreted in urine or faeces respectively. In fresh water, they form miracidia which hatch and infect snails (4,5). Miracidium removes ciliated plates, develops into a mother sporocyst, which reproduces daughter sporocysts (4,6). Daughter sporocysts give rise to either cercaria or more daughter sporocysts (3). Snails can shed hundreds of cercariae per day approximately 200 for *S. haematobium* (7).

Man gets infected by its cercariae present in fresh water (7,8). The life cycle occurs in two hosts: snail and mammals. Cercariae enter through the skin and enter the circulation passing through the heart, lungs, liver to reach venous plexus. These worms mature and mate. Adult worms of *S. haematobium* exists in the bladder (8,9), ureters and rectal venules. Acute schistosomiasis presents as Katayama syndrome can also have chronic manifestations. Incubation period of Katayama syndrome is 14 to 84 days. Katayama syndrome presents with fever, headache, myalgia, rash, cough and breathlessness (10). *S. haematobium* may manifest as chronic disease with dysuria and hematuria. It can cause bowel wall ulceration, fibrosis, hyperplasia, polyposis, and portal hypertension (11). Initial manifestation occurs in immunocompromised host as acute disease. Eggs that are not passed in intestine or bladder are the main cause for chronic granulomatous reaction and fibrosis. This may cause hepatosplenomegaly, portal hypertension and

may enter into pulmonary vessels, which in long run cause obliterative arteritis leading to pulmonary hypertension.

In our case, the patient had negative urine cultures and ultrasound abdomen/pelvis was within normal limits and generally these patients are prone to pulmonary hypertension but our patient had a normal 2D echo report.

In non-endemic countries, returned non-immune travelers may present with acute schistosomiasis while migrants from endemic countries may present with chronic disease. Symptoms generally occur 4 to 6 weeks after infection. In acute cases, serology is negative with no eggs detectable and diagnosis is difficult to be made. In heavy infections, the migratory phase in lung may produce pneumonitis resembling hookworm infestation (Loeffler-like syndrome) (12).

Radiological features like nodular or reticulonodular ill-defined lesions may be seen on chest x-ray in acute cases (13). Chest x-rays may show features resembling granulomatous disease or tuberculosis (14,15). In chronic cases, interstitial or granulomatous changes may be seen in pulmonary vasculature. CT thorax may show nodular opacities and ground glass opacities (16). Blood investigations may show peripheral eosinophilia in 65% of the patients (17). Schistosomiasis in bronchoalveolar lavage may be seen after approximately 6 weeks after infection. IgG antibodies to eggs can also be found after 6-12 weeks by ELISA and may remain positive for several years, so not useful for prognosis and monitoring of the disease.

The treatment of choice for schistosomiasis is praziquantel. In acute cases, (Katayama fever) praziquantel is administered under steroid cover. A second course of praziquantel may need to be given 3 to 6 months later to eradicate any schistosomes that may have survived the first course of treatment. Treatment is less effective in chronic disease (18).

Here we report a case of *S. haematobium* in bronchoalveolar lavage in an immunocompromised individual from India.

### Case Report

A 51-year vegetable vendor with HIV positive status on following antiretroviral drugs T. tenofovir 300 mg + T. lamivudine 300 mg + T. dolutegravir 50 mg regimen since 2020 and was managed in a tertiary care hospital in west India in May 2023 with complaints of dysphagia, odynophagia, fever and chest pain for 3 days, cough and breathlessness for 1 month. He is also a treated case of Hansen's disease in August 2022.

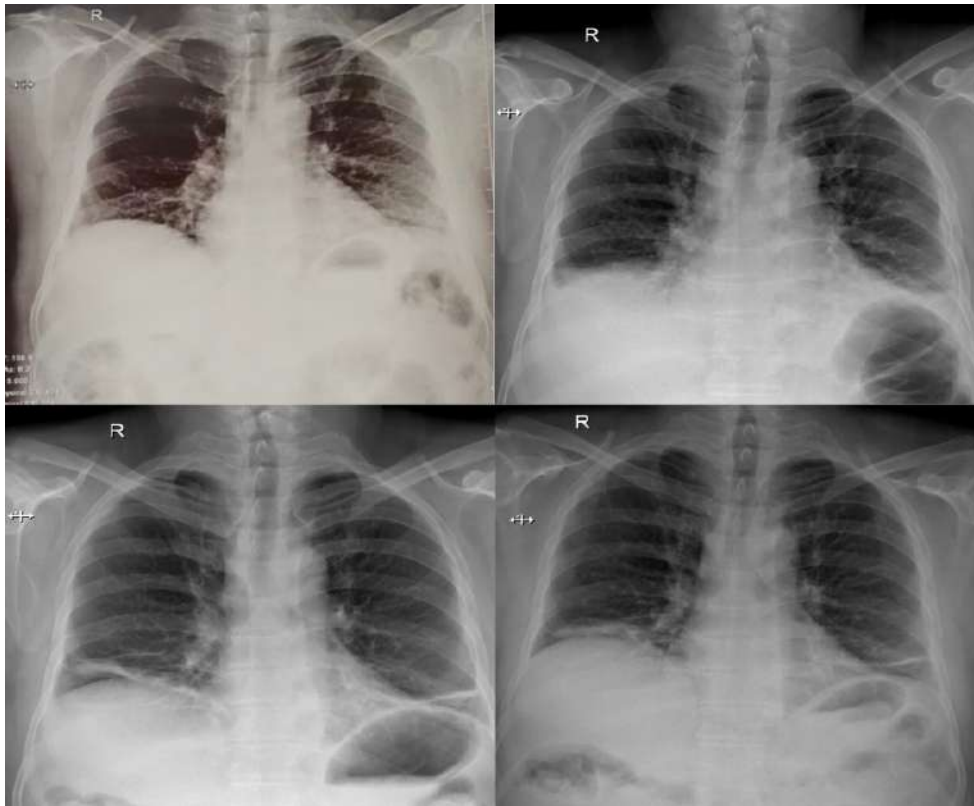
Cough since 1 month with whitish expectorant with history of 2 episodes of blood tinged sputum in 2020. Breathlessness since 1 month, MMRC grade I. He denied any recent travel

history. Grade 2 clubbing of fingers with hyperkeratotic patches in bilateral lower limbs were present. All routine blood investigations and cultures were negative.

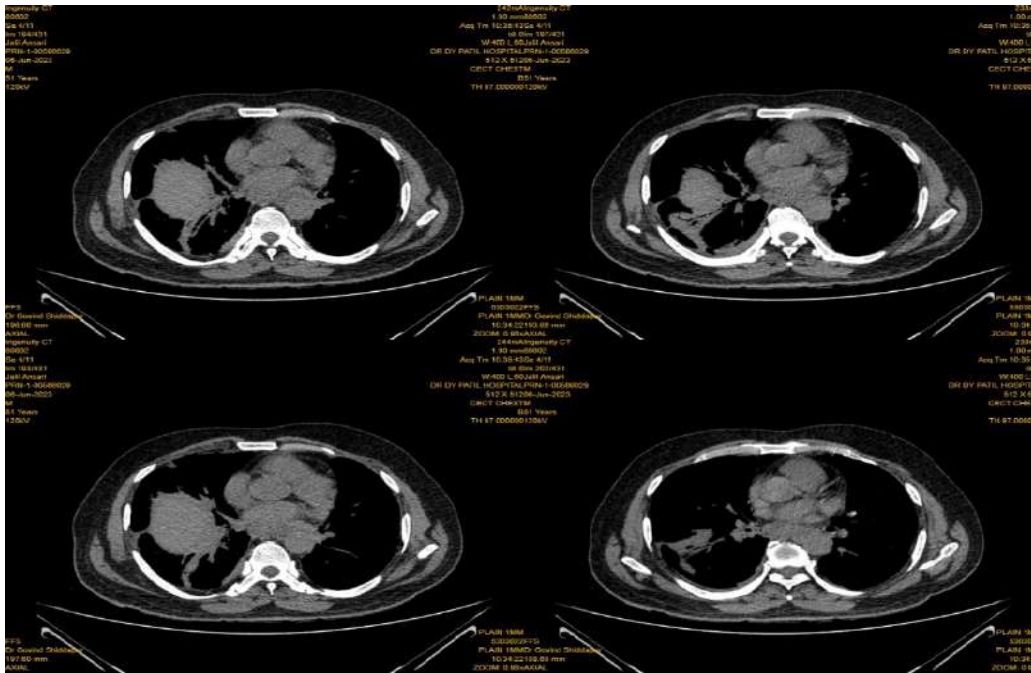
Serial chest x-rays were done since admission and followed up showing resolution after treatment (Fig. 1).

HRCT done was suggestive of bilateral effusion with atelectasis followed by CECT thorax suggestive of right lower zone consolidation with opportunistic infection (Figs. 2,3).

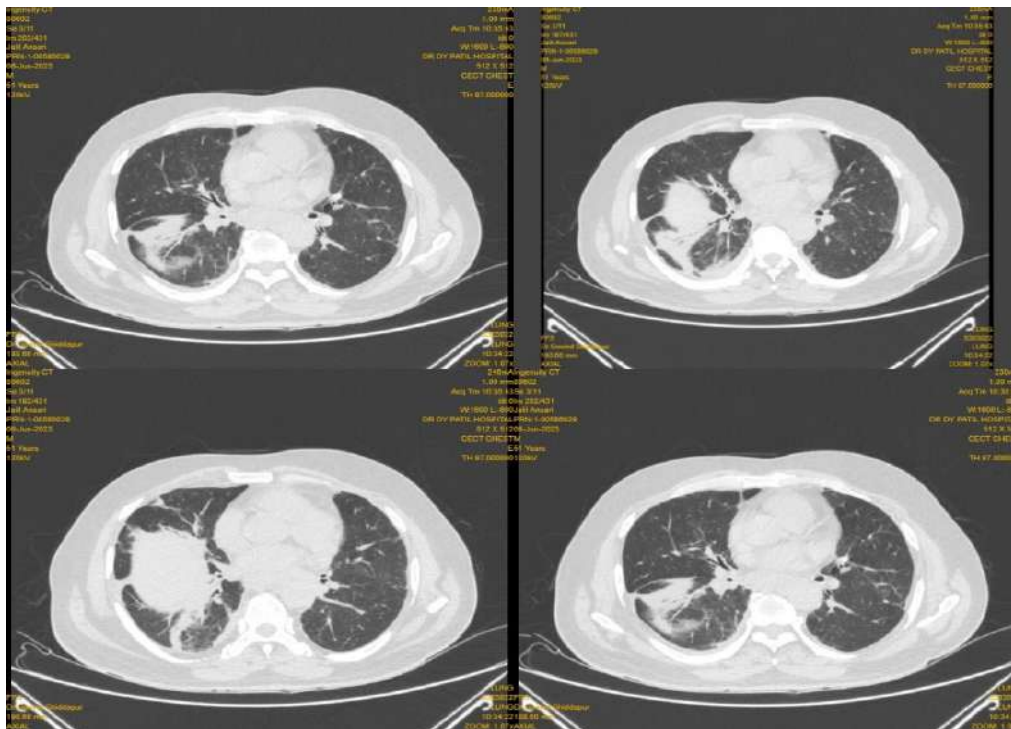
The authors certify that we have taken all appropriate patient consent forms. In the form, the patient has given his consent for his images and other clinical, radiological information to be reported in the journal. The patient has been assured that his name and initial will not be published. Efforts will be made to conceal his identity, but anonymity cannot be guaranteed.



**Fig. 1:** Chest x-ray showed inhomogeneous opacity with fiberoptic band in bilateral lower lobes with left Costophrenic angle blunting. Last x-ray shows resolution



**Fig. 2:** HRCT thorax showed mild bilateral pleural effusion (Right>Left) with few areas of subsegmental atelectasis, circumferential wall thickening of esophagus extending for approximately 15cm from mid thoracic region to gastroesophageal junction



**Fig. 3:** CECT thorax showed consolidation in right lower zone with opportunistic infection, mild left sided pleural effusion with pleural thickening

2D echo was done which turned out to be normal with no pulmonary hypertension. Upper gastrointestinal scopy showed pangastritis, treated with *Helicobacter pylori* kit.

Fiberoptic bronchoscopy done showed no structural abnormality or endobronchial mass. Bronchoalveolar lavage from posterobasal segment of right lower lobe was sent for investigation, which was suggestive of parasitic infection *Schistosoma haematobium*. The patient was treated with tablet praziquantel P/O 2400 mg in divided doses for 1 day.

On follow up, 6-minute walk test, showed no significant desaturation with a total distance covered being 310 meters. In addition, symptoms reduced but persisted, a sputum culture was sent for wet mount suggested schistosomiasis, and a repeat dose of tablet praziquantel 3000 mg in divided doses for 1 day along with glucocorticoid (Tablet wysolone 30 mg twice daily) for 3 days was administered (17).

## Discussion

Schistosomiasis is a parasitic disease caused by trematodes (body flukes), affecting millions worldwide. However, its pulmonary manifestations are rare. Man is infected by its cercariae present in fresh water. The life cycle occurs in two hosts: snail and mammals. Parasitic infections of the lung occur worldwide among both immune compromised and immunocompetent. The clinical presentation and radiographic features of many of these may mimic tuberculosis and malignancy (12). If identified early, most parasitic infections are medically or surgically curable.

## Conclusion

Pulmonary schistosomiasis is a rare disease, which if detected early on radiograph and confirmed in bronchoalveolar lavage or sputum samples and treated aggressively with praziquantel and steroids has minimal residual

effect with no activity limitation in an individual.

## Conflict of Interest

The authors declare that there is no conflict of interests.

## Abbreviations

CT-Computed Tomography, CECT- Contrast Enhanced Computed Tomography, HRCT-High Resolution Computed Tomography, BD- twice daily, 2D- 2-Dimensional, IgG-Immunoglobulin G, PLHIV- People Living with HIV, ELISA- Enzyme Linked Immunosorbent Assay, P/O- Per oral, CBNAAT- Cartridge Based Nucleic Acid Amplification Test

## References

1. Chistulo L, Loverde P, Engels D. Disease watch: schistosomiasis. *Nat Rev Microbiol*, 2004;2:12-3.
2. Van der Werf MJ, de Vlas SJ, Brooker S, et al. Quantification of clinical morbidity associated with schistosome infection in sub-Saharan Africa. *Acta Trop*. 2003;86(2-3):125-39.
3. Schwartz E. Lung involvement in schistosomiasis. *Lung biology in health and disease*. 2006; 211:351.
4. Alemu M, Zigta E, Derbie A. Under diagnosis of intestinal schistosomiasis in a referral hospital, North Ethiopia. *BMC Res Notes*. 2018;11(1):245.
5. Mohamed I, Kinung'hi S, Mwinzi PNM, et al. Diet and hygiene practices influence morbidity in schoolchildren living in schistosomiasis endemic areas along Lake Victoria in Kenya and Tanzania-A cross-sectional study. *PLoS Negl Trop Dis*. 2018;12(3):e0006373.
6. Wei Y, Huang N, Chen S, et al. The diagnosis and treatment introspection of the first imported case of atypical cerebral

- schistosomiasis in Guangzhou city. PLoS Negl Trop Dis. 2018 15;12(3):e0006171.
7. Braun L, Grimes JET, Templeton MR. The effectiveness of water treatment processes against schistosome cercariae: A systematic review. PLoS Negl Trop Dis. 2018;12(4):e0006364.
  8. CDC - DPDx - Schistosomiasis Infection. 2019.14.  
<https://www.cdc.gov/dpdx/schistosomiasis/index.html>
  9. Abe EM, Guan W, Guo YH, et al. Differentiating snail intermediate hosts of *Schistosoma* spp. using molecular approaches: fundamental to successful integrated control mechanism in Africa. Infect Dis Poverty. 2018;7(1):29.
  10. Ross AG, Vickers D, Olds GR, Shah SM, McManus DP. Katayama syndrome. Lancet Infect Dis. 2007;7(3):218-24.
  11. Barbosa MM, Lamounier JA, Oliveira EC, et al. Pulmonary hypertension in Schistosomiasis *mansoni*. Trans R Soc Trop Med Hyg. 1996;90(6):663-5.
  12. Kunst H, Mack D, Kon OM, Banerjee AK, Chiodini P, Grant A. Parasitic infections of the lung: a guide for the respiratory physician. Thorax. 2011;66(6):528-36.
  13. Schwartz E, Rozenman J, Perelman M. Pulmonary manifestations of early schistosome infection among nonimmune travelers. Am J Med. 2000;109(9):718-22.
  14. Schaberg T, Rahn W, Racz P, Lode H. Pulmonary schistosomiasis resembling acute pulmonary tuberculosis. Eur Respir J. 1991;4(8):1023-6.
  15. Lambertucci JR, Silva LC, de Queiroz LC. Pulmonary nodules and pleural effusion in the acute phase of schistosomiasis *mansoni*. Rev Soc Bras Med Trop. 2007;40(3):374-5.
  16. Waldman AD, Day JH, Shaw P, Bryceson AD. Subacute pulmonary granulomatous schistosomiasis: high resolution CT appearances--another cause of the halo sign. Br J Radiol. 2001;74(887):1052-5.
  17. Day JH, Grant AD, Doherty JF, Chiodini PL, Wright SG. Schistosomiasis in travelers returning from sub-Saharan Africa. BMJ. 1996;313(7052):268-9.
  18. Jauréguiberry S, Paris L, Caumes E. Acute schistosomiasis, a diagnostic and therapeutic challenge. Clin Microbiol Infect. 2010;16(3):225-31.