



Tehran University of Medical
Sciences Publication
<http://tums.ac.ir>

Iran J Parasitol

Open access Journal at
<http://ijpa.tums.ac.ir>



Iranian Society of Parasitology
<http://isp.tums.ac.ir>

Original Article

First Record of *Spirometra erinaceieuropaei* spargana Infection in Amphibians of South Asia: A Causative Agent of Surficial Abnormalities

Praneeth Silva¹, Tharanga Dasanayake², Dulan Jayasekara², Chathuranga Dharmarathne³,
*Dharshani Mahaulpatha²

1. Department of Oral Biology, Rady Faculty of Health Sciences, University of Manitoba, Winnipeg, Canada
2. Department of Zoology, Faculty of Applied Sciences, University of Sri Jayewardenepura, Nugegoda, Sri Lanka
3. Department of Biological Sciences and Engineering, Macquarie University, Sydney, Australia

Received 11 Feb 2022

Accepted 22 May 2022

Keywords:

HPNP;
Spargana;
Sparganosis;
Spirometra erinaceieuropaei

***Correspondence**

Email:

mahaulpatha@sjp.ac.lk

Abstract

Background: Sparganosis is a zoonotic disease caused by Plerocercoid larvae (spargana) of the genus *Spirometra*. We aimed to provide molecular evidence for the infection of amphibians with *Spirometra* sp. in the inside and outside of Horton Plains National Park (HPNP), Sri Lanka.

Methods: The prevalence of sparganum infection in wild frogs (*Truga eques* and *Minivarya agricola*) was investigated in the inside and outside of HPNP from June 2019 to April 2021. A total of 1,434 Amphibians samples were surveyed to examine the spargana infection from the study site. To identify the species identity of the collected spargana, a portion of the mitochondrial cytochrome c oxidase subunit 1 (cox1) gene and nuclear 18S rRNA gene were amplified, sequenced, and analyzed.

Results: A total of 539 infected amphibians (*T. eques* and *M. agricola*) samples were examined to survey from the study area. Spargana were detected in all dissected specimens belonging to the species *Spirometra erinaceieuropaei* that were genetically confirmed using the evolutionary conserved nuclear 18S rRNA gene and then compared to the GenBank deposit, indicating that *S. erinaceieuropaei* is the primary causal agent of sparganosis both inside and outside the HPNP.

Conclusion: Our finding is the first genetically confirmed record of *S. erinaceieuropaei* in amphibians in South Asia. However, further studies are needed to investigate the prevalence of spargana infection in amphibians all over the island.



Copyright © 2022 Silva et al. Published by Tehran University of Medical Sciences.

This work is licensed under a Creative Commons Attribution-NonCommercial 4.0 International license.

(<https://creativecommons.org/licenses/by-nc/4.0/>). Non-commercial uses of the work are permitted, provided the original work is properly cited

Introduction

Sparganosis is a neglected parasitic infection and, emerging zoonotic disease in Asia, Europe and North America (1-3). Hence, the Plerocercoid larvae (sparganum /pl. spargana) of various Diphylobothroid tapeworms cause sparganosis, a food-and water-borne illness in humans and animals. The species of genus *Spirometra* include *S. erinacei*, *S. ranarum*, *S. mansonioides* and *Sparganum proliferum* (4-6). *S. mansonioides* and *S. erinacei* are recorded as the most important causative agents, which are distributed in North American and Asian countries, respectively (7).

The tapeworm *S. erinacei* is the most important species in the genus *Spirometra* tapeworms (8). The life cycle of these parasites requires two different intermediate hosts; the parasite's first intermediate hosts are copepods (*Cyclops* sp.) planktonic crustaceans in which proceroids (the first larval stage) develop, and the second intermediate or paratenic hosts are vertebrates, such as amphibians, reptiles, birds,

or mammals (including humans) (9,10). Intermediate hosts are already considered important vectors for parasite transmission in Asia (10-12). Moreover, the sites spargana (plerocercoid larvae) migrate in the subcutaneous tissues and sometimes invade the abdominal cavity, skin and soft tissues, muscles, visceral organs, and the central nervous system (13-15). Infected amphibians are more vulnerable to parasitic infection, which causes amphibian abnormalities caused by trematode, cestode, and nematode parasites (16-19). However, cestode parasites cause parasitic infection, which leads to amphibian abnormalities forming surficial abnormalities (infectious diseases, cysts, and wounds), skeletal abnormalities, and eye abnormalities (20-21).

The current study was conducted in the HPNP, as shown in Fig. 1. Only one study has been recorded on this site concerning amphibian abnormalities and threats in pristine ecosystems in Sri Lanka, and these abnormalities have been mentioned by (22).

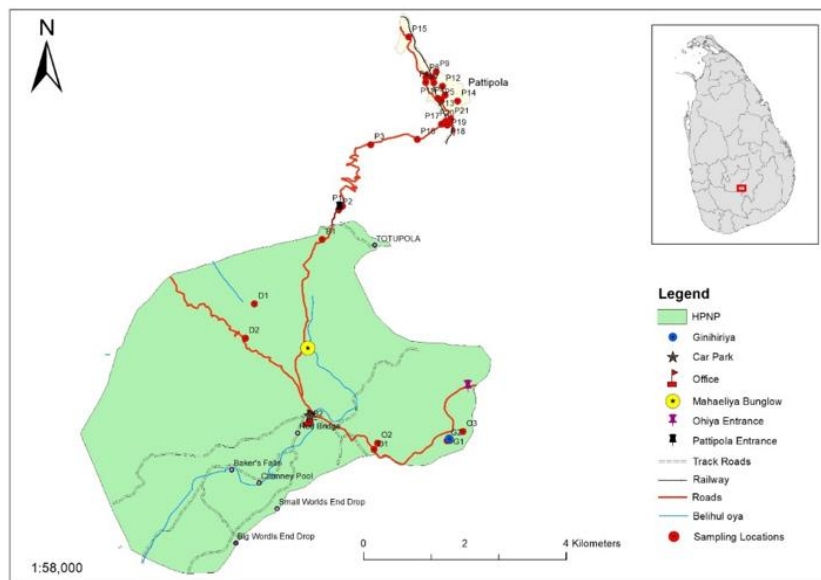


Fig. 1: Locations of sampling sites within and outside the HPNP

The aim of the present study was to conduct a survey of amphibians as hosts of *Spirometra* sp. and to provide molecular evidences of spargana collected from amphibians. These findings may aid in identifying the origins of infection, which accounts for major implications for the prevention and management of sparganosis in the research region. Moreover, we designed our analysis based on the coding gene of mitochondrial cytochrome c oxidase 1 gene (*cox1*) and nuclei 18SrRNA of spargana isolated from infected amphibians, HPNP, Sri Lanka.

Materials and Methods

Ethical approval

This study was conducted with the permission from the Department of Wildlife and Conservation, Sri Lanka (permit no WL/2/3/6/19) and Department of Forest Conservation (R&E/RES/NFSRCM/2019-03).

Parasites samples

Live specimens of *T. eques* (Hour grass-tree frog) and *M. agricola* (common Indian cricket frog) were collected from the inside and outside of HPNP, respectively, totaling 1320 and 114. According to the procedures, the naked eye was used to examine the skeletal muscles and skins for the presence of spargana according to the methods of (23). Only fifteen samples were taken from the total number of infected amphibians and dissected to determine the parasitized helminths.

Euthanizing and preserving of infected amphibians

Infected frogs were euthanized by immersing them one by one in a 10% buffered formalin solution (24). Then it was followed by the preservation of specimens in 70% alcohol for 6 hours for full necropsies to confirm and characterize suspected parasitism.

Dissection of preserved frogs

Parasitized larval stages and cysts extracted from muscles and subcutaneous tissues, were isolated using small scissors and forceps and placed in a Petri dish containing physiological 0.85% saline (25) to observe their viability and movement. The number of parasites collected from each infected frog was counted to estimate the intensity of infection. Then, the extracted parasites and their life stage were examined microscopically to identify them up to genus level according to morphological features and site of predilection (26) and after microscope analysis, they were immediately fixed in 70% ethanol and stored at -20°C until the extraction of genomic DNA.

Molecular Procedure

DNA extraction

Total genomic DNA was extracted from individual plerocercoid samples using the extraction QIAamp-DNA Mini kit with the tissue protocol ((NucleoSpin® Tissue, Macherey-Nagel, Germany)) following the manufacturer's protocol. The samples were incubated with ATL buffer and proteinase K for 1 h. (completely digested with lysis buffer/proteinase K for 2–3 h at 56°C).

Amplification

The partial two nuclei 18SrRNA genes were amplified using the forward primer 18S9modF (5'-GATCCTGCCAGTAGTCATATGCT*IG-3') and the reverse primer 18S637modR (5'-TACGCTWYTGGAGCTGGAGTTACCG-3'). The partial *cox1* region was amplified using the forward primer Dice1F (5'-AT-TAACCCCTCACTAAATT-WCNTTRGATCATAAG-3') and the reverse primer Dice11R (5'-TAATACGACTCAC-TATAGCWGWACHAAATTTTHCGATC-3') (11).

PCRs were 25 μL in volume and typically contained: 3.5 mM MgCl_2 , 0.5 μM each primer, 0.2 mM dNTPs, 0.6 U Platinum Taq polymerase (Invitrogen) in $1\times$ PCR buffer. Thermocycling conditions were as follows:

94 °C for 2 min; 3 cycles of 94 °C for 40 sec, 51 °C for 40 sec, 72 °C for 1 min; 5 ‘touch-down’ cycles of 94 °C for 40 sec, 50 °C to 46 °C for 40 sec (dropping 1 °C per cycle), 72 °C for 1 min; 35 cycles of 94 °C for 40 sec, 45 °C for 40 sec, 72 °C for 1 min; and a final extension at 72 °C for 5 min. For each PCR experiment, a negative (no DNA) and an amplicon were separated by 1% agarose gel-electrophoresis (11).

Sequences of the nuclei and mitochondrial genes were separately aligned with the reference sequences in the GenBank using the computer program Clustal W 2.0 and adjusted manually. The DNA sequences obtained herein were compared (using the algorithm BLAST-N) with known sequences available in

the National Center for Biotechnology Information (NCBI) database by BLAST analysis (<https://blast.ncbi.nlm.nih.gov>). Our current material's 18SrRNA and cox1 sequences have been uploaded to the GenBank database (<https://www.ncbi.nlm.nih.gov/genbank/>).

Results

Only 539 amphibians were infected out of 1,434 amphibians examined both inside and outside the HPNP. The cyst and larval stages were found in 37.5% of the amphibians (539/1434). Infection prevalence varied from 2.1% to 42.7% in Table 1.

Table 1: Prevalence and host samples from the inside and outside of HPNP, Sri Lanka in 2019

| <i>Host species</i> | <i>Sources of samples</i> | <i>Number of samples</i> | <i>Infected host samples</i> | <i>Types of infection</i> | <i>Prevalence (%)</i> |
|---------------------|---------------------------|--------------------------|------------------------------|---------------------------|-----------------------|
| <i>T. eques</i> | Inside the HPNP | 250 | 84 | Cyst | 33.6 |
| <i>T. eques</i> | Ambewela | 456 | 195 | Cyst | 42.7 |
| <i>T. eques</i> | Pattipola | 614 | 256 | Cyst | 41.6 |
| <i>M. Agricola</i> | Boralanda | 67 | 3 | Larval stage | 4.4 |
| <i>M. Agricola</i> | Ohiya | 47 | 1 | Larval stage | 2.1 |
| Total | | 1434 | 539 | | 37.5 |

*Locations outside HPNP was represented from Ambewela, Pattipola, Boralanda, Ohiya

Molecular analysis for cysts of infected amphibians

Encysted parasites of *T. eques* were found as cysts, only few infections were recorded at the muscles of sampled amphibians, which are associated with backbones. Mostly parasitized around the muscles attached to the metacarpals and phalanges of hind limb bones. Cysts are cream-white in colour and spherical shaped. Length and Diameter of cysts ranged between 0.1mm – 8.00 mm and 0.05 mm – 4.00 mm respectively, as shown in Fig. 2. The analyzed 18S rRNA and cox1 gene fragment of parasitic cysts isolated from frog skeletal tissues showed 99% -100% identity with the

GenBank-deposited *S. erinaceieuropaei*. from GenBank. Parasites which were found in *M. agricola* species mostly parasitized muscles, especially muscles of the hind limbs. This infection appeared as cysts when examining superficially but parasites were precisely detected when the infected frogs were skinned and dissected as creamy-white masses. The length of parasites ranged from 1.00 cm- 10.00 cm, as shown in Fig.3. The analyzed 18S rRNA and cox 1 gene fragments of parasitic cysts isolated from frog skeletal tissues showed respectively 98% -99% and 88%- 94% identity with the GenBank-deposited *S. erinaceieuropaei*.



Fig. 2: Parasitization sites in *T. eques* frogs. A-F: Parasitization in skeletal muscles in backbone and thigh region of frogs. C, D: Cysts attached to the Sartorius, gracilis major and gracilis minor muscles. E- Cysts bound to the metacarpals and phalanges of hind limb bones. F- Extracted cysts from the musculature of infected frogs




Fig. 3: Parasitisation sites in *M. agricola* frogs. A-C: Parasitisation in skeletal muscles in the thigh region of frogs. A- Cotton like parasitic worm. B, C- Curled up parasite at the dorsal muscle

Discussion

Premature stages of *T. eques* to parasite infections were prominent both inside and outside Horton Plains National Park, showing the great vulnerability of pre-mature stages of *T. eques* to parasitic infections as a widespread phenomenon (22). *T. eques* was infected with encysts, which did not lead to the identification of parasitic infection. Therefore, the present study is the first genetically confirmed report of *S. erinaceieuropaei* infection in amphibians (*T. eques* and *M. agricola*) in South Asia. Most of the cysts were observed to emerge within the musculature around the limb structures of the amphibians.

Therefore, these cysts could be due to attack by cestoda as they are generally found above the skeletal muscles around the limb structures. Because *S. erinaceieuropaei* cysts form in the deeper layers of the epidermis, they could have been caused by parasitic infections. *Spirometra* sp. plerocercoids are difficult to identify morphologically. As a result, molecular techniques are the most encouraging affirmation of their systematic classification (9, 27, 28). A group of morphologically similar parasites was identified using the molecular taxonomy method based on suitable markers, which is well documented. Previous studies have used these markers, such as *cox1*, for the identification of *S. erinaceieuropaei* (5, 29-33). Hence, due to the identification of the spargana samples as *S. erinaceieuropaei*, the phylogenetic relationship of tapeworms within the Diphylobothriidae family, based on partial *cox1* and 18S rRNA sequences unambiguously separated the genus *Spirometra* from *Diphylobothrium*. In order to elucidate the genetic diversity of *S. erinaceieuropaei* in Sri Lanka, a further investigation with a greater number of cyst-infected frog samples from diverse locations is required.

Conclusion

The present study indicated all spargana specimens of amphibians (*T. eques* and *M. agricola*) which were dissected in the inside and outside of HPNP, Central Province, Sri Lanka were confirmed as *S. erinaceieuropaei* with 37.5% (537/1434) prevalence rate. Future research should investigate especially the role of *S. erinaceieuropaei* infection, along with the broader impact of *S. erinaceieuropaei* as a primary pathogen on amphibian's populations. This investigation consequently shown which spargana is the major causative agent of cyst abnormalities in amphibians. The findings should be complemented by a discussion of the benefits and limitations of the surveillance strategy in order to estimate the disease's relevance to amphibian populations in Sri Lanka.

Acknowledgements

We highly appreciate the support received from the staff of Horton Plains National Park and "Department of Wildlife Conservation", for granting permission (Permit No: WL/3/2/04/18) to conduct this research.

Conflict of interest

The authors declare that they have no conflict of interest.

References

1. Joyeux C, Baer JG. Sur quelques larves de Bothriocephales. Bull Soc Pathol Exot Paris. 1927;20:921-937.
2. Reeves MK, Dolph CL, Zimmer H, et al. Road proximity increases risk of skeletal abnormalities in wood frogs from National Wildlife Refuges in Alaska. Environ Health Perspect. 2008;116(8):1009-1014.
3. Sahoo N, Sahoo S, Mohanty B, et al. Molecular identification of *Spirometra erinaceieuropaei* infec-

- tion in a dog with its successful treatment. J Entomol Zool. 2018;6(4):1487-1489.
4. Gray ML, Rogers F, Little S, et al. Sparganosis in feral hogs (*Sus scrofa*) from Florida. J Am Vet Med Assoc. 1999;215: 204-8.
 5. Zhu X, Beveridge I, Berger L, et al. Single strand conformation polymorphism-based analysis reveals genetic variation within *Spirometra erinacei* (Cestoda: Pseudophyllidea) from Australia. Mol Cell Probes. 2002;16(2):159-16.
 6. Kolodziej-Sobocińska M, Miniuk M, Ruczyńska I, et al. Sparganosis in wild boar (*Sus scrofa*) – implications for veterinarians, hunters, and consumers. Vet Parasitol. 2016;227:115-117.
 7. Anantaphruti MT, Nawa Y, Vanvanitchai Y. Human sparganosis in Thailand: an overview. Acta Trop. 2011;118(3):171-176.
 8. Mueller JF. The biology of *Spirometra*. J Parasitol. 1974;60(1): 3-14.
 9. Wongkulab P, Sukontason K, Chaiwarith R. Sparganosis: a brief review. J Infect Dis Antimicrob Agents. 2011;28:77-80.
 10. Hong Q, Feng JP, Liu HJ, et al. Prevalence of *Spirometra mansoni* in dogs, cats, and frogs and its medical relevance in Guangzhou, China. Int J Infect Dis. 2016; 53:41-45.
 11. Silva GKVPT, Mahaulpatha WAD, de Silva A. Amphibian abnormalities and threats in pristine ecosystems in Sri Lanka. J Threat Taxa. 2019;11(15):15004-15014.
 12. Nakao M, Sako Y, Yokoyama N, et al. Mitochondrial genetic code in cestodes. Mol Biochem Parasitol. 2000;111(2):415-424.
 13. Nelli S, Felix D, Marine A. Seven new species of helminths for reptiles from Armenia. Acta Parasitol. 2014; 59(3):442-447.
 14. Cui J, Li N, Wang ZQ, et al. Serodiagnosis of experimental sparganum infections of mice and human sparganosis by ELISA using ES antigens of *Spirometra mansoni* spargana. Parasitol Res. 2011;108(6):1551-1556.
 15. Linder G. Multiple stressor effects in relation to declining amphibian populations. J ASTM Int. 2003;1443:3-262
 16. Blaustein AR, Johnson PT. The complexity of deformed amphibians. Front Ecol Environ. 2003;1(2):87-94.
 17. Ankley GT, Degitz SJ, Diamond SA, et al. Assessment of environmental stressors potentially responsible for malformations in North American anuran amphibians. Ecotoxicol Environ Saf. 2004;58(1):7-16.
 18. Imasuen AA, Ozemoka HJ, Aisien MS. Anurans as intermediate and paratenic hosts of helminth infections in the rainforest and derived savanna biotopes of southern Nigeria. Int J Zool. 2012;5(3):1-7.
 19. Liu W, Zhao GH, Tan MY, et al. Survey of *Spirometra erinacei* spargana infection in the frog *Rana nigromaculata* of the Hunan Province of China. Vet Parasitol. 2010;173:152-6.
 20. Lescano AG, Zunt J. Other cestodes: *sparganosis*, *coenurosis* and *Taenia crassiceps* cysticercosis. Handb Clin Neurol. 2013;1(114):335-45.
 21. Ooi HK, Chang SL, Huang CC, et al. Survey of *Spirometra erinacei* in frogs in Taiwan and its experimental infection in cats. J Helminthol. 2000;74(2):173-6.
 22. Scholz T, Kuchta R, Brabec J. Broad tapeworms (Diphyllobothriidae), parasites of wildlife and humans: Recent progress and future challenges. Int J Parasitol Parasites Wildl. 2019;9:359-369.
 23. Okamoto M, Iseto C, Shibahara T, et al. Intra-specific variation of *Spirometra erinacei* and phylogenetic relationship between *Spirometra* and *Diphyllobothrium* inferred from mitochondrial CO1 gene sequences. Parasitol Int. 2007;56(3):235-8.
 24. Lunde KB, Johnson PT. A practical guide for the study of malformed amphibians and their causes. J. Herpetol. 2012;46(4):429-441.
 25. Jongthawin J, Intapan PM, Sanpool O, et al. Molecular evidence of *Spirometra erinacei* infection in snakes *Ptyas korros* from Lao PDR and Thailand and Frogs *Hoplobatrachus rugulosus* from Myanmar. Southeast Asian J Trop Med Public Health. 2014;45(6):1271-1278.
 26. Miller DL, Bursey CR, Gray MJ, et al. Metacercariae of *Clinostomum attenuatum* in *Ambystoma tigrinum mavortium*, *Bufo cognatus* and *Spea multiplicata* from west Texas. J Helminthol. 2004;78(4):373-376.
 27. Kondzior E, Tokarska M, Kowalczyk R, et al. The first case of genetically confirmed sparganosis (*Spirometra erinacei*) in European reptiles. Parasitol. Res. 2018;117(11):3659-3662.
 28. Kolodziej-Sobocińska M, Tokarska M, Kowalczyk R. The first report of sparganosis (*Spirometra* sp.) in Eurasian badger (*Meles meles*). Parasitol Int. 2014; 63(2):397-399.

29. Nithiuthai S, Anantaphruti MT, Waikagul J, et al. Waterborne zoonotic helminthiasis. *Vet Parasitol.* 2004;126(1):167–193.
30. Liu W, Liu GH, Li F, et al. Sequence variability in three mitochondrial DNA regions of *Spirometra erinaceieuropaei* spargana of human and animal health significance. *J Helminthol.* 2012;86(3):271-5.
31. Steenkiste Van, Locke N, Castelin S A, et al. New primers for DNA barcoding of digeneans and cestodes (Platyhelminthes). *Mol Ecol Resour.* 2015;15(4) :945-952.
32. Liu Q, Li MW, Wang ZD, et al. Human sparganosis, a neglected food borne zoonosis. *Lancet Infect Dis.* 2015;15(10):1226–1235.
33. Wang F, Zhou L, Gong S, et al. Severe infection of wild-caught snakes with *Spirometra erinaceieuropaei* from food markets in Guangzhou, China involves a risk for zoonotic sparganosis. *J Parasitol.* 2011;97(1):170–171.