

Proficiency of Carboxymethyl cellulose as a Cryoprotectant. Clinical and Histological Evaluation of Cryopreserved Heterogenous Mesenchymal Stem Cell-Exosomal Hydrogel on Critical Size Skin Wounds in Dogs

Mohamed M. Bahr¹, Mohamed S. Amer¹, Khaled Abo-EL-Sooud², Ahmed N. Abdallah³, Gehan G. Shehab³, Omar S. El-Tookhy¹

¹Department of Surgery, Faculty of Veterinary Medicine, Cairo University, Egypt

²Department of Pharmacology, Faculty of Veterinary Medicine, Cairo University, Egypt

³Department of Pathology, Animal Health Research Institute, Cairo, Egypt

Corresponding Author: Mohamed M Bahr, Department of Surgery, Faculty of Veterinary Medicine, Cairo University, Egypt

Tel: +201151237151

Email: Mohamed.moustafa83@yahoo.com

Received: 28, Feb, 2020

Accepted: 15, Sep, 2020

ABSTRACT

Background: Fresh stem cell exosomes are usually obtained and reused in the same individual. It cannot be kept viable for a long period of time regardless of the lengthy preparation time. Freezing is typically used to preserve the viability of perishable materials and increase their lifetime. Regrettably, normal freezing of biomaterials leads to cell damage. Therefore, a cryoprotectant can save the cells from the conventional cryodamage. Sodium carboxymethylcellulose (NA-CMC) is a powdery substance that is used to manufacture bio-safe hydrofilm gels because of its high viscosity, cytocompatibility, and nonallergenic nature.

Materials and Methods: Sterile CMC hydrogel was prepared, part of which was loaded with exosomal solution derived from MSCs. The gel was kept at -20°C for preservation. Two bilateral full-thickness circular skin wounds of 2-cm diameter were created on the back of experimental dogs. The wounds were at least 2.5 cm apart. Treatment started 24 hours after wound creation. Group I received CMC gel solely, whereas group II received frozen CMC exosomal gel. The gel was applied 4 times, a single application per day with 1- day interval.

Results: Clinically, the frozen exosomal gel significantly promoted wound healing with no scarring. Histologically, enhanced dermal fibroblasts and organized collagen deposition were seen in the treated group.

Conclusion: CMC proved to be an efficient cryoprotectant and a suitable vehicle for exosomes. Deep freezing was proven to conserve the viability, extended the preservation, and facilitated the usage of exosomal gel. This technique of preserved cell-free therapy is inexpensive, time-saving, and proficient and seems suitable for treating cutaneous wounds.

Keywords: Critical-size defect; Skin wound; Heterogeneous; Frozen; Exosome; Carboxymethyl cellulose

INTRODUCTION

Exosomes are a type of extracellular vesicles (EVs), which are released from the endosomal compartment or shed from the surface of many cell types. EVs include exosomes, ectosomes, microvesicles, microparticles, apoptotic bodies, and other subsets but the term “exosomes” is the most commonly used word to indicate any type of EV ¹. Exosomes play an important role in cell-cell communication. It behaves as an endocrine and a paracrine mediator that interacts with neighboring cells ². For a long time, these vesicles are considered to be an artifact under the electron microscope, but are now recognized as vesicles of a specific structure that play an important biological cell-cell horizontal transfer of proteins and RNA ³. The exosome effect is similar to their originating mesenchymal stem cells (MSCs) in different experimental models, for example, as inhibitors to apoptosis and stimulators to tissue proliferation ⁴. The problem with fresh exosomal solutions is that they are obtained and reinjected into the individual and they cannot be kept for a long period of time, not to mention the lengthy preparation time. Therefore, it was appropriate to seek a technique to preserve and extend the biological effect of these vesicles. Freezing is a process typically used to preserve perishable materials; lowering the temperature inhibits the enzymatic activity and decreases material decomposition. Sodium carboxymethylcellulose (Na-CMC) is synthesized by the hydration of cellulose with sodium hydroxide and from an alkaline pulp-catalyzed reaction with chloroacetic acid ⁵. CMC-based hydrogel is used primarily because of its high viscosity and nontoxic and nonallergenic properties ⁶. CMC-based hydrogels are cytocompatible considering the in vitro cell viability responses of more than 95% toward human embryonic kidney cells used as the model cell line ⁷. It also has a strong ability to absorb and transport fluids and protect the wound from bacterial exposure of the external environment ⁸.

This study aimed to evaluate the proficiency of CMC as a cryoprotectant and a bio-safe vehicle for heterogeneous exosomes and to establish a base for long-term preservation of EVs.

MATERIALS AND METHODS

The study was approved by the Institutional Animal Care and Use Committee VET-CU-0722019059.

Bone marrow MSC isolation and propagation

One month before the start of the experiment, fresh bone marrow (BM) was aspirated from the iliac crest of apparently healthy dogs under a general anesthesia regimen: premedication with atropine sulfate (0.1 mg/kg) subcutaneous injection, xylazine (1 mg/kg) intramuscular injection, and induction with ketamine (10 mg/kg) intravenous injection. A total of 9 MSCs were isolated from the BM and were incubated at 37°C in 5% CO₂. The media were continuously changed to remove nonspecific cells and to allow MSCs to grow and multiply to form a confluence sheet.

Identification of BM-derived MSCs

Cells were identified as MSCs by their morphology and adherence to the tissue culture flask ¹⁰. Flow cytometric analysis of cultured MSC surface markers was performed using CD105, CD90, and CD73 ¹¹.

Isolation and expansion of canine MSCs-derived EVs

MSCs were cultured in Dulbecco's modified Eagle medium (DMEM) deprived of fetal bovine serum and supplemented with 0.5% of bovine serum albumin (Sigma). Then, ultracentrifugation of the media was performed to collect the exosomes ¹².

Identification of MSCs-derived EVs

Electron microscopy analyses of the collected exosomal solution were performed. Purified images were obtained by secondary electron at a working distance of 15 to 25 mm and an accelerating voltage of 80 KV. The Jeol T300 system was used for digital acquisition and analysis. Cytofluorometric analysis was performed using CD63, CD44, and CD73. Mouse nonimmune isotypic immunoglobulin G was used as a control.

Preparation of CMC gel-loaded MSCs-derived EVs

CMC powder was mixed with DMEM media in a sterile Petri dish to form a gel, which was left for 30 minutes under a UV lamp for sterilization. DMEM medium containing exosomes was added to the

sterilized CMC at a concentration of 22 mg/mL. Each 1 mL of the gel contained exosomes derived from 0.5×10^6 MSCs. The gel was then stored at -20°C for 1 week after processing and then used for treatment.

Induction of skin wound

This study used 3 apparently healthy dogs (2 males and 1 female) weighing 15–20 kg aged 1–2 years. The dogs were obtained from the official animal supplier to the Faculty of Veterinary Medicine, Cairo University, for animals used in research and teaching purposes. The dogs were housed at separate kennels at the Department of Surgery, Anesthesiology and Radiology, Faculty of Veterinary Medicine, Cairo University, given free access to standard food and water. After overnight fasting, the experimental dogs were anesthetized using the general anesthetic regimen: premedication with atropine sulfate (0.1 mg/kg) subcutaneous injection, xylazine (1 mg/kg) intramuscular injection, and induction with ketamine (10 mg/kg) intravenous injection. Under aseptic conditions, 2 bilateral full-thickness circular wounds of 2-cm diameter were created on the back of each dog using a dermal punch^{13,14}. The wounds were at least 2.5 cm apart. The day on which the wounds were created was designated as day 0¹⁵.

Treatment

Topical treatment started 24 hours after wound creation: group I received CMC gel alone, whereas group II received CMC gel-loaded exosomes. The frozen gel was placed at room temperature (RT) for thawing before usage. The gel was applied 4 times, with 1 day interval, single application per day, starting from the 1st to the 7th day after wounding, in the equivalence of 1-mL gel per wound. Wounds were covered with dressing bandages. All animals received a systemic pain killer and a broad-spectrum antibiotic agent for 3 consecutive days. Daily dressing and monitoring of wound healing were performed.

Evaluation

Physical evaluation of the wounds

Wounds were evaluated and photographed for standard healing parameters for 4 weeks. Wound-size reduction was calculated using the following

equation: $\text{wound-size reduction} = (A_i - A_f) / A_i \times 100$ (where A_i is the initial wound area and A_f is the wound area at days 3, 7, 14, 21, and 28 after wounding)¹⁶.

Histological and immunohistochemical evaluation

Samples for histological and immunohistochemical evaluation were taken at the 3rd, 7th, and 14th day after wounding. According to the schedule, dogs were sedated and wound biopsy were harvested¹⁶. Hematoxylin and eosin (H&E) and Masson's trichrome (MTC) staining were used¹⁵. The reaction toward CD31 and alpha smooth muscle actin (α -SMA) immunofluorescence was studied¹⁶. Statistical analysis using *t*-test for 2 dependent means was performed ($P=0.05$)⁹. All dogs were properly treated following the study period.

RESULTS

MSCs were identified by its morphology under an inverted microscope. On the day of collection, BM mononuclear cells and MSCs were rounded and close to each other. On the 3rd day, MSCs started to take their characteristic spindle shape and became adherent to specific tissue culture flasks. After repeated washing, more of the nonspecific cells were continuously removed, which gave wider space for the MSCs to propagate and multiply as was seen on the 7th and 10th days. A confluence sheet of 70% to 80% of the tissue culture flask was reached on the 14th day (Figure 1). Flow cytometry using CD90, CD73, and CD105 surface markers positively identified MSCs 98.21, 97.1, and 98.44, respectively (Figure 2).




Figure 1. Serial photographs showing (a) bone marrow cells on the day of collection; then subsequent MSC's growths: (b) MSC's growth on the 3rd day (c,d) MSCs took the spindle shape and adhered to the tissue culture flask; the nonspecific cells (rounded) were removed by washing at the 7th and 10th day (e) MSCs multiplied and increased in number until it reached a confluence sheet of up to 70% to 80% of the tissue culture flask at the 14th day

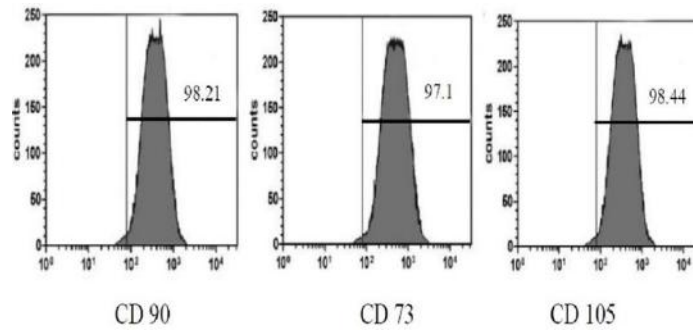


Figure 2. Flow cytometric analysis of MSCs showing the counts of different surface markers

Ultracentrifugation of DMEM media resulted in the gathering of exosome. Exosomes were identified by electron microscope. Differently sized well-defined spherical vesicles were detected (Figure 3). The cytofluorometric reactions toward markers CD44, CD63, and CD73 were 99.61, 98.99, and 99.71, respectively (Figure 4).

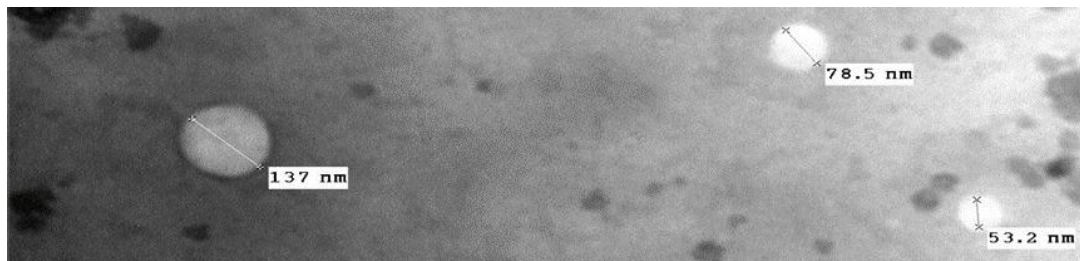

Figure 3. Electron microscopic photograph showing well-defined EVs of different sizes. Direct Mag 60000x

Figure 4: Cytofluorometric analysis of the obtained exosomal solution, notice the reaction toward different markers

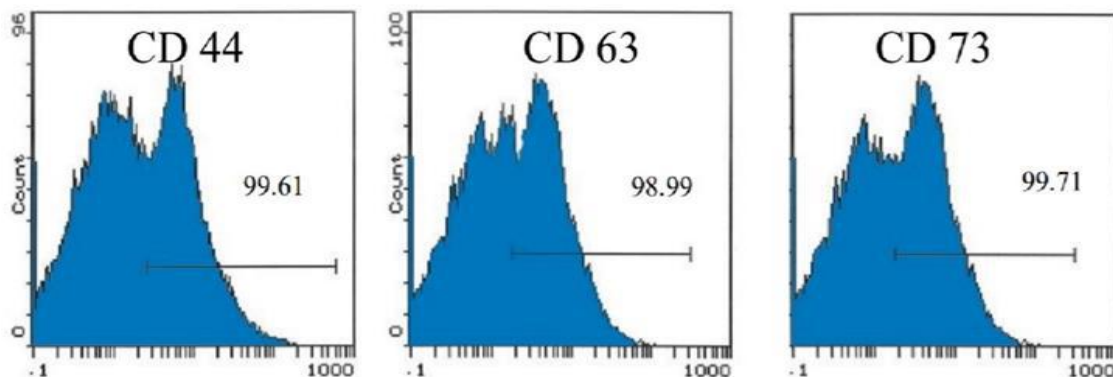


Figure 4. Cytofluorometric analysis of the obtained exosomal solution, notice the reaction toward different markers

Physical evaluation of the wounds

Clinically, wounds treated with preserved CMC exosome gel showed quicker healing than their counterparts treated with preserved CMC gel solely (Figure 5). Wounds were measured at 3, 7, 14, 21, and 28 days (Table 1). The wound reduction size was

greater in the treated group than the control group. The wound edges were more corrugated in the control group than the treated one (Figure 6). No animals had experienced wound infection or any other health issues.

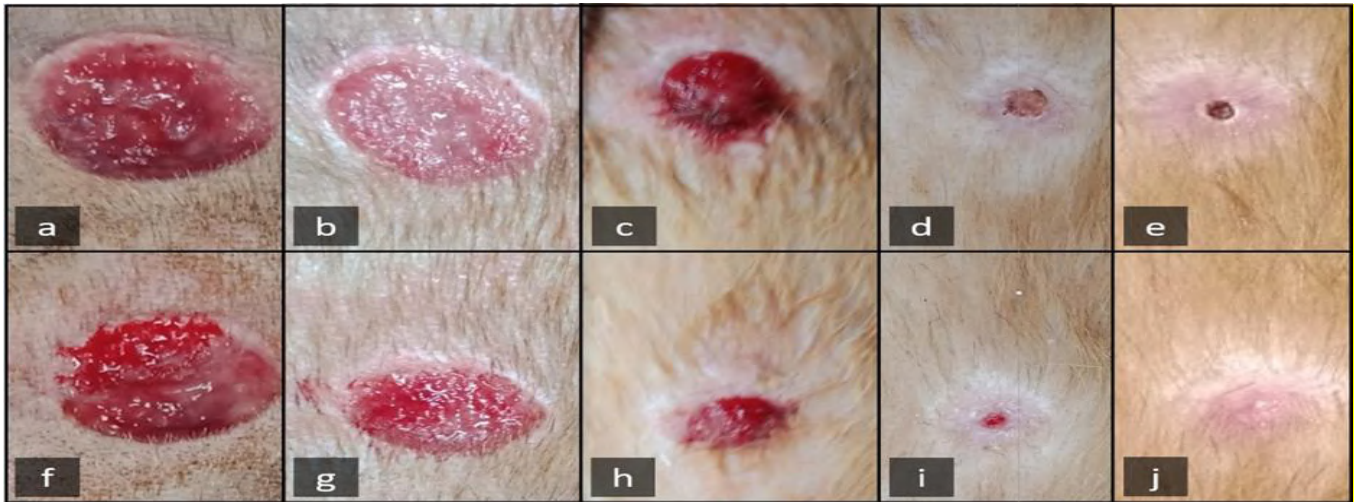

Figure 5: Photographs showing wound areas of the 2 groups at 3, 7, 14, 21, and 28 days: the (a-e) control group; (f-j) treated group. Notice the quicker healing and wound closure in the treated group than the control group with even healed surface

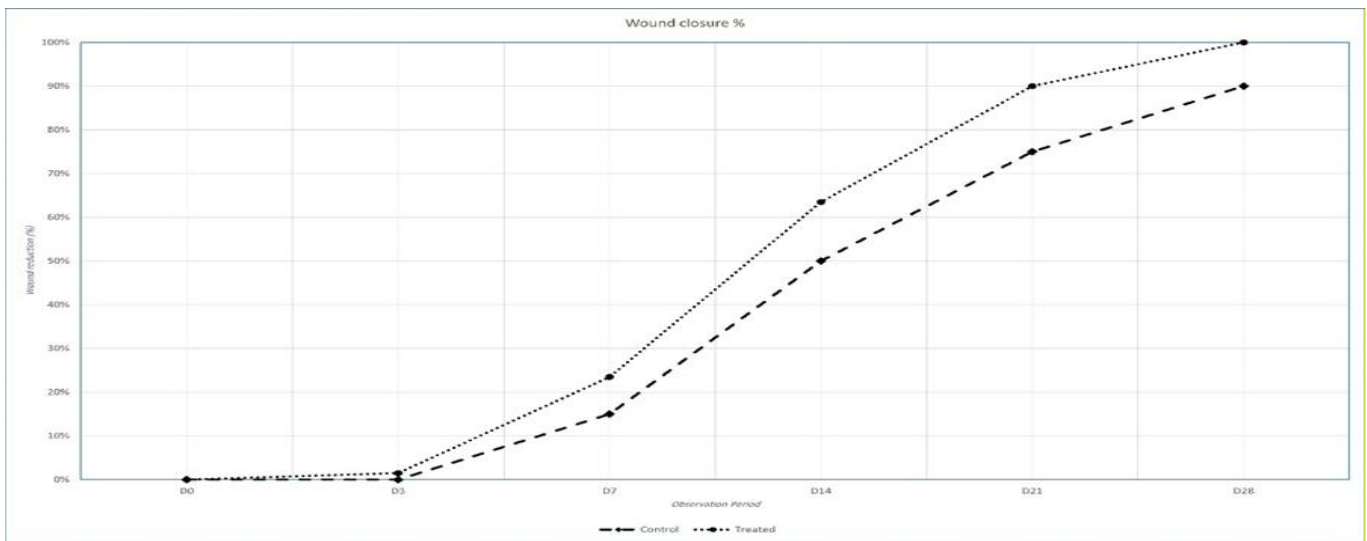


Figure 6: Histogram showing the wound closure percentage for the treated group compared with the control group during the follow-up period

Table 1: Mean and percentage of wound reduction size (compared with initial wound size) and the contraction difference between the control and treated groups. P<0.05 was considered statistically significant

	Control mean cm (%)	Treated mean cm (%)	Diff (Treated - Control)	Dev (Diff - M)	Sq. Dev
D0	2 (0%)	2 (0%)	0	0.16	0.03
D3	2 (0%)	1.97 (1.5%)	0.03	0.13	0.02
D7	1 (15%)	1.53 (23.5%)	-0.17	-0.01	0
D14	1 (50%)	0.73 (63.5%)	-0.27	-0.11	0.01
D21	0.5 (75%)	0.2 (90%)	-0.3	-0.14	0.02
D28	0.2 (90%)	0 (100%)	-0.2	-0.04	0
	Avg.=1.23	Avg.=1.07	M = -0.16		S= 0.08

The value of t is 3.21. The value of P=0.01181.

Histological evaluation of wound healing

Histologically, H&E sections of the control group at 3 days showed epidermal destruction, hemorrhage, and exudate infiltrated with inflammatory cells. This was followed by more cellular infiltration and mild angiogenesis on the 7th day. Reepithelization and fibrous granulation tissue were seen on the 14th day. The treated group showed the same level of epidermal damage and necrosis on the 3rd day with inflammatory cell infiltration, whereas the 7th day showed early proliferation of fibrous tissues with marked angiogenic activity. The wound sites were

narrow showing developed epithelial cells with enhanced cellularity and angiogenesis and subepidermal proliferation of collagen and fibroblasts on the 14th day (Figure 7). MTC histological sections of the control group showed a fibrous tissue deposition on the 3rd day. Few unorganized collagen fibers were interspersed between the fibrous tissue bundles on the 7th and 14th day. The treated group showed marked deposition of collagen bundles starting from the 3rd day that became more organized on the 7th and the 14th day (Figure 8).

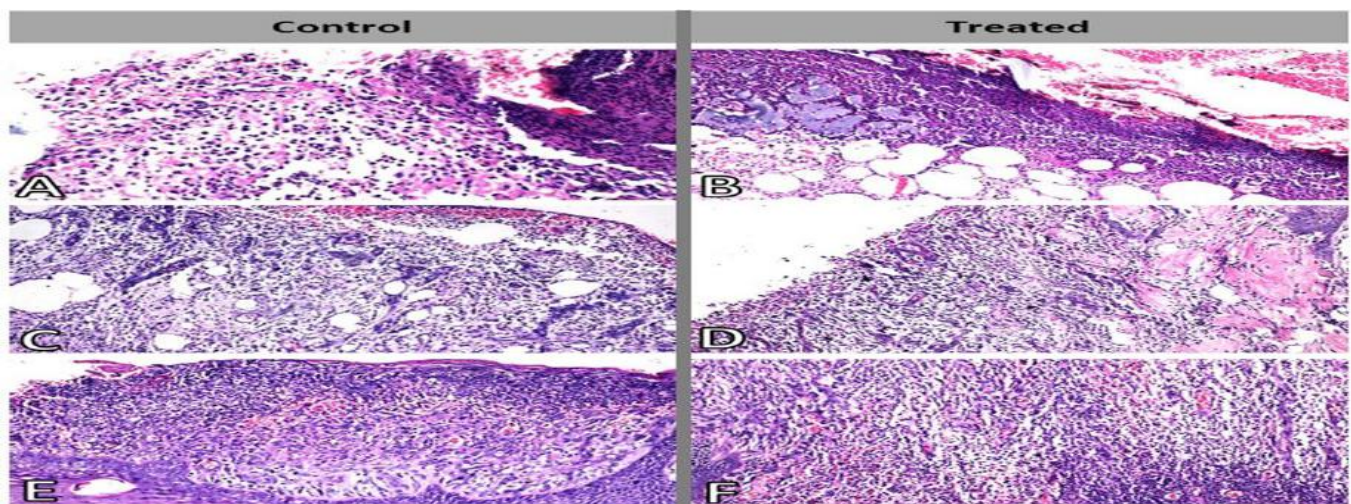


Figure 7. H&E histological skin sections of wound areas: (A) group I at 3 days of treatment disclosing the wound edge, with complete damage of epidermal layer; the dermis was infiltrated with inflammatory exudate, neutrophils, mononuclear cells, fibrin deposition, and necrotic debris. $\times 400$; (B) group II at 3 days showing damage of epidermal layer; the dermis at the wound area showed inflammatory exudates mixed with necrotic tissue debris and deposition of fat cells and hemorrhage $\times 200$; (C) group I on the 7th day showing the wound site with hemorrhage, infiltration of inflammatory cells, fat cells, and formation of new capillaries (angiogenesis). $\times 200$; (D) group II on the 7th day showing the damage to the epidermis, the dermis at the wound site populated with inflammatory exudate, proliferation of fibroblasts, and formation of new capillaries. $\times 200$; (E) group I on the 14th day showing reepithelization of wound surface with a large amount of granulation tissue formation over the epidermal layer. The dermis revealed the proliferation of fibroblasts and few collagens. $\times 400$; (F) group II on the 14th day showing contraction of wound edges with narrow wound site, enhanced cellularity, and increased vascularization, with subepidermal proliferation of fibroblasts and few mature collagen depositions. $\times 100$.

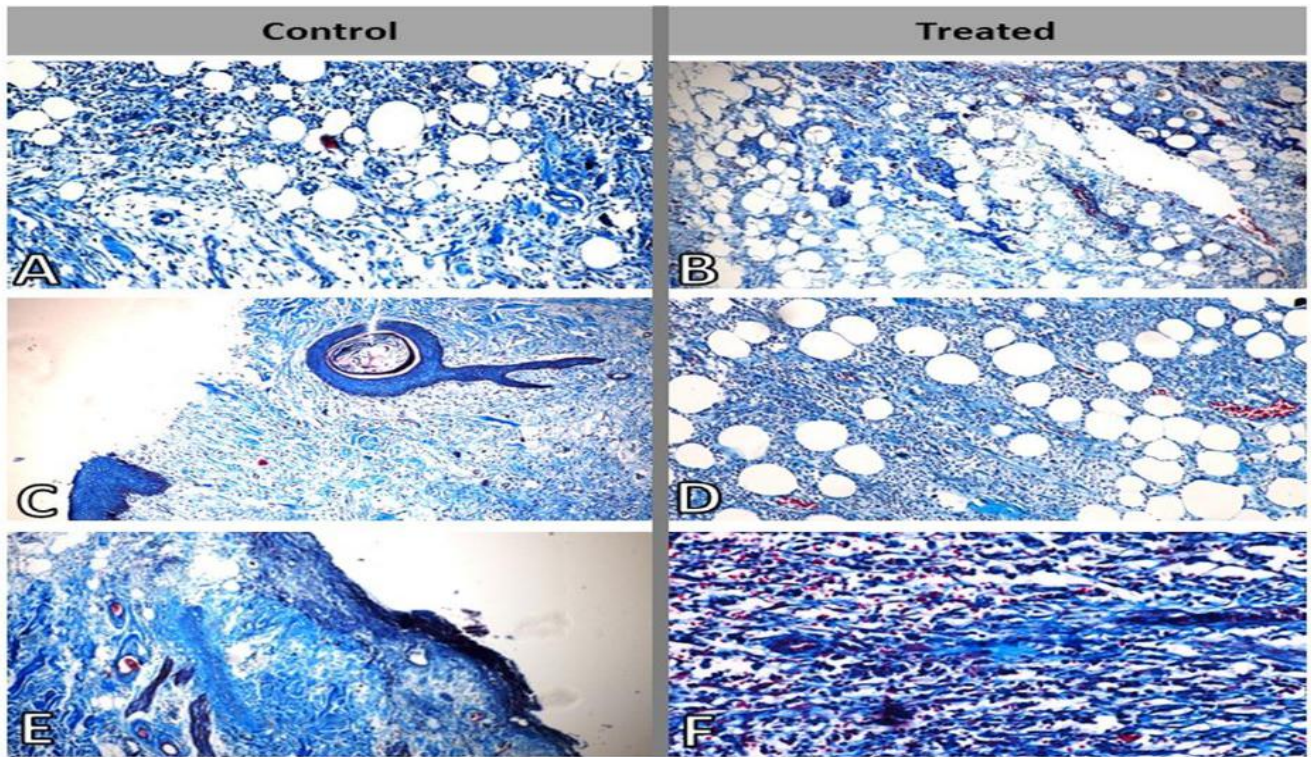


Figure 8. MTC histological skin sections of wound areas: (A) group I at 3 days of treatment showing the dermis at the wound site with few fibroblastic proliferations. $\times 400$; (B) group II at 3 days showing fat cells, few fibroblasts, and collagen deposition in the dermis. $\times 200$; (C) group I on the 7th day showing fibroblastic proliferation and few disorganized collagens. $\times 100$; (D) group II on the 7th day showing the proliferation of fibroblasts with few collagen depositions in the dermis. $\times 200$; (E) group I, day 14, showing the deposition of disorganized collagen and fibroblasts $\times 100$; (F) group II, day 14, showing enhanced dermal fibroblasts and organized collagen deposition in the dermis with hemorrhage. $\times 400$

Immunohistochemical evaluation of wound healing

Immunohistochemical staining of skin wound sections of the control group at 3 days revealed few expressions of both angiogenesis markers CD31 and α -SMA. On the 7th day, a mild positive expression of both markers was observed. On the 14th day, few positive expressions of both markers were observed. Alternatively, treated group revealed varying degrees of CD31 and α -SMA marker expression. The

3rd day of treatment showed scattered few positive expressions of the 2 markers. Distinct positive expression of the markers was more evident on the 7th day of treatment, followed by diminutive positive expression of α -SMA marker and slight immunoreactivities against the CD31 marker on the 14th day of treatment (Figures 9 and 10).

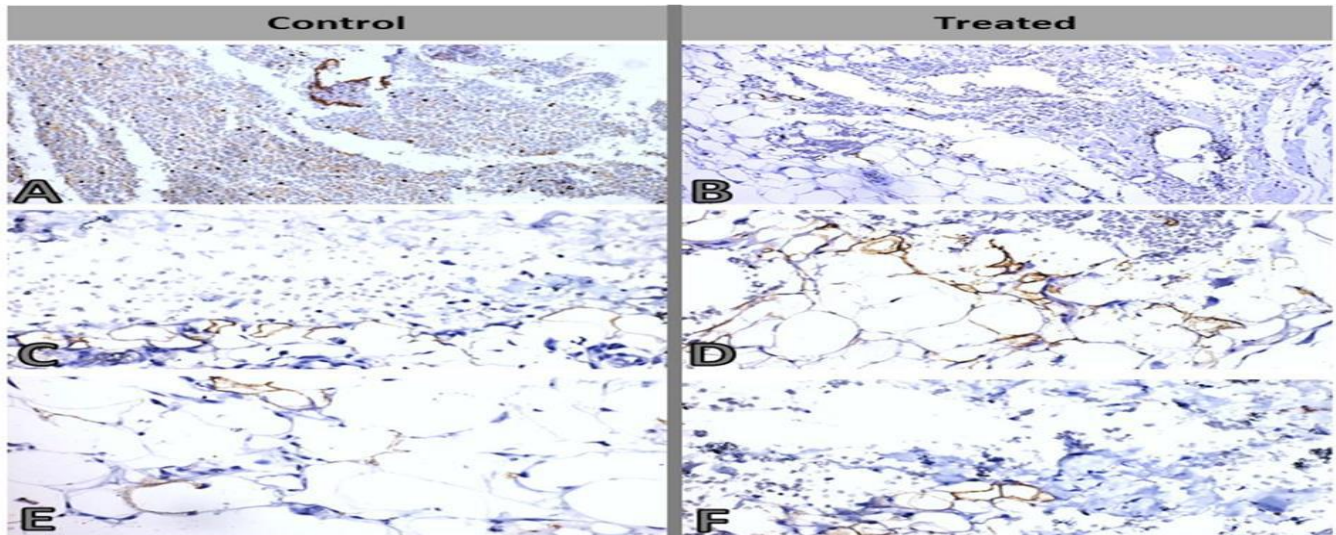


Figure 9. α -SMA-Immunohistochemistry of skin wound sections: (A) group I, 3 days of treatment revealing few expressions of α -SM antigen. $\times 400$; (B) group II, 3 days of treatment showing scattered few positive expression of α -SM antigen. $\times 400$; (C) group I, 7 days of treatment revealing mild positive expression against α -SM antigen. $\times 400$; (D) group II, 7 days of treatment showing increased positive expression of α -SM antigen. $\times 400$; (E) group I at 14 days of treatment showing few positive expressions against α -SM antigen. $\times 600$; (F) group II, 14 days of treatment revealing little positive expression of α -SMA. $\times 400$

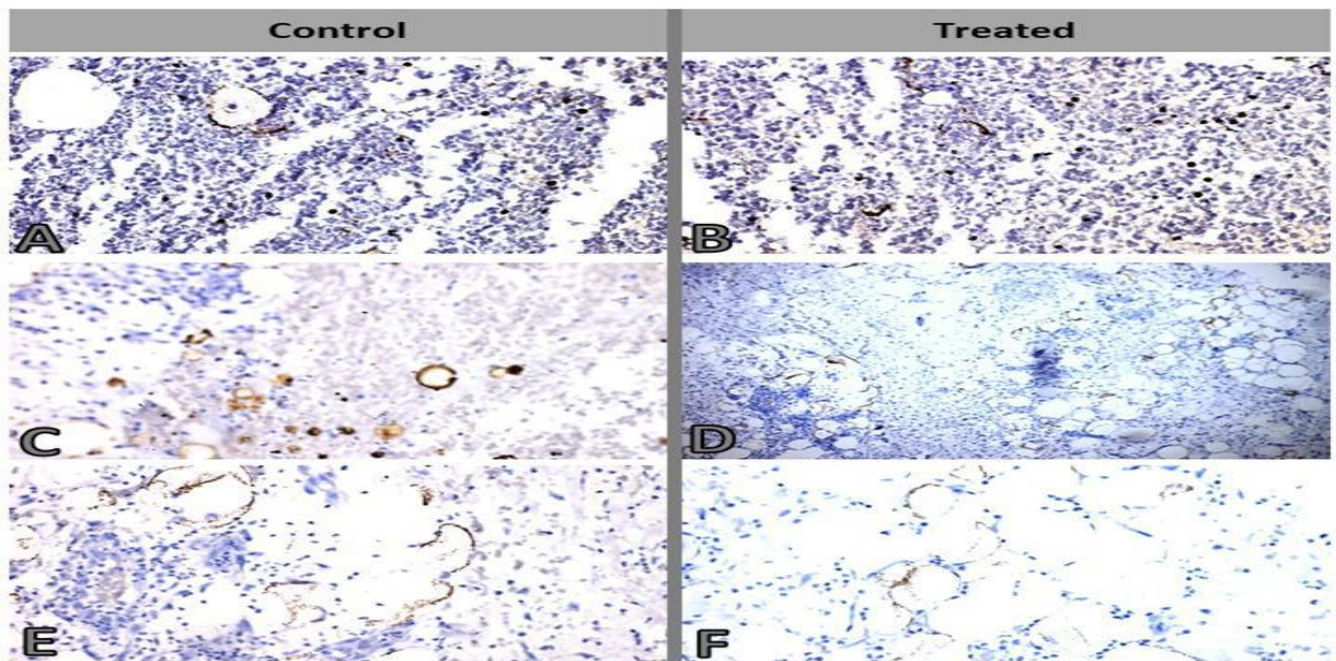


Figure 10. Avidin biotin immunoperoxidase of skin wound sections: (A) group I, 3 days of treatment showing few immunoreactivities against CD31 antigen as dense brown granules lining the new capillaries in the subepidermal layer $\times 400$; (B) group II, 3 days of treatment showing few immunoreactivity against CD31 antigen lining few capillaries $\times 400$; (C) group I, 7 days of disclosing mild positive immunoreactivity against CD31 antigen as dense brown granules lining some new capillaries $\times 400$; (D) group II, 7 days of treatment revealing increase immunoreactivity against CD31 antigen lining the neocapillaries $\times 200$; (E) group I, 14 days of treatment revealing positive immunoreactivity against CD31 antigen as dense brown granules lining the dermal new. $\times 400$; (F) group II, 14 days of treatment revealing few immunoreactivity against CD31 antigen in some new capillaries. $\times 400$

DISCUSSION

Exosomes are small EVs secreted by most cell types^{17,18} and play an important role in cell-cell communication^{19,20}. Different exosomal sizes have been postulated (30–120 nm²¹, 30–140 nm²², 40–100 nm²³), but all fall in the range of 30–200 nm²⁴. It was recently discovered that aside from its differentiation capacity, the effect of MSCs depends mainly on its exosomal secretion^{16,17}. However, recent studies suggested that the therapeutic use of MSCs has several drawbacks, such as poor engraftment efficiency, potential tumor formation, undesired immune responses, nonspecific differentiation, short half-life, and the difficulty of quality control before administration²⁴. Contrarily, growing evidence suggests that exosomes derived from stem cells could be a promising alternative because they would avoid most of the problems associated with cell-based therapy while recapitulating the therapeutic efficacy of stem cells²⁴. For example, because they cannot replicate, exosomes have no risk of tumor formation. They can also be sterilized by filtration and have a longer shelf-life than cells themselves. Being much smaller than stem cells, exosomes easily circulate through the body and reach injury sites. In addition, long-term repetitive administration of exosomes does not elicit toxicity²⁵.

The immunogenicity and toxicity of exosomes depend both on the animal models used in testing and on the source and composition of the exosomes. Although some argue that immortalized cell lines should not be used for the production of therapeutic exosomes, because some of the exosomal cargo may carry toxic or even carcinogenic constituents^{26,27}, different immortalized cells have been used commonly as exosome producers owing to the infinite supply of cells for exosomal production, increased proliferative rate, and the ease of genetically modifying these cells^{28,29}. Our results also showed that repeated administration of cryopreserved “heterogeneous” exosomes at 0.5×10⁶ mL per dose over a 4-week observation period from a single donor dog did not induce either toxicity or any appreciable immune response in

other recipient dogs. Similar conclusions were published by^{25,30}.

Previous studies proved the effectiveness of MSC exosomes in wound management through intradermal injection^{15,31}, local and systemic injection^{9,32,33}, or spray³⁴. Generally, the topical methods for skin wounds were statistically more effective than other routes of administration³⁵.

Nevertheless, the lengthy preparation time, exosomes cannot be maintained for a long time at RT at which exosomal proteins and RNA amounts are mostly reduced. In addition, flow cytometry results indicated that exosomal population became more dispersed after 10 days of RT incubation than the freshly isolated one³⁶. Therefore, it was worthy to find a preservation method that can maintain longer exosomal viability and at the same time keep it easy to use for topical application. Many strategies for exosomal preservation were suggested, such as lyophilization, cryopreservation, and spray drying³⁷, all of which poses some destructive effects on the biomolecules within the extracellular fluids.

Lyophilization and spray drying of exosomes may improve their stability at higher temperatures. However, it is unclear whether different types of exosomes can be processed by the same methodology. Further research should be performed to reveal these points²¹.

Cryopreservation in general depends on markedly lowering the temperature, consequently leading to inhibition of cellular enzymatic activity and thus decreasing material rapid decomposition³⁸. However, freezing of biomaterials results in ice crystal formation inside the cell, which leads to rupture of the phospholipid membrane and osmotic imbalance³⁹.

The International Society of Extracellular Vesicles recommended exosomes to be suspended in phosphate-buffered saline and stored at –80°C⁴⁰. It was previously shown that storage at higher temperatures decreased the quantity of exosomes and their contents, whereas storage at –80°C was associated with fewer changes^{41,42}. For therapeutic application, storage at higher temperatures is desirable because it does not require special

equipment²¹. It was stated that -20°C was the highest temperature at which exosomes from MSCs were stable⁴³, and the freeze-thaw cycles did not affect their stability that allowed their use and preservation⁴³⁻⁴⁵.

Improvements in the preservation procedures to further protect the exosomes and their cargo by adding bio-safe cryoprotectants in the formulation could be of great value. Cryoprotectants are divided into 2 main groups: (a) intracellular group that can penetrate inside the cells and prevent ice crystal formation and subsequently membrane rupture as dimethyl sulfoxide and glycerol, and (b) extracellular group that act by reducing the hyperosmotic effect during freezing procedure as trehalose, dextrose, and polyvinylpyrrolidone³⁹. The extracellular group of cryoprotectants as trehalose (natural nonreducing disaccharide) is used as a cryoprotectant for various proteins and cell products⁴⁶. It was revealed that the addition of trehalose protected exosomes from cryodamage⁴⁷.

In this study, Na-CMC was used as vehicle and a cryoprotectant for exosomes during freezing at -20°C . A suitable cryoprotectant must be bio-safe, cytocompatible, nontoxic, nonallergenic, and of a suitable viscosity. CMC has been devised as a dressing for treating burn wounds. It primarily maintains an optimal moist environment in the wound region for extracellular matrix formation and reepithelialization to occur⁴⁸. The moist regulation of the wound has been reported to have multiple advantages, namely, prevention of tissue dehydration and death, alleviation of pain sensation, promotion of angiogenesis, breakdown of dead tissue and fibrin, and interaction between growth factors and target cells^{49,50}. Furthermore, CMC films could aid wound healing through early physical eradication of some microbes from the tissue bed surfaces⁴⁸. In terms of tissue toxicity,⁵¹ stated that there was no significant toxicity on cells cultured with CMC for 5 days, at a concentration of 10–40 mg/mL, and there was no significant membrane rupture.

Despite significant efforts into this relatively new field of research, our understanding of exosomes remains limited by factors such as inefficient separation methods, lack of exclusive biomarkers,

and lack of high-resolution visualization techniques²². Because some components of biological fluids such as lipoprotein, chylomicrons, and microvesicles have size overlaps with exosomes, exosome isolation from raw biological fluids is challenging^{52,53}. Isolation from conditioned cell culture media is less complicated; however, other types of EVs are often coisolated²². In this study, exosomes were detected by electron microscope¹⁹ and cytofluorometric analysis⁹. Different vesicular sizes were observed under an electron microscope ranging from 25 nm to 191 nm.

The CMC gel was placed for 30 minutes under an ultraviolet lamp to circumvent the bacterial contamination and to break the medium amino acid chains, which could affect skin healing⁵⁴. The exosomal solution was added to sterile CMC to have a concentration of 22 mg/mL, which falls in the safe range proposed by⁵¹. The formed exosome gel was kept at -20°C for preservation for 1 week. The number of exosomes used is the amount obtained from 2×10^6 MSCs per wound, similar to^{31,32,55}. The treatment was divided by 4 times of topical application; hence, each time the wound surface was covered with 1-mL gel, which contained exosomes obtained from 0.5×10^6 MSCs. Results obtained after 1 week of preservation followed by topical application on wounds indicated the proficiency of the CMC as a cryoprotectant capable of protecting the integrity of the exosomes; moreover, the exosomes were viable and exerted their anticipated effect.

Grossly, wounds treated with frozen exosomal gel showed early and better wound contraction, early crustation, and formation of healthy granulation tissue, consequently resulting in complete healing and covering of wound with regenerated tissue by the end of the second week. Alternatively, the control group exhibited delayed crustation, unhealthy granulation tissue formation, and delayed wound closure in the control group. There was no wound infection in either group, which could be attributed to the use of systemic antibiotic alongside the bacteriostatic nature of the CMC⁸.

The macroscopic findings revealed that the percentage of wound-size reduction for the treated group was 1.5%, 23%, and 63.5% on the 3rd, 7th, and

14th day after treatment compared with the control group of 0%, 15%, and 50% on the 3rd, 7th, and 14th day after treatment. The peak of wound reduction was during the second week after treatment in both groups. Statistical results showed a significant improvement in the wound reduction size of the treated group compared with the control group ($P=0.0118$). Compared with single subcutaneous injection of freshly prepared exosomal solution⁹, the wound-size percentage was reduced by 72.5% on the 14th day after treatment compared with 63.5% in the cryopreserved group. Although the wound reduction percentage was higher in the fresh group, the results firmly indicate the existence of viable exosomes after 1 week of cryopreservation, which opens the doors for longer preservation tests.

Tissue samples were taken on the 3rd, 7th, and 14th day after wounding. Because wound area was <0.5 cm that was not suitable for sample preparation, no samples were taken starting from the 21st day. All dogs were properly treated until full recovery. The microscopic findings revealed similar observations on the 3rd day of both groups, complete damage of epidermis, and dermal infiltration with inflammatory exudate, neutrophils, mononuclear cells, fibrin deposition, and necrotic debris. Starting from the 7th day, the wound site of the control group maintained the existence of hemorrhage and the inflammatory cells, with mild angiogenesis. Group II exhibited less hemorrhage, populated inflammatory exudate, and early proliferation of fibroblasts and moderate new capillary formation. Sections from group I on the 14th day displayed reepithelization of wound surface, with a large amount of granulation tissue formation over the epidermal layer. The dermis revealed late fibroblastic proliferation with few collagens. In contrast, group II exhibited more contraction of wound edges with narrow wound site, enhanced cellularity, and increased vascularization, with more subepidermal proliferation of fibroblasts and few mature collagen deposition. Similarly, MTC-stained skin sections of groups I and II presented the same picture except the collagen deposition in the dermis in the second group. On the 7th day, group I demonstrated fibroblastic proliferation with few disorganized collagens. Group II revealed more proliferation of fibroblasts with few but more

organized collagen depositions in the dermis. Sections taken on the 14th day in group I exhibited deposition of disorganized collagen and fibroblasts, whereas group II revealed enhanced dermal fibroblasts and well-organized collagen deposition in the dermis. Immunohistochemical staining of skin wound sections of group I at 3 days revealed few expressions of both angiogenesis markers that increased on the 7th day to a mild positive expression reaching a mild to moderate expression on the 14th day.

Wound sections treated with frozen microvesicle gel revealed scattered few positive expressions of the 2 markers on the 3rd day of treatment, which increased to a high positive expression on the 7th day followed by mild positive expression on the 14th day of treatment. These findings indicated quicker angiogenesis and proper collagen deposition in the treated group than the control group. The histological and immunohistochemical pictures of both techniques were substantially similar compared with a single subcutaneous injection of freshly prepared exosomal solution⁹.

CONCLUSION

In summary, cryopreservation with CMC as a cryoprotectant preserved the biological nature of the exosomes. There was no evidence of toxicity or undesirable immune responses from using the heterogeneous exosomes. The treated group demonstrated faster and better healing than the control group. Fibroblastic proliferation and angiogenesis started earlier in the treated group than the control group. The quality of healing in the treated group was better with no scar and organized collagen. The rapid clinical healing of the control group could be attributed to the beneficial properties of the CMC. In addition, the frequent application of the gel might be a reason for the better results than fresh, single injection. Prepared frozen gel was easy to handle and apply without the need for special equipment. Further studies will be needed to confirm how much the potency of long-term cryopreserved exosomes is affected and the medical possibility of using xenogenous exosomes.

Conflict Of Interest

The authors have no conflicting financial interest.

Funding

This research did not receive any specific grant from funding agencies in the public, commercial, or nonprofit sectors.

REFERENCES

1. Lötvall J, Hill AF, Hochberg F, et al. Minimal experimental requirements for definition of extracellular vesicles and their functions: a position statement from the International Society for Extracellular Vesicles. *J Extracell Vesicles* 2014;3:26913.
2. Camussi G, Deregibus MC, Cantaluppi V. Role of stem-cell-derived microvesicles in the paracrine action of stem cells. *Biochem Soc Trans* . 2013;41(1):283-7.
3. del Conde I, Shrimpton CN, Thiagarajan P, et al. Tissue-factor-bearing microvesicles arise from lipid rafts and fuse with activated platelets to initiate coagulation. *Blood*. 2005;106(5):1604–1611.
4. Bruno S, Grange C, Collino F, et al. Microvesicles derived from mesenchymal stem cells enhance survival in a lethal model of acute kidney injury. *PLoS One*. 2012;7(3):e33115.
5. Sudhakar Y, Kuotsu K, Bandyopadhyay AK. Buccal bioadhesive drug delivery—a promising option for orally less efficient drugs. *J Control release*. 2006;114(1):15–40.
6. Castellano JJ, Shafii SM, Ko F, et al. Comparative evaluation of silver-containing antimicrobial dressings and drugs. *Int Wound J*. 2007;4(2):114–122.
7. Capanema NS V, Mansur AAP, de Jesus AC, et al. Superabsorbent crosslinked carboxymethyl cellulose-PEG hydrogels for potential wound dressing applications. *Int J Biol Macromol*. 2018;106:1218–1234.
8. Shimamura MK, Kamata K, Yao A, et al. Scattering functions of knotted ring polymers. *Phys Rev E Stat Nonlin Soft Matter Phys* . 2005;72(4 Pt 1):041804.
9. El-Tookhy OS, Shamaa AA, Shehab GG, et al. Histological evaluation of experimentally induced critical size defect skin wounds using exosomal solution of mesenchymal stem cells derived microvesicles. *Int J stem cells*.; 2017;10(2):144-153.
10. Jung D-I, Ha J, Kim J-W, et al. Canine mesenchymal stem cells derived from bone marrow: isolation, characterization, multidifferentiation, and neurotrophic factor expression in vitro. *J Vet Clin*. 2008;25(6):458–465.
11. Ryu H-H, Kang B-J, Park S-S, et al. Comparison of mesenchymal stem cells derived from fat, bone marrow, Wharton's jelly, and umbilical cord blood for treating spinal cord injuries in dogs. *J Vet Med Sci*. 2012; 74(12):1617-30.
12. Théry C, Amigorena S, Raposo G, et al. Isolation and characterization of exosomes from cell culture supernatants and biological fluids. *Curr Protoc cell Biol*. 2006 Apr;Chapter 3:Unit 3.22.
13. Adam JA. A simplified model of wound healing (with particular reference to the critical size defect). *Math Comput Model*. 1999;30(5–6):23–32.
14. Karayannopoulou M, Tsioli V, Loukopoulos P, et al. Evaluation of the effectiveness of an ointment based on Alkannins/Shikonins on second intention wound healing in the dog. *Can J Vet Res*. 2011;75(1):42–48.
15. Kim J, Lee J, Lyoo YS, et al. The effects of topical mesenchymal stem cell transplantation in canine experimental cutaneous wounds. *Vet Dermatol*. 2013;24(2):242-e53.
16. Zhang J, Guan J, Niu X, et al. Exosomes released from human induced pluripotent stem cells-derived MSCs facilitate cutaneous wound healing by promoting collagen synthesis and angiogenesis. *J Transl Med*. 2015;13:49.
17. Rani S, Ryan AE, Griffin MD, et al. Mesenchymal stem cell-derived extracellular vesicles: toward cell-free therapeutic applications. *Mol Ther*. 2015;23(5):812–823.
18. Togel F, Weiss K, Yang Y, et al. Vasculotropic, paracrine actions of infused mesenchymal stem cells are important to the recovery from acute kidney injury. *Am J Physiol Physiol*. 2007;292(5):F1626–35.
19. Simons M, Raposo G. Exosomes-vesicular carriers for intercellular communication. *Curr Opin Cell Biol*. 2009;21(4):575–81.
20. Kinnaird T, Stabile E, Burnett MS, et al. Marrow-derived stromal cells express genes encoding a broad spectrum of arteriogenic cytokines and promote in vitro and in vivo arteriogenesis through paracrine mechanisms. *Circ Res*. 2004;94(5):678–85.
21. Yamashita T, Takahashi Y, Takakura Y. Possibility of exosome-based therapeutics and challenges in production of exosomes eligible for therapeutic application. *Biol Pharm Bull*. 2018;41(6):835–842.
22. Li X, Corbett AL, Taatizadeh E, et al. Challenges and opportunities in exosome research—Perspectives from biology, engineering, and cancer therapy. *APL Bioeng*. 2019;3(1):011503.
23. Ha D, Yang N, Nadiithe V. Exosomes as therapeutic drug carriers and delivery vehicles across biological membranes: current perspectives and future challenges. *Acta Pharm Sin B*. 2016;6(4):287–96.
24. Lou G, Chen Z, Zheng M, et al. Mesenchymal stem cell-derived exosomes as a new therapeutic strategy for liver diseases. *Exp Mol Med*. 2017;49(6):e346.

25. Mendt M, Kamerkar S, Sugimoto H, et al. Generation and testing of clinical-grade exosomes for pancreatic cancer. *JCI Insight*. 2018; 3(8):e99263.
26. Nakamura K, Sawada K, Kinose Y, et al. Exosomes promote ovarian cancer cell invasion through transfer of CD44 to peritoneal mesothelial cells. *Mol Cancer Res*. 2017;15(1):78–92.
27. He M, Qin H, Poon TCW, et al. Hepatocellular carcinoma-derived exosomes promote motility of immortalized hepatocyte through transfer of oncogenic proteins and RNAs. *Carcinogenesis*. 2015;36(9):1008–18.
28. Pollock K, Stroemer P, Patel S, et al. A conditionally immortal clonal stem cell line from human cortical neuroepithelium for the treatment of ischemic stroke. *Exp Neurol*. 2006;199(1):143–55.
29. Chen TS, Arslan F, Yin Y, et al. Enabling a robust scalable manufacturing process for therapeutic exosomes through oncogenic immortalization of human ESC-derived MSCs. *J Transl Med*. 2011;9:47.
30. Zhu X, Badawi M, Pomeroy S, et al. Comprehensive toxicity and immunogenicity studies reveal minimal effects in mice following sustained dosing of extracellular vesicles derived from HEK293T cells. *J Extracell Vesicles*. 2017;6(1):1324730.
31. Abd-Allah SH, El-Shal AS, Shalaby SM, et al. The role of placenta-derived mesenchymal stem cells in healing of induced full-thickness skin wound in a mouse model. *IUBMB Life*. 2015;67(9):701–9.
32. Basiouny HS, Salama NM, El Maadawi ZM, et al. Effect of bone marrow derived mesenchymal stem cells on healing of induced full-thickness skin wounds in albino rat. *Int J Stem Cells*. 2013;6(1):12-25.
33. Tark K-C, Hong J-W, Kim Y-S, et al. Effects of human cord blood mesenchymal stem cells on cutaneous wound healing in leprdb mice. *Ann Plast Surg*. 2010;65(6):565–72.
34. Falanga V, Iwamoto S, Chartier M, et al. Autologous bone marrow–derived cultured mesenchymal stem cells delivered in a fibrin spray accelerate healing in murine and human cutaneous wounds. *Tissue Eng*. 2007;13(6):1299–312.
35. Petrilli R, Lopez RFV. Brasil- methods for topical skin drug delivery: concepts and applications. *Braz J Pharm. Sci*. 2018; 54 (spe).
36. Lee M, Ban J-J, Im W, et al. Influence of storage condition on exosome recovery.. *Bioprocess Biosyst Eng*. 2016;21(2):299–304.
37. Kusuma GD, Barabadi M, Tan JL, et al. To protect and to preserve: novel preservation strategies for extracellular vesicles. *Front Pharmacol*. 2018;9:1199.
38. Bennett TP, Frieden E. Worthington publication which was originally published in 1972 as the Manual of Clinical Enzyme Measurements: Modern Topics in Biochemistry. Macmillan, London; 1969.
39. Janz F de L, Debes A de A, Cavaglieri R de C, et al. Evaluation of distinct freezing methods and cryoprotectants for human amniotic fluid stem cells cryopreservation. *Biomed Res Int*. 2012;2012;1-10.
40. Witwer KW, Buzas EI, Bemis LT, et al. Standardization of sample collection, isolation and analysis methods in extracellular vesicle research. *J Extracell Vesicles*. 2013; 2.
41. Zhou H, Yuen PST, Pisitkun T, et al. Collection, storage, preservation, and normalization of human urinary exosomes for biomarker discovery. *Kidney Int*. 2006;69(8):1471–6.
42. Munagala R, Aqil F, Jeyabalan J, et al. Bovine milk-derived exosomes for drug delivery. *Cancer Lett*. 2016;371(1):48–61.
43. Sokolova V, Ludwig A-K, Hornung S, et al. Characterisation of exosomes derived from human cells by nanoparticle tracking analysis and scanning electron microscopy. *Colloids Surf B Biointerfaces* . 2011; 87(1):146-50.
44. Lv LL, Cao Y, Liu D, et al. Isolation and quantification of microRNAs from urinary exosomes/microvesicles for biomarker discovery. *Int J Biol Sci*. 2013;9(10):1021-31.
45. Ge Q, Zhou Y, Lu J, et al. miRNA in plasma exosome is stable under different storage conditions. *Molecules*. 2014;19(2):1568–75.
46. Eroglu A, Russo MJ, Bieganski R, et al Intracellular trehalose improves the survival of cryopreserved mammalian cells. *Nat Biotechnol*. 2000;18(2):163-7.
47. Bosch S, De Beaurepaire L, Allard M, et al. Trehalose prevents aggregation of exosomes and cryodamage. *Sci Rep*. 2016;6:36162.
48. Ramli NA, Wong TW. Sodium carboxymethylcellulose scaffolds and their physicochemical effects on partial thickness wound healing. *Int J Pharm*. 2011;403(1–2):73–82.
49. Field CK, Kerstein MD. Overview of wound healing in a moist environment. *Am J Surg*. 1994;167(1A): 2S-6S.
50. Stashak TS, Farstvedt E, Othic A. Update on wound dressings: indications and best use. *Clin Tech Equine Pract*. 2004;3(2):148–163.
51. Rodrigues C, de Assis AM, Moura DJ, et al. New therapy of skin repair combining adipose-derived mesenchymal stem cells with sodium carboxymethylcellulose scaffold in a pre-clinical rat model. *PLoS One*. 2014;9(5):e96241.
52. Wu M, Ouyang Y, Wang Z, et al. Isolation of exosomes from whole blood by integrating acoustics and

microfluidics. *Proc Natl Acad Sci U S A* . 2017 Oct 3;114(40):10584-10589.

53. Yuana Y, Levels J, Grootemaat A, et al. Co-isolation of extracellular vesicles and high-density lipoproteins using density gradient ultracentrifugation. *J Extracell Vesicles*. 2014;3.

54. Iacono E, Lanci A, Merlo B, et al. Effects of amniotic fluid mesenchymal stem cells in carboxymethyl cellulosegel on healing of spontaneous pressure sores: clinical outcome in sevenhospitalized neonatal foals. *Turkish J Biol*. 2016;40(2):484–492.

55. Fu X, Fang L, Li X, et al. Enhanced wound-healing quality with bone marrow mesenchymal stem cells autografting after skin injury. *Wound Repair Regen*. 2006;14(3):325-35.