

# The Role of Ultrasonography for Diagnosing Wilms Tumor in Developing Country

Aulia Rahmani<sup>1</sup>, Nur Melani Sari<sup>2</sup>, Vita Indriasari<sup>3</sup>

<sup>1</sup>Faculty of Medicine, Universitas Padjadjaran, Bandung, Indonesia

<sup>2</sup>Departement of Pediatrics, Hematology & Oncology Division, Faculty of Medicine, Universitas Padjadjaran/Dr. Hasan Sadikin Hospital, Bandung, Indonesia

<sup>3</sup>Departement of Pediatric Surgery, Faculty of Medicine, Universitas Padjadjaran/ Dr. Hasan Sadikin General Hospital, Bandung, Indonesia

**Corresponding Author:** Aulia Rahmani, Faculty of Medicine, Universitas Padjadjaran, Bandung, Indonesia

Tel: +62 87743630533

Email: aulia16007@mail.unpad.ac.id

Received: 29, Dec, 2019

Accepted: 14, Dec, 2020

## ABSTRACT

**Background:** Overall five-year survival rate of Wilm's Tumor (WT) in developing countries is still poor. Delayed diagnosis is one of the contributing factors, whereas early diagnosis is an important thing for the outcome. It is caused by the WT burden in developing countries that was not comparable with the number of facilities for diagnosis and treatment. Ultrasonography (USG) is the mandatory first-line imaging modality in children with a suspected abdominal mass and an overall sensitivity of 76%. Additionally, it can be found in many health facilities at a lower cost, quick, non-invasive, and carries no risk of radiation. Therefore, the relationship between USG and histopathology should be measured.

**Materials and Methods:** A cross-sectional study with an analytical approach was performed in pediatric (0 until 18 year of age) renal malignancy and neuroblastoma that admitted to Dr. Hasan Sadikin Hospital, Bandung between 2015-2018. Data were collected from medical records. Statistical analyses using Fisher exact test were done to determine the significance of the relationship between USG and histopathology.

**Results:** Forty-three samples were obtained based on inclusion criteria, such as WT (n=33), neuroblastoma (n=6), renal clear cell carcinoma (n=2) and no specific type of renal malignancy (n=2). Fisher exact test revealed no-significant relationship between USG and histopathology with p-value > 0.05

**Conclusion:** There is no significant relationship between USG and histopathology. Therefore, centralized unity for USG interpretation is recommended.

**Keywords:** Wilms tumor (WT); Ultrasonography (USG); Histopathology

## INTRODUCTION

Nephroblastoma or Wilms Tumor (WT) is the most common renal malignancy in children (85% cases).<sup>1,2</sup> It accounts for 5% of all childhood malignancies.<sup>3</sup> Data from Dr. Hasan Sadikin General Hospital stated 24 pediatrics WT during 2014-2016.<sup>4</sup> Patients usually come to hospitals at an advanced stage.<sup>5</sup> Currently, most high-income countries reported that survival at 5 years is more than 90% for children with localized disease and 70% for distant metastatic disease.<sup>6,7</sup>

However, the outcome in developing countries is still poor with most studies report less than 50% survival at 5 years.<sup>8,9</sup>

Delayed diagnosis is one of the contributing factors for low survival rate in developing countries, whereas early diagnosis is an important factor for the outcome. It is caused by lack of facilities for diagnosis and treatment, lack of multidisciplinary collaboration, long distances to treatment centers and also lack of parental awareness about early signs

and symptoms of childhood malignancy.<sup>10,11,12</sup> Other causes of the low survival rate include refusal and abandonment of treatment, preference for alternative medicine, financial difficulties coupled with lack of health insurance.<sup>13,14</sup>

WT patient is diagnosed sequentially by history taking, physical examination, laboratory investigation followed by imaging and histopathologic examinations. The physician usually uses Ultrasonography (USG) and CT scan as an imaging examination. CT scan is important for diagnosis because it is relevant and accurate to determine the staging of WT.<sup>15</sup> But practically it is not yet available in many health facilities, expensive and contain radiation effect.<sup>16,17</sup> Therefore, ultrasonography (USG) is needed as an alternative imaging examination with the overall sensitivity is 76%.<sup>18,19</sup>

According to UMBRELLA SIOP–RTSG 2016 protocol, USG is the mandatory first-line imaging modality in children with a suspected abdominal mass. USG is enough to evaluate whether the abdominal mass originates from the kidney or not and whether the component is solid or cystic. Additionally, the role of ultrasonography in developing country should be large, because it can be found and performed in many health facilities, low cost, fast, non-invasive, and doesn't contain radiation effect.<sup>20,21</sup> If the study is significant, the umbrella protocol can be used as a new protocol to diagnose WT. Hopefully, it can improve the survival rate, especially in developing countries.

Currently, the study report on ultrasonography examination for WT patients in Indonesia does not yet exist. The aim of this study is to find relationship between USG with histopathology findings as a gold standard for diagnosing WT.

## MATERIALS AND METHODS

A cross-sectional medical record study was conducted with an analytical approach. The sample was collected in August-October 2019 using medical records from inpatient, outpatient, Hospital Information System (SIRS) and Bandung Pediatric Cancer Registry. All children (0-18 years old) representing with renal malignancy and neuroblastoma at Dr. Hasan Sadikin General Hospital

from January 1<sup>st</sup>, 2015 until December 31<sup>th</sup>, 2019 were included. The exclusion criteria were incomplete data (never done USG and/or histopathology examination), lost medical record data, inaccessible data and the results of histopathology examination were not renal malignancy or neuroblastoma.

The study was approved by the Health Research Ethics Committee of Universitas Padjadjaran, Bandung through a letter of approval number 808/UN6.KEP/EC/2019 and was permitted by the Medical Research Ethics Committee of Dr. Hasan Sadikin General Hospital with a letter Number LB.02.01/X.2.2.1/12581/2019. This study was also acknowledged and approved by Pediatrics Department and Pathology Anatomy Department of Dr. Hasan Sadikin General Hospital and Hospital Information System (SIRS).

Data analysis includes sample of demographic characteristics such as age and gender; USG finding; histopathology finding, treatment protocol, and tumor distribution. USG finding was classified based on location (intrarenal and extrarenal) and type (solid, cystic and mix) of mass. Histopathology finding was classified based on histological subtypes into blastemal, epithelial and stromal. Treatment was classified based on first treatment that given to patients such as preoperative chemotherapy (SIOP 2001 protocol) or nephrectomy (COG/NWTSG protocol). And tumor distribution was classified into localized and metastatic tumors based on Toronto guidelines.<sup>22</sup>

The statistical analysis was performed using Microsoft<sup>®</sup> Excel 2016 and Statistical Package for Social Sciences (IBM<sup>®</sup> SPSS<sup>®</sup> Statistics Data Editor version 23). USG and histopathology relationship analyzed by Fisher Exact Test and  $p < 0.05$  considered statistically significant.

## RESULTS

Seventy-eight children with renal malignancy and neuroblastoma were admitted to Dr. Hasan Sadikin General Hospital during the period of study and among them, 43 data fulfilled the inclusion criteria of this study. 30 data were excluded because there were no USG and/or histopathology findings. Thirty-three children who diagnose WT were included in

the case group and 10 children who diagnose renal malignancy (except WT) or neuroblastoma were included in the control group.

**Table 1.** Characteristics of the patient

Variable	Wilm's Tumor n=33	non-Wilm's Tumor n=10
Age at diagnosis, years		
Median	3.00	3.00
Range	0-13	0-16
Gender		
• Male	18 (41.9)	4 (9.3)
• Female	15 (34.9)	6 (13.9)

Patient characteristics are presented in Table 1, the age of WT patients ranges between 0-13 with the median age at diagnosis was approximately 3 years.

Most WT patients were male and the male to female ratio was 6:5.

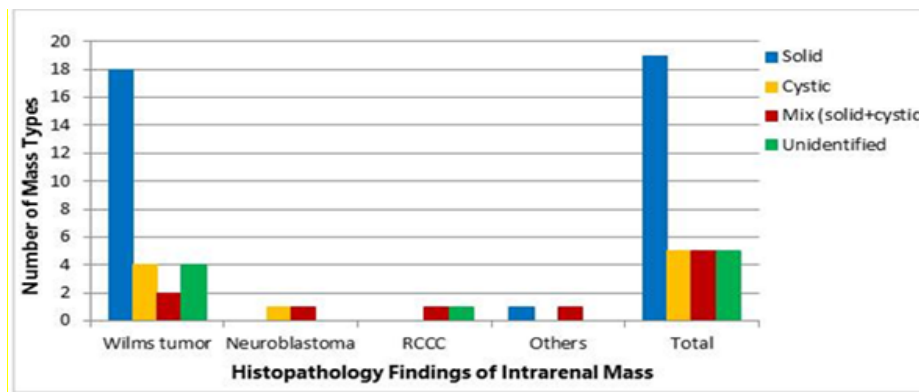


Figure 1 Distribution of renal mass type in accordance with histopathology findings of intrarenal mass

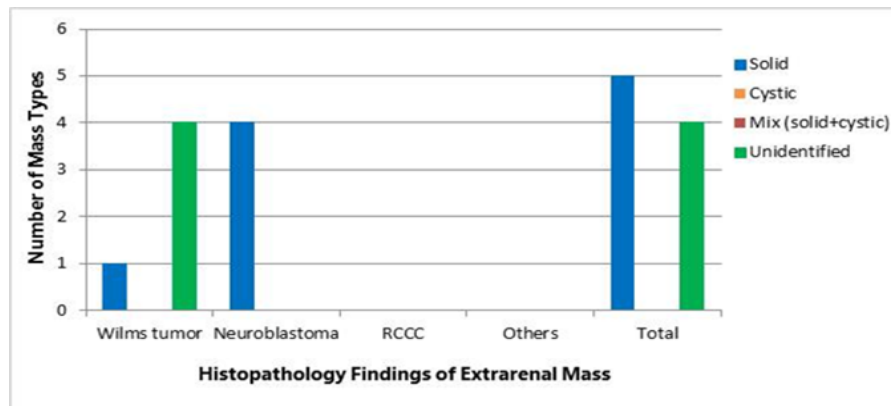


Figure 2 Distribution of renal mass type in accordance with histopathology findings of extrarenal mass

**Table 2.** Histopathology Findings, Primary Treatment and Mass Distribution in Wilms Tumor

Variable	n (%)
Histopathology examination	
• Blastemal + stromal +epithelial	7 (21.2)
• Blastemal + stromal	4 (12.1)
• Blastemal + epithelial	2 (6.1)
• Unidentified	20 (60.6)
Treatment Protocol	
• Preoperative chemotherapy (SIOP)	15 (45.4)
• Nephrectomy (COG/NWTSG)	10 (30.3)
• Unidentified	8 (24.3)
Mass Distribution	
• Localized	29 (87.9)
• Metastasis	4 (12.1)
Total	33 (100)

Histopathology findings in table 2 showed a subtype component, but 20 samples were unidentified. Preoperative chemotherapy becomes the majority primary treatment for WT patients used by

physicians in Dr. Hasan Sadikin General Hospital. And also in mass distribution showed patients with localized mass (87.9%) more than patients with metastasis (12.1%).

**Table 3.** Cross tabulation USG and histopathology examination

USG	Wilms Tumor (Histopatologi)		Total n (%)	P-value
	Positive Wilm's Tumor n (%)	Negative Wilm's Tumor n (%)		
Positive Wilm's Tumor	28 (65.1)	6 (14)	34 (79.1)	0.177*
Negative Wilm's Tumor	5 (11.6)	4 (9.3)	9 (20.9)	
Total	33 (76.7)	10 (23.3)	43 (100.0)	

\*Fisher's Exact Test

Table 3 illustrated the relationship between ultrasonography and histopathology. All children who diagnose Wilms Tumor based on histopathology findings were 33 patients, and the majority were positive WT in USG findings with p-value = 0.177.

## DISCUSSION

This study reveals the age of WT patients ranges between 0-13 with the median age at diagnosis was approximately 3 years. Most WT patients were male with male to female ratio is 6:5. This finding was similar to a study from Soyemi SS et.al, 2013 who reported that 44 pediatric WT patients in Lagos State University Teaching Hospital, Nigeria have the median age of 3 years at diagnosis.<sup>23</sup> Another study

conducted by F Rais et.al, 2016 at Departement of Hemato-oncology in Children Hospital of Rabat also stated that WT in children were frequent in male with the ratio of male to female (10:9).<sup>24</sup>

Most USG findings were intrarenal mass (n=34) and the majority showed solid type (n=19). This study was in line with an article from Lisa H. Lowe, MD about variety of pediatric renal masses that explained the characteristics of WT in children mostly appear large solid mass, often vascular invasion.<sup>25</sup> Ellen M. Chung et.al also explained that the margin was smooth and well-defined margin formed a pseudocapsule. Areas of necrosis and cystic appear hypoechoic and/or anechoic while

hemorrhagic, fat and calcification appear hyperechoic.<sup>26,21</sup>

Histopathology is performed after Fine Needle Aspiration Biopsy (FNAB) and/or Nephrectomy. Only 13 samples that explained the subtype of histopathology findings in this study and 20 samples were unidentified. Triphasic component was the most component (21.2%), followed by blastemal+stromal (12.1%) and blastemal+epithelial (6.1%). This result was similar to a study from Soyemi SS et.al, 2013 revealed 100% from 44 patients WT who didn't have neo-adjuvant chemotherapy exhibiting triphasic histological pattern.<sup>27</sup> But, another study from Innocent et.al,2019 found that the most common subtype was blastemal monophasic (43%), followed by triphasic type (35%) and blastemal-stromal (22%).<sup>28</sup>

According to SIOP 2001, triphasic type (blastemal+epithelial+stromal) is a classical pattern in histopathology of WT.<sup>2</sup> Blastemal component presume the most malignant component.<sup>29</sup> Neo-adjuvant chemotherapy may modify the histopathological patterns, therefore patients who performed nephrectomy before chemotherapy susceptible to have triphasic pattern.<sup>30</sup> Chemotherapy destroyed blastemal and epithelial element, while induced maturation in stromal component. Differentiation of stroma cell in the form of well-differentiated smooth or skeletal muscle cells, fat tissue, cartilage, bone and even glial tissue. Presence of blastemal after preoperative chemotherapy indicated that it does not respond to chemotherapy.<sup>2</sup>

Treatment protocol in WT patients divided into SIOP 2001 protocol (preoperative chemotherapy) and COG protocol (primary surgery). SIOP protocol can't be performed for patient under 6 months old, while COG protocol can't be used for bilateral WT.<sup>31</sup> In this study, neo-adjuvant chemotherapy was given to 15 patients (45.4 %) and nephrectomy was the initial treatment in 10 patients (30.3 %). Two patients with WT bilateral gave neo-adjuvant chemotherapy before surgery, this procedure can reduce tumor component in WT bilateral before resected. Besides, a patient under 6 months old performed surgery before chemotherapy.

Mass distribution in this study showed patients with localized mass (87.9%) more than patients with metastasis (12.1%). This study was in line with the previous study conducted by Atteby Jean-Jacques Yao et.al, 2019 which revealed children with localized mass (n=158) more than children with metastasis (n=11)<sup>32</sup>.

Both USG and histopathology examinations are performed for diagnosing WT. According to Umbrella Protocol, USG is first choice investigation in suspected WT and sufficient to diagnosis WT.<sup>21</sup> This study reported all children who diagnose Wilms Tumor based on histopathology findings were 33 patients, and 28 patients among them have positive WT in USG findings. The USG is positive if the tumor comes from the kidney and negative if the tumor is located outside of the kidney. There were 5 patients with histopathologically positive but negative in USG findings because several cases in WT showed mass outside of the kidney (extrarenal WT cases). And from 10 patients with negative WT, 6 patients among them have positive results in USG. It is caused by several conditions, such as WT only accounts for 85% of all renal malignancies, therefore not all intrarenal mass is WT. Additionally, neuroblastoma intra-abdominal sometimes invade the kidney and show an intrarenal-mass in USG findings.<sup>33</sup>

This study revealed no-significant relationship. That was different from the Umbrella Protocol statement which stated that USG was sufficient for diagnosing WT. The researcher suggested that the no-significant results were impacted by USG finding which was not centralized from Dr. Hasan Sadikin General Hospital only. USG was operator-dependent, so it probable to have different perceptions and interpretations.<sup>34</sup>

Limitations of this study are difficulty in accessing result of USG and histopathology examination because not all results noted and placed in the medical records, especially for referral patients. Besides, the researcher could not take the data under 2014 because it was destroyed.

In conclusion, there is no-significant relationship between USG and histopathology for diagnosing WT. The reasons are the data collected using medical records (a lot of incomplete and missing data), USG from various operators and health facilities. As such

long period of prospective study that centralized in one health facility is necessary to reduce data exclusion.

#### ACKNOWLEDGMENTS

We would like to thank Departement of Pediatric Hemato-Oncology, Departement of Pathology Anatomy and Departement of Pediatric Surgery at Hasan Sadikin General Hospital Bandung for providing us an opportunity to review their medical records

#### CONFLICT OF INTEREST

The authors declare that there is no conflict of interest.

#### REFERENCES

1. Yao J-JA, Graf N, Vujanic GM. Nephroblastoma. In: Stefan DC, Rodriguez-Galindo C, editors. Pediatric Hematology- Oncology in Countries with Limited Resources. New York: Springer; 2014. p. 355–64.
2. Vujani GM, Sandstedt B. The pathology of Wilms ' tumour (nephroblastoma) : the International Society of Paediatric Oncology approach. *J Clin Pathol.* 2010;63(2):102–9.
3. Szychot E, Apps J, Pritchard-jones K. Wilms ' tumor : biology , diagnosis and treatment. *Transl Pediatr.* 2014;3(1):12–24.
4. Sari NM, Reniarti L, Suryawan N, et al. Burden of Pediatric Cancer Treatment : Results of Online Pediatric Cancer Registry Prototype 1 at A Third Referral Hospital in Indonesia. *Althea Med J.* 2017;4(3):461–7.
5. Eggi R, Yacobda S. Wilms Tumor in Children : Results from A Large Indonesian Referral Hospital ' s Experience Over 5 Years. *J Med - Clin Res Rev.* 2019;3(5):5–8.
6. Fawkner-corbett DW, Howell L, Pizer BL, et al. Wilms ' tumor — lessons and outcomes — a 25-year single center UK Experinece . *Pediatr Hematol Oncol .* 2014;31(5):400-8.
7. Leslie SW, Sajjad H, Murphy PB. Wilms Tumor (Nephroblastoma). *StatPearls Publ.* 2019;
8. Israels T, Pidini D, Borgstein E, et al. Survival of children with a Wilms tumor in Survival of children with a Wilms tumor in Blantyre , Malawi. *Pediatr Hematol Oncol.* 2018;35(3):196–202.
9. Libes J, Oruko O, Abdallah F, et al. Risk Factors for Abandonment of Wilms Tumor Therapy in Kenya. *Pediatr Blood Cancer .* 2015;62(2):252-256.
10. Wilde JCH, Lameris W, Hasselt EHV, et al. Challenges and outcome of Wilms' tumour management in a resource-constrained setting. *Afr J Paediatr Surg .* 2010;7(3):159-62.
11. Kumar NA, Bezawada S, Chaitanya SV, et al. A Retrospective Study of Wilms Tumour in Our Institute. *Int J Contemp Med Res.* 2016;3(8):2015–7.
12. Abdelmabood S, Kandil S, Megahed A, et al. Delays in diagnosis and treatment among children with cancer : Egyptian perspective. *East Mediterr Heal J.* 2017;23(6):422–9.
13. Njuguna F, Martijn HA, Kuremu RT, et al. Wilms Tumor Treatment Outcomes : Perspectives From a Low-Income Setting. *J Glob Oncol.* 2017;3(5):555–62.
14. Rabeh W, Akel S, Eid T, et al. Wilms tumor : Successes and challenges in management outside of cooperative clinical trials. *Hematol Oncol Stem Cell Ther.* 2016;9(1):20-5.
15. Olukayode AA, Richard IO, Rachael AA, et al. Pattern of computed tomography scan findings in children with Wilms' tumor in a tertiary hospital in Lagos, Nigeria. *Indian J Med Paediatr Oncol.* 2014;35(1):31–5.
16. Bergeron C, Fleet R, Tounkara FK, et al. Lack of CT scanner in a rural emergency department increases inter-facility transfers: a pilot study. *BMC Res Notes.* 2017;10(1):772.
17. Bhagat S, Gauba N, Singh S, et al. Assessment and Comparison of Abdominal Masses by Sonography and Computed Tomography. *J Evol Med Dent Sci.* 2013;3(1):84–94.
18. Otto JH, Janse van Rensburg J, Stones DK. Post-treatment surveillance abdominopelvic computed tomography in children with Wilms tumour: Is it worth the risk? *S Afr J Rad.* 2015;19(1):1–6.
19. Ali Nawaz Khan, MBBS, FRCS, et al. Wilms Tumor Imaging - Ultrasonography [Internet]. *Medscape.* 2019 [cited 2019 Dec 16]. Available from: <https://emedicine.medscape.com/article/415012-overview#a5>
20. Shah SP, Epino H, Bukhman G, et al. Impact of the introduction of ultrasound services in a limited resource setting: rural Rwanda 2008. *BMC Int Health Hum Rights.* 2009;9:4.
21. Brillantino C, Rossi E, Minelli R, et al. Current Role of Imaging in the Management of Children with Wilms Tumor According to the New UMBRELLA Protocol Translational Medicine. *Transl Med.* 2019;8(2):1–16.
22. Aitken JF, Youlden DR, Moore AS, et al. Childhood cancer staging for population registries according to the Toronto Childhood Cancer Stage Guidelines. *Cancer Counc Queensl Cancer Aust Brisbane.* 2017. :33–7.
23. Isowo ABM, Sowunmi AC, Oyeseun AR, et al. Management of Wilm ' s tumor at the Lagos University

- Teaching Hospital ( a 10-year retrospective study ). *J Clin Sci.* 2019;16(2):68–73.
24. Rais F, Benhmidou N, Rais G, et al. Wilms tumor in childhood : Single centre retrospective study from the National Institute of Oncology of Rabat and literature review. *Pediatr Hematol Oncol J.* 2016;1(2):28–34.
25. Lowe LH, Isuani BH, Heller RM, et al. Pediatric Renal Masses: Wilms Tumor and Beyond. *Radiographics.* 2000;20(6):1585–603.
26. Chung EM, Graeber AR, Conran RM. Renal Tumors of Childhood: Radiologic-Pathologic Correlation Part 1. The 1st Decade: From the Radiologic Pathology Archives. *Radiographics.* 2016;36(2):499–522.
27. Soyemi SS, Osuoji RI, Fadayile FA, et al. Morphological Features of Wilms Tumour in a Tertiary Health Care Institution: Our Findings. *J Clin Exp Pathol.* 2013;3(3):1–3.
28. Okello I, Tibenderana R, Lubega A, et al. Wilms tumour among children attending Mbarara Regional Referral Hospital: Clinico-pathological characteristics and outcome at the end of treatment. *East Afr J Surg.* 2019;24(1):28–34.
29. Popov SD, Sebire NJ, Vujanac GM. Wilms' Tumour – Histology and Differential Diagnosis. In: Heuvel-Eibrink MM van den, editor. *Wilms Tumor.* Codon Publications; 2016. p. 3–21.
30. Taskinen S, Leskinen O, Lohi J, et al. Effect of Wilms tumor histology on response to neoadjuvant chemotherapy. *J Pediatr Surg.* 2019;54(4):771–4.
31. Wang J, Li M, Tang D, et al. Current treatment for Wilms tumor: COG and SIOP standards. *World J Pediatr Surg.* 2019;2(3):e000038.
32. Yao AJ, Moreira C, Traoré F, et al. Treatment of Wilms Tumor in Sub-Saharan Africa: Results of the Second French African Pediatric Oncology Group Study. *J Glob Oncol.* 2019;(5):1–8.
33. Dumba M, Jawad N, McHugh K. Neuroblastoma and nephroblastoma: a radiological review. *Cancer Imaging.* 2015;15(1):5.
34. de Sousa Leão LR, Mussi TC, Yamauchi FI, et al. Common pitfalls in renal mass evaluation : a practical guide. 2019;52(4):254–61