

Vildagliptin-Associated Bullous Pemphigoid: A Case Report

Debanjan Roy¹, Gunjan Gayen¹, Sabnam Ara Begum², Sandip Ghosh³, Sucheto Talukder⁴, Arisha Sarkar⁴, Shritama Aich^{5*}

¹Post-Graduate Trainee, Department of Pharmacology, R. G. Kar Medical College and Hospital, Kolkata, India.

²Associate Professor, Department of Pharmacology, R. G. Kar Medical College and Hospital, Kolkata, India.

³Principal, R.G. Kar Medical College and Hospital, Kolkata, India.

⁴Undergraduate Student (M.B.B.S), R.G. Kar Medical College and Hospital, Kolkata, India.

⁵Multidisciplinary Research Unit, R.G. Kar Medical College and Hospital, Kolkata, India.

Abstract

Objective: Bullous pemphigoid is a rare autoimmune skin disorder characterized by blistering, urticarial lesions, which are sometimes associated with adverse drug reactions.

Vildagliptin is an oral anti-diabetic agent that selectively inhibits the dipeptidyl peptidase-4 (DPP-4) enzyme.

Materials and Methods: A 75-year-old female with a known case of type 2 Diabetes Mellitus, hypertension, and hypothyroidism for the last 10 years presented with pruriginous tense bullous skin lesions over her both palms and soles. There was no mucosal involvement. Further interrogation revealed that she started taking Vildagliptin 5 days ago which was prescribed due to high levels of post-prandial blood sugar level despite already intake of Glimpiride-4 mg and Metformin-3 gm.

Results: Vildagliptin was immediately advised to be stopped. She was treated with antihistamines, steroids, and conservative management which led to remission of the blisters.

Conclusion: Vildagliptin is the probable causative drug for developing bullous pemphigoid skin lesion which shows temporal association in this case as other concomitant drugs has no direct correlation. Therefore physicians must be aware of this rare life-threatening side effect of this medicine and advice patients to visit the hospital even the slightest cutaneous manifestation. Bullous pemphigoid can result in fatal life-threatening conditions if not treated early.


Keywords: Autoimmune, Hemidesmosomes, pruriginous, Bullous, Immune-tolerance, Vildagliptin.

QR Code:



Citation: Roy D, Gayen G, Ara Begum S, Ghosh S, Talukder S, Sarkar A et al . Vildagliptin-Associated Bullous Pemphigoid: A Case Report. IJDO 2024; 16 (2) :121-126

URL: <http://ijdo.ssu.ac.ir/article-1-874-en.html>

 10.18502/ijdo.v16i2.15711

Article info:

Received: 24 December 2023

Accepted: 08 April 2024

Published in May 2024



This is an open access article under the (CC BY 4.0)

Corresponding Author:

Shritama Aich, Multidisciplinary Research Unit, R.G. Kar Medical College and Hospital, Kolkata, India.

Tel: (91) 98741-44337

Email: mrurgkarmch@gmail.com

Orcid ID: 0009-0008-7679-0113

Introduction

Bullous pemphigoid is an acquired sub epidermal autoimmune blistering disease that is associated with some medications as well such as Vildagliptin.

Vildagliptin is an oral anti-diabetic drug that is a DPP-4 enzyme inhibitor. It acts by enhancing the secretion of GLP-1 and GIP with food intake, which promotes glucose-dependent insulin secretion and suppresses glucagon secretion causing a lowering of blood glucose levels.

Bullous Pemphigoid (BP) patients have circulating auto-Ab BP 180 and BP 230 which are components of hemi-desmosomes in basal keratinocytes. DPP-4 protein (AKA CD26) is expressed in various kinds of cells including T- Lymphocytes (1). Pathogenesis of DPP-4 inhibition associated BP is unknown but inhibition of CD26 expression on T-cells have certain effects on the immune system (2). Two hypotheses are proposed one shows that DPP-4 inhibition in turn inhibits the CD-26 expression on T-cells which causes infiltration of eosinophils into the skin. The other hypothesis says DPP-4 inhibition can break the immune tolerance of BP-180 which causes alteration of BP-180 metabolism leading to unstable adhesion between dermis and epidermis and ultimately blister formation.

The first nationwide study from Finland revealed a 10-fold elevated risk of bullous pemphigoid after the use of Vildagliptin in case-controlled settings. In that study,

combined therapy of metformin and vildagliptin showed an increased risk of bullous pemphigoid. There were no reports with Metformin alone (3).

A recent French study demonstrated that the observed per capita intake of DPP-4 inhibitors, particularly that of Vildagliptin, was higher in a Cohort Study of 1787 patients with bullous pemphigoid as compared to the general population (4).

Case details

In this case a 75 years old female with known type 2 Diabetes Mellitus, hypertension, and hypothyroidism for the last 10 years was presented to the OPD of R. G. Kar Medical College and Hospital. Also, she had pruriginous tense bullous skin lesion over her both palms and soles. On inspection, it was noted that the lesion had no mucosal involvement. Further interrogation revealed that she started intake of Vildagliptin 5 days ago which was prescribed due to high levels of post-prandial blood sugar level despite previous combined intake of Glimepiride-4 mg and Metformin-3 gm (Table 1).

The images of bullous skin lesions over palms and soles are presented in Figures 1. For Laboratory Diagnosis specimens of intact bulla were collected from the right forearm for Skin Biopsy and Direct Immunofluorescence (Table 2 and Table 3).

The microscopic finding shows fibrin mesh

Table 1. The prescribed drugs with their dosage, frequency, and duration

Drug with dosage	Frequency	Duration
Tab Glimepiride (2 mg)	Twice daily	10 years
Tab Metformin (2000/1000 mg) (2 g after breakfast, 1 g after dinner)	Twice daily	10 years
Tab Cilnidipine (10 mg)	Twice daily	10 years
Tab Levothyroxine (50 µg)	Once daily	10 years
Tab Torsemide (5 mg)	Once daily	5 years
Tab Vildagliptin (50 mg)	Once daily	5 years

with inflammatory cells in the sub-epidermal region, confirming the diagnosis of bullous pemphigoid.

Keeping in mind the history and clinical presentation of the patient along with the skin biopsy and direct immunofluorescence reports,

a diagnosis of bullous pemphigoid was confirmed by the Department of Dermatology, R. G. Kar Medical College and Hospital. The patient was advised to immediately stop Vildagliptin. She was prescribed Tab Levocetirizine-5mg and Tab Prednisolone-

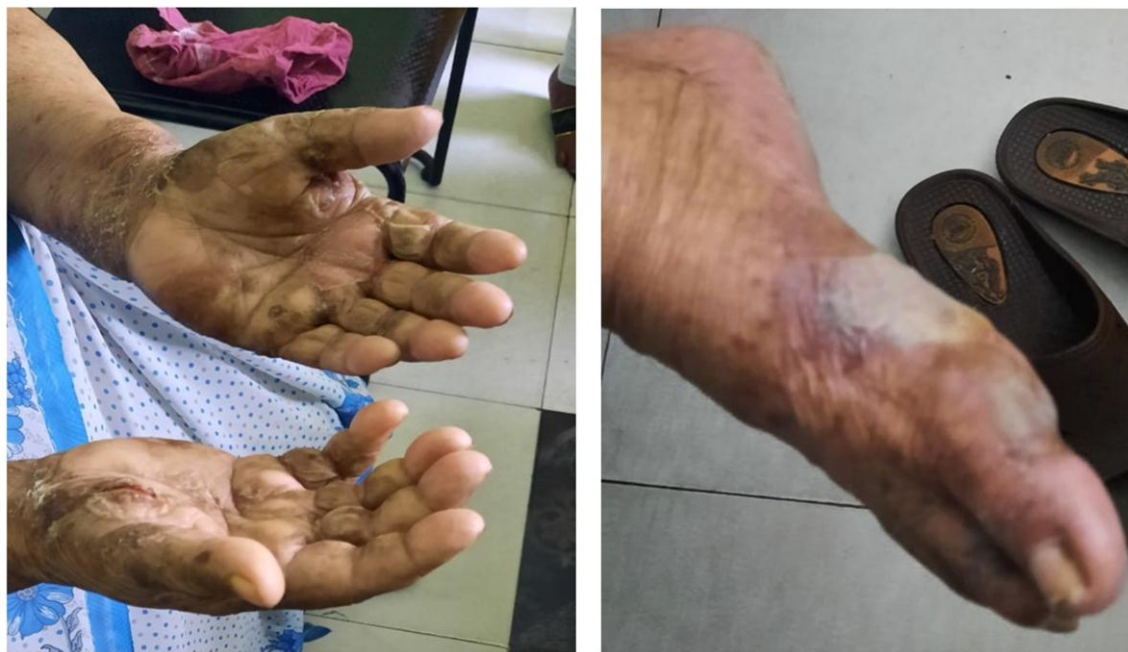

Figure 1. Pruriginous tense bullous skin lesion over both palms and over sole

Table 2. Direct Immunofluorescence. The report shows positive C3 and IgG at the basement membrane zone and negative for IgA and IgM

Specimen	Skin biopsy for Direct Immunofluorescence
Microscopy	C3: Positive, at the basement membrane zone IgG: Weak positive, at the basement membrane zone IgA: Negative IgM: Negative
Comment	Please correlate with the histopathology report (WPC00139)

Table 3. Histological Findings of the patient

Specimen	Skin biopsy was taken from the right forearm, intact bulla.
Grossing	Received punch biopsy of skin measuring 4 mm in diameter.
Microscopy	Sections studied show a bulla in the sub-epidermal region which is filled with fibrin mesh which has few inflammatory cells. No acantholytic cells were seen in the bulla. The stroma shows mixed inflammatory cells in perivascular areas.
Diagnosis	Sub-epidermal bulla, consistent with bullous Pemphigoid.

1mg/kg/day which will lead to remission of the blisters. Although it was HLA predisposition, genotyping was not done. Recovery after being treated is shown in Figure 2.

Ethical considerations

Informed consent has been taken from the patient for reporting her case and all ethical issues have been considered while submitting the case report.

Result

The patient was diagnosed with bullous pemphigoid and Vildagliptin was immediately stopped. She was treated with Tab Prednisolone 1mg/Kg/day and steroid ointment local which led to remission of the blisters. Oral re-challenge test with vildagliptin was not done on ethical grounds but causality assessment was done by both Naranjo and WHO-UMC scale and vildagliptin was found probable category in both.

Discussion

Pemphigoid was 1st described by Lever in 1953, which is a disease characterized by bullous formation due to sub-epidermal detachment (5). There can be differential diagnoses of pemphigus foliaceus, pemphigus herpetiformis, linear IgA bullous dermatosis, eczema, urticaria, and prurigo. The diagnosis of BP was confirmed by Direct immunofluorescence and histopathology confirmed a definitive diagnosis of BP (5). In our case, the oral re-challenge test with vildagliptin was not done on ethical grounds. Causality assessment was done by both Naranjo and WHO-UMC scale and it was found to be a “probable” category in both. According to Vigiacess, a total of 740 cases of vildagliptin-associated bullous pemphigoid have been reported to date. The patient was treated with antihistamines, steroids, and conservative management.

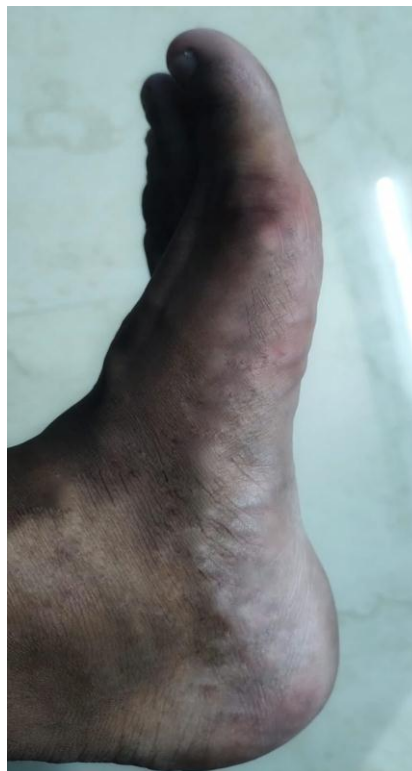

Figure 2. Recovery after treatment

Conclusion

Vildagliptin administration in Diabetes Mellitus patients is the major factor in BP pathogenesis. Presently it is unknown whether all DPP-4 inhibitors possess the same capacity to induce BP or not. The pathogenesis behind this phenomenon is still unknown and needs to be investigated whether Vildagliptin makes individuals vulnerable to BP by disturbing the balance of the immune system or altering the structure of the cutaneous basement membrane. However, we need more information regarding the prognosis of vildagliptin associated with BP, especially for replacing gliptin with other anti-diabetic medications in patients with BP.

Acknowledgments

We thank the Indian Pharmacopoeia Commission for providing a platform to detect and monitor this case as reported.

Funding

The case has been reported from a patient undergoing treatment in a tertiary care government hospital of Kolkata (under the

West Bengal health scheme) and thus no funding was required.

Conflict of Interest

The authors declare no conflict of interest.

Authors' contributions

D. R: conceived and designed the analysis and collected the data.

G. G: performed the analysis and wrote the manuscript.

S. AB: conceived and designed the analysis, performed the analysis and wrote the manuscript.

S. Gh: conceived and designed the analysis and performed the analysis.

S. T and A. S: wrote the initial draft of the manuscript and collected the data.

Sh. A: performed the analysis and collected the data.

All authors have accepted responsibility for the entire content of this manuscript and agreed to be accountable for all aspects of the study and resolved and approved the version to be published.

References

1. Ohnuma K, Dang NH, Morimoto C. Revisiting an old acquaintance: CD26 and its molecular mechanisms in T cell function. *Trends in immunology*. 2008;29(6):295-301.
2. Tasanen K, Varpuluoma O, Nishie W. Dipeptidyl peptidase-4 inhibitor-associated bullous pemphigoid. *Frontiers in immunology*. 2019;10:463593.
3. Varpuluoma O, Försti AK, Jokelainen J, Turpeinen M, Timonen M, Huilaja L, Tasanen K. Vildagliptin significantly increases the risk of bullous pemphigoid: a Finnish nationwide registry study. *Journal of Investigative Dermatology*. 2018; 138(7):1659-61.
4. Plaquevent M, Tétart F, Fardet L, Ingen-Housz-Oro S, Valeyrie-Allanore L, Bernard P, et al. Higher frequency of dipeptidyl peptidase-4 inhibitor intake in bullous pemphigoid patients than in the French general population. *Journal of Investigative Dermatology*. 2019;139(4):835-41.
5. Miyamoto D, Santi CG, Aoki V, Maruta CW. Bullous pemphigoid. *Anais brasileiros de dermatologia*. 2019;94:133-46.