

Comparative Efficacy Study of N-Chromosome Royal Jelly Versus Semelil (ANGIPARS) on Wound Healing of Diabetic Rats

Saeed Ahmadi Majd¹, Mohammad Rabbani Khorasgani^{1*}, Sayed Rasoul Zaker¹,
Maryam Khezri², Azam Aliasghari Veshareh³

¹Department of Cell and Molecular Biology & Microbiology, Faculty of Biological Science & Technology, University of Isfahan, Isfahan, Iran.

²Department of Chemistry, Faculty of Chemistry, University of Isfahan, Isfahan, Iran.

³Department of Microbiology, Faculty of Biological Sciences, Alzahra University, Tehran, Iran.

Abstract

Objective: The healing effects of two different dilutions (5 & 100%) of N-Chromosome Royal Jelly and ANGIPARS ointment were investigated and measured on experimental injuries in streptozotocin (STZ)-induced diabetic rats. This study investigated the healing effects of 2 different N Chromosome Royal Jelly dilutions on injuries of STZ-induced diabetic rats.

Materials and Methods: For diabetes induction, male Wistar rats received STZ (55 mg/kg) intraperitoneally and plasma glucose level measurement after 72 hours demonstrated diabetes induction. Rats were randomly divided into 5 groups of 6 members and one square centimeter (cm²) wound was surgically induced in the dorsal region of each rat. The test groups were treated with ANGIPARS, undiluted royal jelly N chromosome, and royal jelly N chromosome 5% separately. The control groups were including non-diabetic and untreated diabetic rats.

Results: The findings indicate a significant acceleration in wound healing of the diabetic rats treated by ANGIPARS ointment or royal jelly N chromosomes 5%. RJ also shortened the healing period of desquamated skin lesions. Thus, RJ possesses an anti-inflammatory action and is able to augment wound healing, but does not have an insulin-like action in streptozotocin-diabetic rats.

Conclusion: Regarding the mentioned findings, royal jelly as a natural product may play an effective role in treating chronic wounds in mice, which makes it a proper candidate for use in human wound repair. Nonetheless, it seems that determination of the suitable dilution of this compound will result in better effects, thus more studies are recommended.

Keywords: Diabetes mellitus, Wound healing, Natural products, Drug effects

QR Code:



Citation: Ahmadi Majd S, Rabbani Khorasgani M, Zaker S R, Khezri M, Aliasghari Veshareh A. Comparative Efficacy Study of N-Chromosome Royal Jelly Versus Semelil (ANGIPARS) on Wound Healing of Diabetic Rats. IJDO 2022; 14 (4) :223-230

URL: <http://ijdo.ssu.ac.ir/article-1-748-en.html>



10.18502/ijdo.v14i4.11230

Article info:

Received: 18 July 2022

Accepted: 04 October 2022

Published in November 2022



This is an open access article under the (CC BY 4.0)

Corresponding Author:

Mohammad Rabbani Khorasgani, Faculty of Biological Science & Technology, Department of Cell and Molecular Biology & Microbiology, University of Isfahan, Isfahan, Iran.

Tel: (98) 912 327 1873

Email: m.rabbani@biol.ui.ac.ir

Orcid ID: 0000-0002-4043-9216

Introduction

Diabetes mellitus (DM) is a metabolic disorder that is caused by abnormal carbohydrate metabolism due to defects in insulin secretion, insulin action, or both (1,2). Insulin deficiency in turn leads to hyperglycaemia causing disturbances in carbohydrates, fat, and protein metabolism (3,4). Diabetic patients mostly experience foot ulceration problems due to blood vessel and nerve damage (5-7). In diabetic patients who suffer from foot ulcer, normal healing fails to progress thus the lesions change into chronic wound rapidly (8). According to worldwide notice on natural products and traditional remedies, studies on honey have increased since 2007 (9,10). In-vivo, in-vitro, and also clinical studies claimed that treatments inclusively containing honey or combined with herbal ointments or any related chemical compound are efficient in ameliorating leisure healing phases (11). Royal jelly (RJ) is a secretion product of the cephalic glands of nurse bees and serves as the most important part of honeybee larvae diet and plays a main role in caste differentiation (12,13). The major nutrients of RJ are amino acids, vitamins, and minerals. The RJ enjoys various biological activities like hypotensive effect, insulin like action, anti-bacterial and anti-tumor effects as well (14). N-chromosome RJ, the commercial product of a Canadian company Caspian ApiariesTM, is a unique RJ produced by nurse bees for queen cells that have drone larvae grafted into them. In another word, N-chromosome RJ is a mixture of RJ and workers jelly which has significant peptic ulcer healing features (15).

On the other side, Semelil (ANGIPARSTM) is a well-known herbal formulation containing *Melilotus officinalis* extract. It is formulated by Iranian scientists as an effective medicine for diabetic peripheral neuropathy (16) and also for diabetic foot ulcer (17). This comparative study was conducted to measure the efficacy of two different dosages of N-

chromosome RJ versus ANGIPARSTM on STZ-induced diabetic rats.

Materials and Methods

Materials

N-Chromosome RJ was obtained from Caspian Apiaries (Canada). STZ was purchased from Sigma-Aldrich (Germany). ANGIPARS ointment was prepared from Pars Rose Pharmaceutical Company (Iran).

Animals

Adult male Wistar rats weighing between 250-300g were used in the study. The animals were housed in plastic cages at a constant temperature of 23°C ± 1 and 12hours light/dark cycle with ad libitum access to water and food (Pars Company, Tehran, Iran). The animals were randomly divided into five experimental groups (6 rats in each group) including non-diabetic control, diabetic control, ANGIPARS and two groups treated with 100% and 5% N-Chromosome RJ.

STZ induced diabetic rats

Diabetes was induced by a single intraperitoneal (i.p) injection of STZ at a dose of 55 mg/kg body weight. Blood samples were collected and fasting blood glucose levels was measured by a glucometer (Easy Gluco, Germany) after 72h of STZ administration. Animals with fasting blood glucose level over 180 mg/dL were considered diabetic and included in the experiments (18).

Macroscopic wound analysis

Digital photographs of the wound were taken on days 0, 4, 7, and 14. Wound areas were measured using AdobeTM photoshop CS6 software in order to monitor the healing process of the wounds closely on each animal.

Microscopic analysis of wounds

Tissue samples were collected and fixed in 10% buffered formalin. Then, sections of 5µm

thickness were prepared. For histological evaluation, Hematoxylin & Eosin staining was performed (19). All samples were examined by a light microscope.

Statistical analysis

The data were statistically analyzed (One way ANOVA and Tukey's post hoc tests) on Graf Pad Prism 5 software (Graph Pad Software Inc., CA, USA). A *P* of less than 0.05 was considered statistically significant.

Ethical considerations

This article is the result of a thesis with a proposalcode 92/14530 that approved by department of cell and molecular biology & microbiology, university of Isfahan.

Results

Wound areas on day 7 of the study in different groups

The average wound area in the healthy

control group was $78.814 \pm 9.744 \text{ mm}^2$. The average wound area in the diabetic control group was $170.050 \pm 57.876 \text{ mm}^2$. The average area of the wound in the treatment groups including N-chromosome royal jelly (pure), N-chromosome royal jelly 5% and ANGIPARS was 208.908 ± 7.678 , 47.754 ± 7.570 and $40.572 \pm 1.955 \text{ mm}^2$, respectively. Statistical analysis shows that the difference in the average area of the wound in the diabetic control group and the healthy control group is significant ($P < 0.05$). Also, the average area of the wound shows a significant difference between the treatment groups and the diabetic control group ($P < 0.05$), But this value is not significantly different between the healthy control groups, N-chromosome royal jelly (5%) and ANGIPARS ($P < 0.05$). On the 7th day, the N-chromosome royal gel (pure) group has the largest wound area, and the ANGIPARS group has the least wound area (Figure 1 & 2).

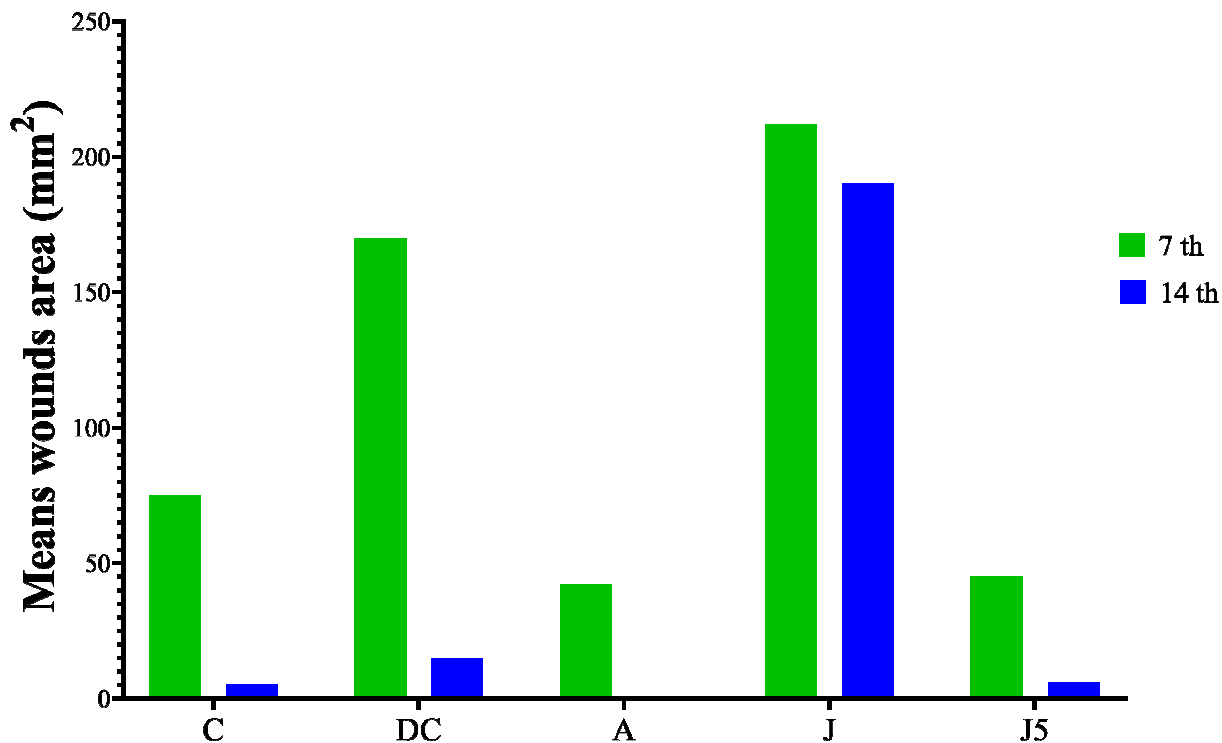


Figure 1. Wound areas in different groups on days 7th and 14th. C: nondiabetic control; DC: diabetic control; A: Angi Pars; J: N-Chromosome RJ; J5: 5% N-Chromosome RJ

Wound areas on day 14 of the study in different groups

The average wound area in the healthy control group was 1.766 ± 0 mm². Also, the average wound area in the diabetic control group was 22.078 ± 3.181 mm². The average area of the wound in the treatment groups including N-chromosome royal jelly (pure), N-chromosome royal jelly 5% and ANGIPARS was 189.503 ± 7.163 , 4.579 ± 2.175 and 0 mm², respectively. Statistical analysis shows that the difference in the average area of the wound in the diabetic control group and treatment groups is significant ($P < 0.05$), But this value is not significantly different between the healthy control groups, N-chromosome royal jelly (5%) and ANGIPARS ($P < 0.05$) (Figure 1& 2).

Histopathological examination of wounds in ANGIPARS group

In the treatment group with ANGIPARS, after 7 days, the epidermis layer is not repaired, and the sample has a gap. After 14 days of treatment with ANGIPARS, the epidermal layer has been completely restored

so that it is almost similar to the healthy tissue. The area of the dermis in the ANGIPARS group on the 7th day is less than the N-chromosome royal jelly group and the diabetic control group, and on the 14th day, it has the smallest area compared to the other groups (Figure 3,4,5).

Histopathological examination of wounds in N-chromosome royal jelly group

In the treatment group with N-chromosome royal jelly, after 7th day the epidermis layer is not repaired, and the sample has a gap. After 14 days of treatment with N-chromosome royal jelly, the epidermis layer has not yet been repaired and the effects of the wound are observed. The area of the dermis in this group on the 7th day is not significantly different compared to the healthy control, but it is smaller than the diabetic control. The N-chromosome royal jelly group has the largest area in the dermis area on the 14th day compared to other groups (Figure 3,4,5).

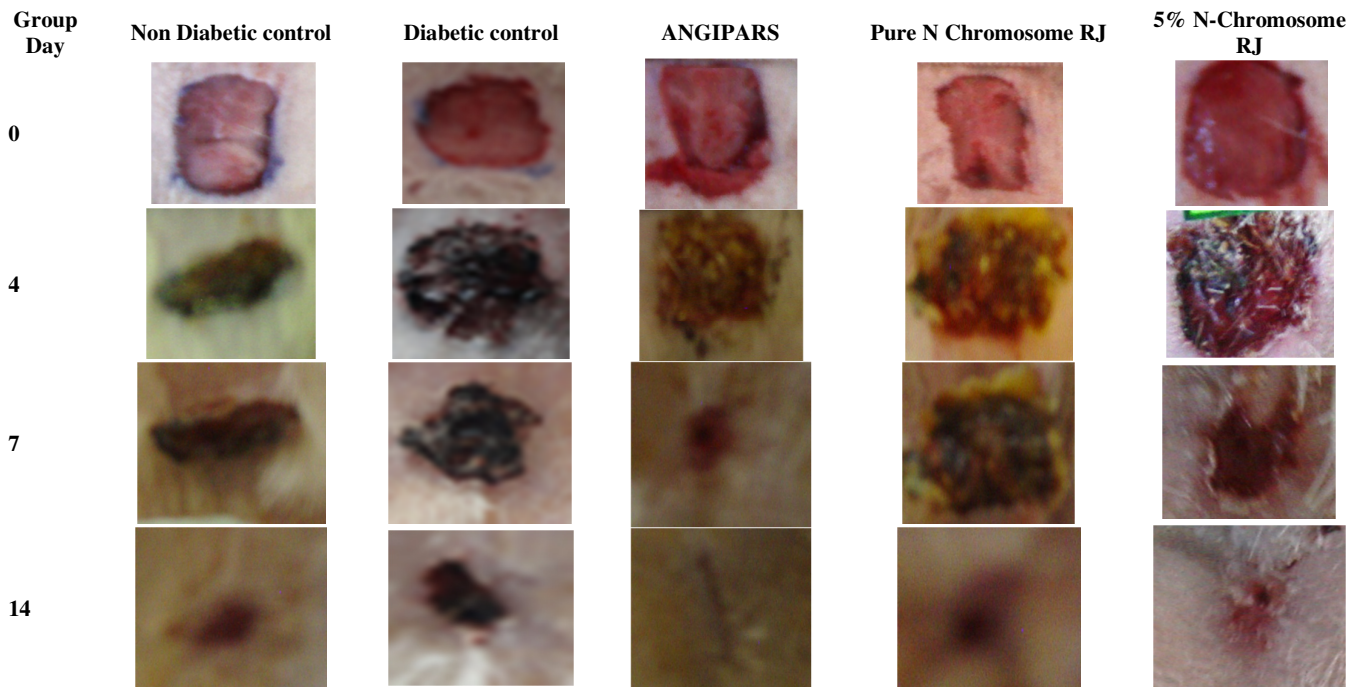


Figure 2. Photographs of macroscopic appearances of the excised wounds from rats that were untreated (control), treated with N-Chromosome RJ, and 5% N-Chromosome RJ in days 0, 4, 7 and 14.

Histopathological examination of wounds in N-chromosome royal jelly (5%) group

In the treatment group with N-chromosome royal jelly (5%), after 7th day the epidermis layer is not repaired, and the sample has a gap. After 14 days of treatment with N-chromosome royal jelly (5%), the epidermis layer has not yet been repaired and the sample has a gap. The dermis area in this group on the seventh day has the lowest area compared to other groups. The N-chromosome royal jelly (5%) group has a smaller area in the dermis than the N-chromosome royal jelly group on

the 14th day (Figure 3-4-5).

Discussion

The mechanism by which ANGIPARS™ is effective in wound healing is due to the chemical content of *Melilotus officinalis* (yellow sweet clover). The most abundant biologically active substances are kaempferol, quercetin glycosides and triterpene saponins. One of the supposed mechanisms of action of the herb is associated with increase of venous return and lymphatic flow (20). Previous studies have investigated the healing effect of N-chromosome RJ on the wound (21) some

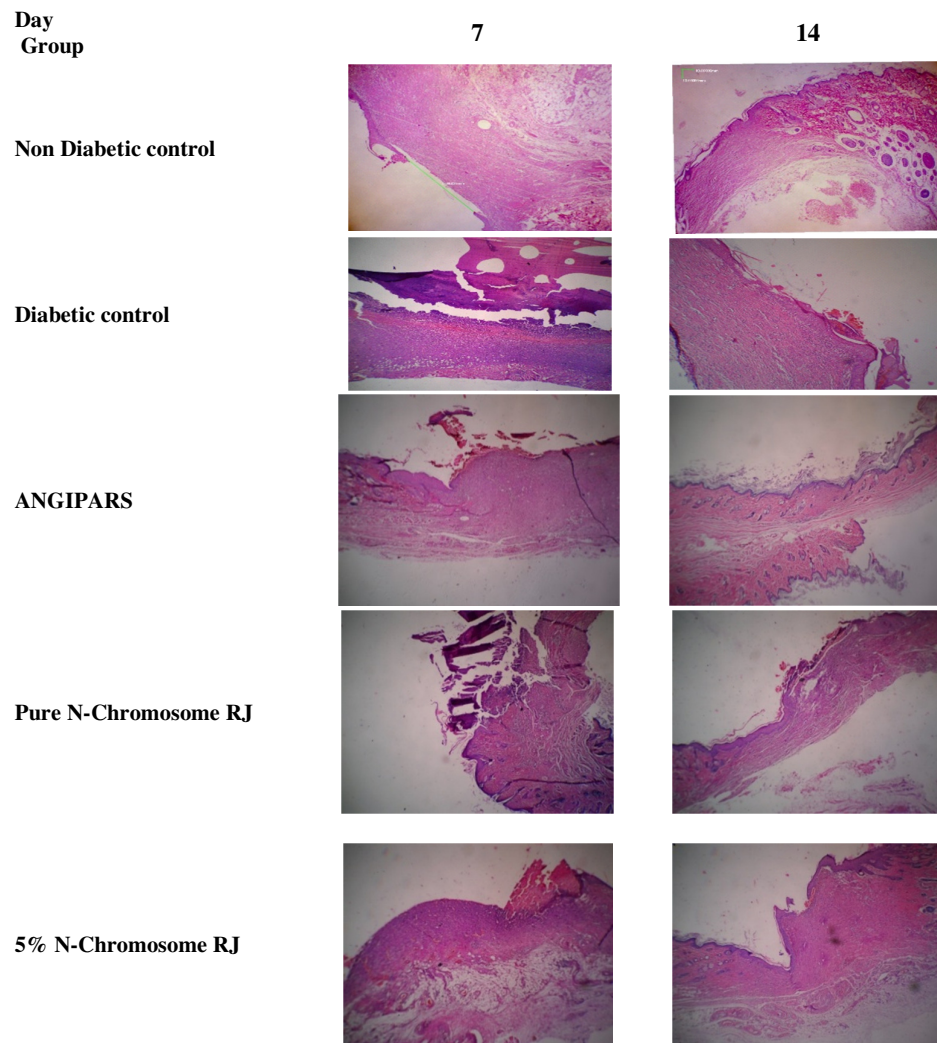


Figure 3. Histological study of wound healing in different groups: Non Diabetic control, Diabetic control, ANGIPARS, N-Chromosome RJ and 5% N-Chromosome RJ.

case is briefly mentioned here:

Siavash et al. (22) studied the efficacy of RJ on treatment of diabetic foot ulcers in patients referring to Khorshid hospital in Isfahan. The results obtained from this study were indicative of the positive impact of 5% RJ on wound repair process acceleration in patients under treatment. Abdollatif et al. (23) evaluated the effects of application of

PedyPhar ointment (a new ointment which is prepared from RJ and panthenol) in treating patients affected by diabetic foot ulcers infections. Sixty patients with diabetic foot infection threatening the limb were separated into three groups based on lesion severity: group one had an ulcer with the whole skin area, group two had deep tissue infection suspect of osteomyelitis, and group three had

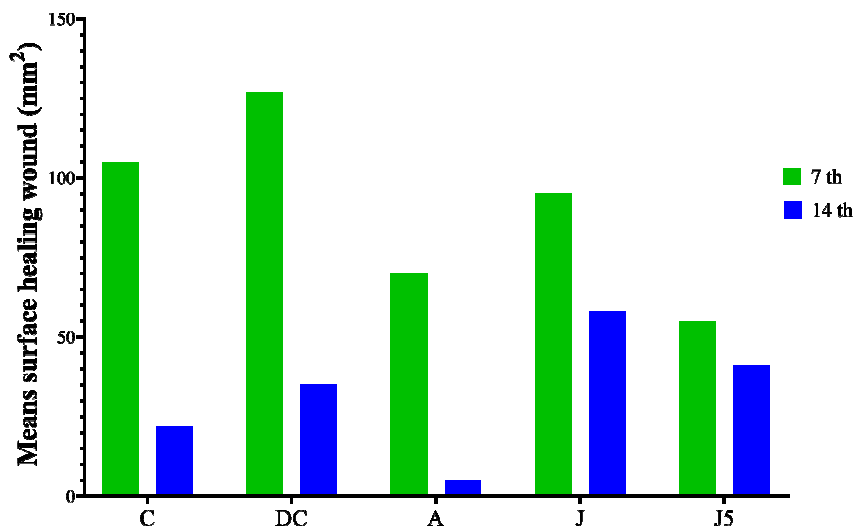


Figure 4. Healing wound Surface of dermis in the study groups at day 7th and 14th. C: non diabetic control; DC: diabetic control; A: Angi Pars; J: N-Chromosome RJ; J5: 5% N-Chromosome RJ.

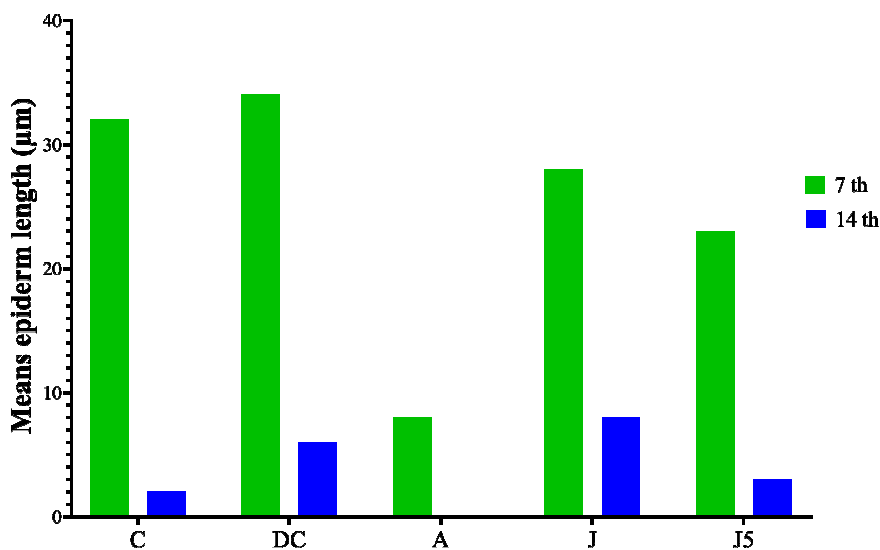


Figure 5. Length of epiderm gap in the study groups at day 7 and 14. C: non diabetic control; DC: diabetic control; A: ANGI-PARS; J: N-Chromosome RJ; J5: 5% N-Chromosome RJ.

gangrenous lesions. All the patients went under treatment by PedyPhar ointment for 6 months after rinsing and cleaning the wound by saline solution. 96% of patients in groups 1 and 2 were completely cured at the end of week 9 and all the patients of group 3 got cured with surgical cutting and debridement of necrotic tissue and preservative treatment by PedyPhar ointment.

Conclusions

This study has shown the difference in healing effects of two different dilutions, in which the 5% N-Chromosome RJ could be helpful while pure form did not lead to an expected decrease of wound size compared to non-treatment diabetic control. The other result of this study indicates that ANGIPARS

ointment is more effective than 5% N-chromosome RJ.

Acknowledgments

This project was financed by the Office of Research Vice Chancellor of University of Isfahan, which authors appreciate them.

Funding

This work was supported financially by University of Isfahan, Iran.

Conflict of Interest

The authors declare that they have no conflict of interest.

References

1. Armstrong DG, Boulton AJ, Bus SA. Diabetic foot ulcers and their recurrence. *New England Journal of Medicine*. 2017;376(24):2367-75.
2. American Diabetes Association. Diagnosis and classification of diabetes mellitus. *Diabetes Care*. 2013;36 Suppl 1(Suppl 1):S67-74. <https://www.ncbi.nlm.nih.gov/pmc/articles/PMC3537273/>.
3. Dilworth L, Facey A, Omoruyi F. Diabetes mellitus and its metabolic complications: the role of adipose tissues. *International Journal of Molecular Sciences*. 2021;22(14):7644.
4. Chawla A, Chawla R, Jaggi S. Microvascular and macrovascular complications in diabetes mellitus: distinct or continuum? *Indian journal of endocrinology and metabolism*. 2016;20(4):546-51.
5. Houreld NN. Shedding light on a new treatment for diabetic wound healing: a review on phototherapy. *The Scientific World Journal*. 2014.
6. Gonzalez AC, Costa TF, Andrade ZD, Medrado AR. Wound healing-A literature review. *Anais brasileiros de dermatologia*. 2016;91:614-20.
7. Pendsey SP. Understanding diabetic foot. *International journal of diabetes in developing countries*. 2010;30(2):75.
8. Iraj B, Khorvash F, Ebnesahidi A, Askari G. Prevention of diabetic foot ulcer. *International journal of preventive medicine*. 2013;4(3):373-6.
9. Naves CC. The diabetic foot: a historical overview and gaps in current treatment. *Advances in wound care*. 2016;5(5):191-7.
10. Khosravi F. A Brief Review about the Effect of Honey on Diabetic Foot Ulcer; from In Vitro Studies to Clinical Trials. *Research Journal of Pharmacognosy*. 2019;6(3):85-91.
11. Erejuwa OO. Effect of honey in diabetes mellitus: matters arising. *Journal of diabetes & metabolic disorders*. 2014;13(1):1-4.
12. Fratini F, Cilia G, Mancini S, Felicioli A. Royal Jelly: An ancient remedy with remarkable antibacterial properties. *Microbiological research*. 2016;192:130-41.
13. Zhang S, Shao Q, Geng H, Su S. The effect of royal jelly on the growth of breast cancer in mice. *Oncology letters*. 2017;14(6):7615-21.
14. Shidfar F, Jazayeri S, Mousavi SN, Malek M, Hosseini F, Khoshpey B. Does supplementation with royal jelly improve oxidative stress and insulin resistance in type 2 diabetic patients?. *Iranian journal of public health*. 2015;44(6):797.
15. Suemaru K, Cui R, Li B, Watanabe S, Okihara K, Hashimoto K, et al. Topical application of royal jelly has a healing effect for 5-fluorouracil-induced experimental oral mucositis in hamsters. *Methods and findings in experimental and clinical pharmacology*. 2008;30(2):103-6.
16. Bakhshayeshi S, Madani SP, Hemmatabadi M, Heshmat R, Larijani B. Effects of Semelil (ANGIPARS (TM)) on diabetic peripheral neuropathy: A randomized, double-blind Placebo-controlled clinical trial. *Daru*. 2011;19(1):65.
17. Ranjbar H. Overview of diabetic foot; novel treatments in diabetic foot ulcer. *DARU Journal of Pharmaceutical Sciences*. 2008;16(Suppl. 1):1-6.
18. Mostafavinia A, Amini A, Ghorishi SK, Pouriran R, Bayat M. The effects of dosage and the routes of

- administrations of streptozotocin and alloxan on induction rate of type 1 diabetes mellitus and mortality rate in rats. *Laboratory animal research*. 2016;32(3):160-5.
19. Suzuki Y, Imada T, Yamaguchi I, Yoshitake H, Sanada H, Kashiwagi T, et al. Effects of prolonged water washing of tissue samples fixed in formalin on histological staining. *Biotechnic & Histochemistry*. 2012;87(4):241-8.
 20. Masoompour SM, Bagheri MH, Novitsky YA, Sadeghi B, Gharibdoust F, Larijani B. Effect of ANGI-PARS, a new herbal drug on diabetic foot ulcer: A phase 2 clinical study. *DARU Journal of Pharmaceutical Sciences*. 2008;16(Suppl. 1):31-4.
 21. Shirzad M, Kordyazdi R, Shahinfard N, Nikokar M. Does Royal jelly affect tumor cells?. *Journal of HerbMed Pharmacology*. 2013;2(2).
 22. Siavash M, Shokri S, Haghighi S, Mohammadi M, Shahtalebi MA, Farajzadehgan Z. The efficacy of topical Royal Jelly on diabetic foot ulcers healing: A case series. *Journal of research in medical sciences: the official journal of Isfahan University of Medical Sciences*. 2011;16(7):904.
 23. Abdelatif M, Yakoot M, Etmaan M. Safety and efficacy of a new honey ointment on diabetic foot ulcers: a prospective pilot study. *Journal of wound care*. 2008 ;17(3):108-10.