

## CASE PRESENTATION

Iran J Allergy Asthma Immunol

April 2019; 18(2):225-229.

# A Rare Case of Hyper IgE Syndrome with Vocal Cords Involvement

Samin Sharafian<sup>1</sup>, Masoud Movahedi<sup>2</sup>, Arash Kalantari<sup>3</sup>, Nima Parvaneh<sup>2</sup>, and Mohammad Gharagozlou<sup>2</sup>

<sup>1</sup> Department of Allergy and Clinical Immunology, School of Medicine, Bushehr University of Medical Sciences, Bushehr, Iran

<sup>2</sup> Department of Allergy and Clinical Immunology, Children's Medical Center, Tehran University of Medical Sciences, Tehran, Iran

<sup>3</sup> Department of Allergy and Clinical Immunology, Vali e Asr Hospital, Imam Khomeini Hospital Complexes, Tehran University of Medical Sciences, Tehran, Iran

Received: 25 January 2018; Received in revised form: 1 July 2018; Accepted: 4 July 2018

## ABSTRACT

Hyperimmunoglobulin E syndrome (HIGE) is considered as a phagocytic or a newly classified complex and heterogeneous primary immunodeficiency disease with symptoms such as increased levels of immunoglobulin E, eczema, and recurrent lung and skin infections. In this paper, we have presented a rare case of this syndrome.

A 9-year-old Iranian girl presented with a history of pruritic maculopapular rash who was eventually diagnosed as a case of HIGE. In her recent admission, she had dysphonia, stridor and huge cauliflower cutaneous lesions on her neck, finger and vocal cords, which did not respond to intravenous antibiotics, and ultimately required surgical removal.

**Keywords:** Cauliflower; Hyperimmunoglobulin E syndrome; Immunodeficiency; Lesions

## INTRODUCTION

Hyper IgE (HIGE) syndrome also known as Jobs syndrome is a rare Primary immunodeficiency disease that was first introduced in 1986 by Davis et al<sup>1</sup> with the annual incidence of less than 1/1,000,000.<sup>2</sup> Affecting men and women equally<sup>3,3</sup> it is characterized by high IgE level, eczema and recurrent bacterial, viral and fungal infections of lung and the skin<sup>4,4</sup>

The IgE levels are typically higher than 2,000

IU/mL and are frequently accompanied by skin infections. The disorder has two different forms, namely autosomal recessive and dominant.

Three genetic etiologies of HIGE have been identified: signal transducer and activator of transcription 3 (STAT3), dedicator of cytokinesis 8 (DOCK8), and tyrosine kinase 2 (Tyk2) with distinct clinical manifestations. Mutations in STAT3 are manifested mostly with skin, skeletal and vascular abnormalities. The main clinical manifestations of the disease include coarse facial, eczema, delayed tooth loss, osteoporosis, excessive flexibility of the joints, short stature and frequent bacterial infections of the skin and lungs.<sup>5</sup> DOCK8 deficiency is characterized by severe cutaneous viral infections such as warts, and a predisposition to malignancies at a young age.<sup>6</sup>

---

**Corresponding Author:** Mohammad Gharagozlou, MD; Department of Allergy and Clinical Immunology, Children's Medical Center, Tehran University of Medical Sciences, Tehran, Iran. Tel: (+98 21) 6147 2153, Fax: (+98 21) 6692 9234, E-mail: gharagoz@tums.ac.ir

In these patients, IgE level is more than normal which may reduce or even return to normal level over time. Other immunoglobulin levels including IgM, IgG, and IgA are usually normal.<sup>7</sup> This group of patients is more susceptible to viral skin infections such as herpes zoster, herpes simplex, molluscum contagiosum, human papillomavirus and autoimmune disease, including autoimmune hemolytic anemia. They also have a high rate of neurologic problems such as encephalitis.<sup>4</sup> An early onset of cutaneous cancers due to viral infections are an important cause of death in these patients.<sup>8</sup> Moreover, arteriovenous malformations such as coronary artery aneurysms and/or malignancies such as lymphoma and leukemia have been reported in these patients. The management of this syndrome is supportive and antibiotics are the primary treatment.<sup>1</sup> Human stem cell transplantation (HSCT) is the treatment choice for an autosomal recessive patient but it has been variably successful in the autosomal dominant forms.

Although the skins involved with dermatitis, molluscum contagiosum, and furunculosis were reported in HIES patients; to the best of our knowledge, no case of cauliflower lesions on the vocal cords, back of the neck and the fingers of the patients have ever been reported.

### CASE PRESENTATION

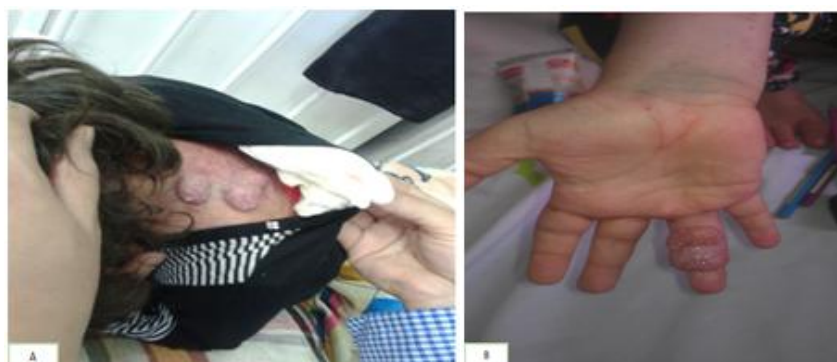A 9-year-old Iranian girl from a relevant parent was admitted with a history of pruritic maculopapular rash since early months of life without responding to the usual treatment regimen. She had episodes of hospitalizations due to upper and lower respiratory

infections, acute otitis media, mucocutaneous candidiasis, and asthma. She was diagnosed as a case of hyper IgE syndrome in infancy. Informed consent was obtained from the patient.

The patient's manifestations included: short stature, stridor since 6 months before the recent admission, wheezing and respiratory distress, dysphonia, severe eczema and huge cauliflower lesions on the back of her neck and fingers which not only did not respond to intravenous antibiotics but also increased in sizes (Figure 1 and 2). The lesions had pussy discharge. She did not have any dental or skeletal involvement such as bone fracture, scoliosis or neurological problems.

Laryngobronchoscopy was done for her and similar lesions were seen on the vocal cords (Figure 3) which were not removable due to severe local adhesion. A complete assessment including immunological tests was performed. Molecular genetic testing confirmed mutation in the DOCK8 gene and diagnosis of HIGE. The patient underwent treatment with antibiotics, intravenous immunoglobulin (IVIG) for the treatment of recurrent infections, proper skin care and management of asthma.

Laboratory findings showed normal flow cytometry and, an evaluation of IgE to 11000 (IU/mL). Skin biopsy revealed angiolymphoid hyperplasia with eosinophilia in fingers and pseudoepitheliomatous hyperplasia in the neck lesions. The lesions' pus and exudate culture showed *Staphylococcus aureus*, which was sensitive to vancomycin and clindamycin. The result of the PCR test was positive for HSV viral load but negative for HPV. Chest x-ray revealed hyperaeration without the evidence of pneumatocele and pneumonia.



**Figure 1. Wart-like skin lesion on the back of neck (A) and finger (B) of a 9-year-old girl with hyper IgE syndrome**

A Rare Case of Hyper IgE Syndrome with Vocal Cords Involvement

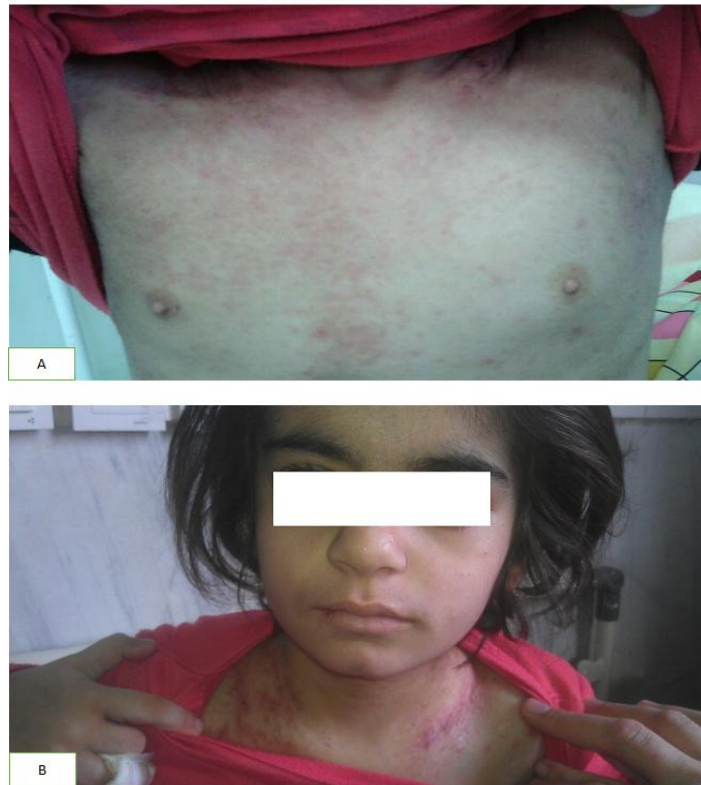

Figure 2. Eczematous lesions (A, B) in a 9-year-old girl with hyper IgE syndrome

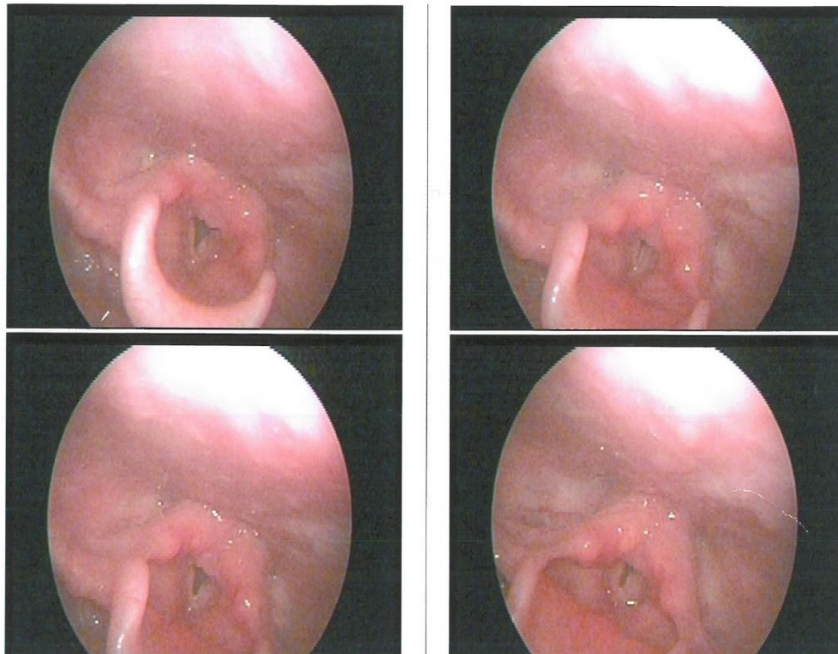


Figure 3. The huge cauliflower lesions on vocal cords of a 9-year-old girl with hyper IgE syndrome

## DISCUSSION

HIES is a complex disorder that affects various parts of the body including the immune system, bones, teeth, and connective tissues. It is known by demonstrations such as dermatitis, recurrent infections and increased level of serum IgE (usually above 2000 IU/mL). The main treatment of this syndrome is long-term antibiotic therapy. IVIG may decrease the frequency of infections.<sup>5</sup> In most cases, autosomal dominant mutations have been reported in gene STAT3 (Signal transducer and activator of transcription 3) however, mutations or deletions in genes DOCK8 (dedicator of cytokinesis 8) and TYK2 (tyrosine kinase 2) have been reported to be in the autosomal recessive form of the disease).<sup>9</sup> HIES should be differentially diagnosed from the other disorders such as Wiskott-Aldrich syndrome, atopic dermatitis, Netherton syndrome and severe combined immunodeficiency.<sup>10</sup>

In this paper, we presented a patient whose lesions had not been observed in any other HIES patient ever referred to our center. At first, it seemed that the lesions were huge warts, but further investigations did not confirm our initial conjecture and later we thought they were probable complications of bacterial infection. Therefore for the management of stridor, respiratory distress, eczema, and skin infection, the treatment was launched by vancomycin, acyclovir, nebulize of epinephrine and salbutamol, topical mupirocin and eucerin ointment. Respiratory symptoms improved with the mentioned treatment, but because of poor response of the skin lesions, surgery was considered to remove them.

No report has ever been received on the vocal cords involvement, negative HPV in wart smear, and negative HPV viral load of PCR test in patients with HIES. Accordingly, it is required to report these different and unusual manifestations in all patients, especially the ones with rare diseases such as HIES. Interestingly, the aforementioned issues disappeared upon applying antibiotics and epinephrine nebulizer. Moreover, advanced technologies in genetic diagnostic could be helpful to timely diagnosis of these diseases.

As the findings of the skin biopsy showed, angiolymphoid hyperplasia with eosinophilia (ALHE) was observed in the fingers of the patient. The development of benign vascular proliferative lesions (mainly in head and neck) accompanying with eosinophils infiltration are considered as the hallmark

of ALHE.<sup>10</sup> The high level of IgE was not usually found in patients with ALHE.<sup>11</sup> The interesting point was the presence of this disorder in this patient. Kimura disease as a scarce benign inflammatory disorder develops similar symptoms with ALHE(10). The main features of Kimura diseases include peripheral eosinophilia and a high concentration of total IgE. The etiology of these two diseases is unknown.<sup>12</sup>

However, the role of hematopoietic stem cell transplant (HSCT) remains unclear, the recent advances expand our understanding of HIES, and improve the diagnostics and clinical care of this rare immunodeficiency disease. According to recent studies, the only way to cure our patient may be HSCT,<sup>8</sup> but a suitable HLA-matched donor has not yet been found for her. In the case of HIES patients, we still need additional studies to evaluate susceptibility to infections and other complications. In addition, it is required to investigate that the cauliflower lesions observed in our patients were directly related to the disease or resulted from the complications.

## ACKNOWLEDGEMENTS

We thank our patient and his parents a great deal for their utmost cooperation . .

## REFERENCES

1. Yong PF, Freeman AF, Engelhardt KR, Holland S, Puck JM, Grimbacher B. An update on the hyper-IgE syndromes. *Arthritis Res Ther* 2012; 14(6):228.
2. Buckley RH, Wray BB, Belmaker EZ. Extreme hyperimmunoglobulinemia E and undue susceptibility to infection. *Pediatrics* 1972; 49(1):59-70.
3. Grimbacher B, Belohradsky BH, Holland SM. Immunoglobulin E in primary immunodeficiency diseases. *Allergy* 2002;57(11):995-1007.
4. Freeman AF, Holland SM. The hyper-IgE syndromes. *Immunol Allergy Clin North Am* 2008; 28(2):277-91.
5. Grimbacher B, Holland SM, Gallin JI, Greenberg F, Hill SC, Malech HL, et al. Hyper-IgE syndrome with recurrent infections--an autosomal dominant multisystem disorder. *N Engl J Med*. 1999; 340(9):692-702.
6. Freeman AF, Holland SM. Clinical manifestations of hyper IgE syndromes. *Dis Markers*. 2010; 29(3-4):123-30.
7. Renner ED, Puck JM, Holland SM, Schmitt M, Weiss M,

## A Rare Case of Hyper IgE Syndrome with Vocal Cords Involvement

- Frosch M, et al. Autosomal recessive hyperimmunoglobulin E syndrome: a distinct disease entity. *J Pediatr* 2004; 144(1):93-9.
8. Szczawinska-Poplonyk A, Kycler Z, Pietrucha B, Heropolitanska-Pliszka E, Breborowicz A, Gerreth K. The hyperimmunoglobulin E syndrome--clinical manifestation diversity in primary immune deficiency. *Orphanet J Rare Dis* 2011; 6:76.
  9. Farmand S, Sundin M. Hyper-IgE syndromes: recent advances in pathogenesis, diagnostics and clinical care. *Curr Opin Hematol* 2015; 22(1):12-22.
  10. Chitrapu P, Patel M, Readinger A, Menter A. Angiolymphoid hyperplasia with eosinophilia. *Proceedings (Baylor University Medical Center)*. 2014;27(4):336-7.
  11. Thompson LD. Angiolymphoid hyperplasia with eosinophilia. *Ear Nose Throat J* 2015; 94(10-11):443-4.
  12. Guo R, Gavino ACP. Angiolymphoid Hyperplasia With Eosinophilia. *Archives of Pathology & Laboratory Medicine*. 2015;139(5):683-6.