

CASE REPORT

Iran J Allergy Asthma Immunol

October 2020; 19(5):550-554.

Doi: 10.18502/ijaa.v19i5.4473

A Case of Linear IgA Bullous Dermatitis Induced by Aspirin Therapy

Mohammad Nabavi¹, Afshin Rezaeifar¹, Ali Sadeghinia², Saba Arshi¹, Sima Bahrami¹,
Mohammad Hassan Bemanian¹, Morteza Fallahpour¹, Sima Shokri¹, and Zahra Vakilzad¹

¹ Department of Allergy and Clinical Immunology, Iran University of Medical Sciences, Tehran, Iran

² Department of Dermatology, Razi Hospital, Tehran University of Medical Sciences, Tehran, Iran

Received: 16 February 2020; Received in revised form: 29 August 2020; Accepted: 7 September 2020

ABSTRACT

Linear IgA bullous dermatosis (LABD) is a rare autoimmune blistering disease that may be triggered by some diseases and medications. For the latter one, non-steroidal anti-inflammatory drugs (NSAIDs) have been identified as one of the potential causative agents to develop LABD. Here, a rare case of drug-induced LABD is introduced. A 13-month-old Iranian boy presented with a history of generalized blisters, displaying the classic “string of pearls” sign who was eventually diagnosed as a case of LABD. In his admission, he was diagnosed with Mucocutaneous lymph node syndrome and treated with aspirin. Some features like appearing the characteristic lesions one week following the administration of aspirin, rapid clearance of lesions after the withdrawal of the drug, and reappearance of new lesions after readministration of aspirin were highly suggestive of aspirin-induced LABD. To establish the diagnosis, we used the “Naranjo probability score” which determined the probable causative role of aspirin. The diagnosis was confirmed by showing the positive IgA deposition in the basement membrane zone in a direct immunofluorescence study of the skin biopsy. The child was treated with dapsone with dramatical response to the drug.

Keywords: Aspirin; Dapsone; Linear IgA bullous dermatosis; Mucocutaneous lymph node syndrome

INTRODUCTION

Linear IgA bullous dermatosis (LABD) is a rare skin bullous condition in young children and adults. The causes of LABD are unknown, it is considered to be an autoimmune disease. Certain medications can cause LABD. In these cases, the blisters appear after starting the medication and disappear after stopping it.

Other reported causative diseases include some systemic autoimmune and non-autoimmune diseases.¹⁻⁶ Patients have itchy tense blisters with a clear fluid, often arranged in clusters or rings so-called “cluster of jewels”, “string of pearls” affecting the skin with occasional mucosal involvement. The diagnosis is usually confirmed with a skin biopsy. Special staining and direct immune fluorescence (DIF) show the deposition of the IgA in the skin along the basement membrane zone (BMZ).¹⁻⁶

The treatment of choice is dapsone with the main adverse effects of methemoglobinemia and hemolytic anemia. Other treatments include systemic and topical

Corresponding Author: Afshin Rezaeifar, MD;
Department of Allergy and Clinical Immunology, Iran University
of Medical Sciences, Tehran, Iran. Tel: (+98 21) 6655 4933,
E-mail: Rezaeifar.a@iums.ac.ir

Linear IgA Bullous Dermatitis Following Aspirin Therapy

corticosteroids, sulfapyridine, colchicine, antibiotics like dicloxacillin, oxacillin, trimethoprim/sulfamethoxazole, flucloxacillin, erythromycin, Immunosuppressants like cyclophosphamide, cyclosporine, mycophenolate mofetil and intravenous immunoglobulin (IVIG) taken in patients who fail to respond to the above-mentioned drugs.¹⁻⁸

In the medical literature, there are only a few case reports regarding the role of non-steroidal anti-inflammatory drugs (NSAIDs) in the pathogenesis of LABD.³ We report a new case of drug-induced LABD following the administration of aspirin.

CASE REPORT

A 13-month-old boy was referred to the clinic of Allergy and Immunology with a generalized blistering skin eruption. He was diagnosed as atypical mucocutaneous lymph node syndrome according to a history of high fever lasting for 10 days associated with non-purulent conjunctivitis, ESR=57, CRP=20, and dilated mild right coronary artery (RCA) and left coronary artery (LCA) without aneurysm in echocardiography. The patient was treated with high dose aspirin (80 mg/kg) and IVIG and discharged with daily use of low dose aspirin (5mg/kg) and recommended for a two-week follow-up visit.

One week after the administration of aspirin, the patient started to develop generalized eruption as grouped tense blisters, localized initially in the perineum and testis and progressed to the trunk, face, and extremities. Several vesicles were seen at the edge of the annular lesion, representing the classic “string of beads” sign (Figure 1A and B). Palmar and plantar

surfaces were not involved. There was no report of any mucosal involvement including eyes. Aspirin was discontinued as a possible culprit agent.

Medical history and clinical examination ruled out the presence of common triggers of erythema multiform such as herpes virus infection. Tzank smear showed many neutrophils and some histiocytes without any pieces of evidence of herpes virus infection. Differential blood count was normal except thrombocytosis (possibly due to previous mucocutaneous lymph node syndrome in the sub-acute period) without neutrophilia or eosinophilia. There was no change in liver function parameters. Serum levels of immunoglobulins including IgA were within normal limits. A skin biopsy was taken from a trunk lesion and in histopathological examination showed subepidermal bullae with predominantly eosinophils and some neutrophils entrapped in a fibrin network associated with perivascular lymphocytic infiltration and some interstitial eosinophils (Figure 2 A, B and C). DIF examination demonstrated linear deposits of IgA along the BMZ, without IgG and C3 deposits, consistent with a diagnosis of Linear IgA bullous dermatosis.

The child was treated with topical corticosteroid and dapsone (0.5 mg/kg/day) after measuring of glucose-6-phosphate dehydrogenase activity and slowly increased until 2 mg/kg/day. The characteristic lesions of LABD began to regress dramatically in one week. The target lesions improved soon with some remaining post-inflammatory hyperpigmentations (PIH) (Figure 1C). Dapsone, 2 mg/kg daily, is well tolerated by the patient and continued despite clearance of all lesions to prevent any possible relapse of the lesions (Figure 1D).

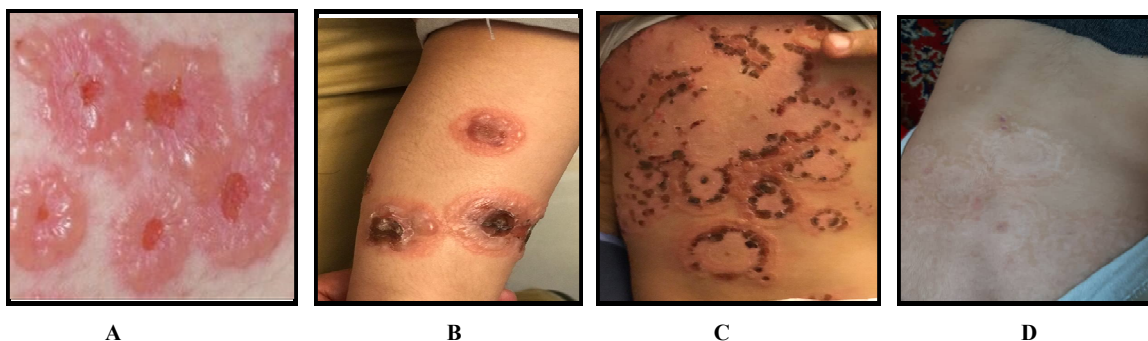


Figure 1. A, B) Characteristic lesions in Linear IgA Bullous Dermatitis (LABD); “String of pearls” sign C) Disappearing lesions after treatment D) complete improved lesions after treatment with dapsone

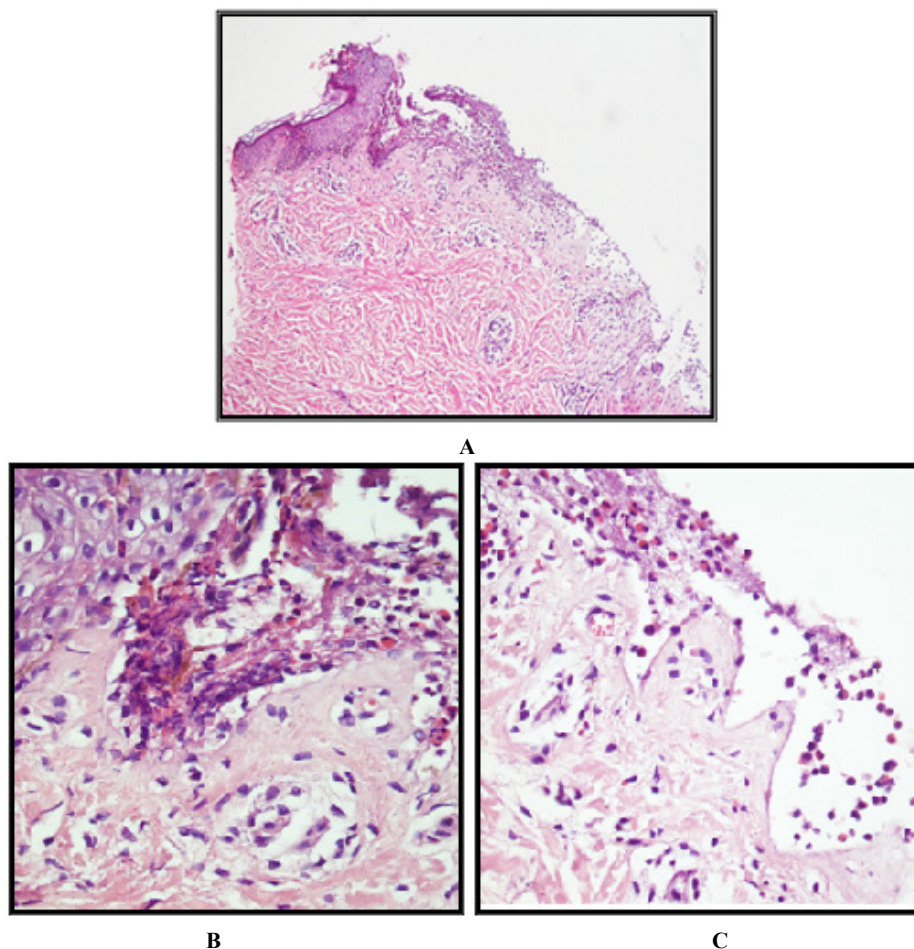


Figure 2. A, B, C) Skin biopsy from a trunk lesion and histopathological examination with hematoxylin and eosin (H&E) staining showed subepidermal bullae with predominantly eosinophils and some neutrophils entrapped in a fibrin network associated with perivascular lymphocytic infiltration and some interstitial eosinophils

Table 1. Differential diagnosis of blistering diseases according to the age of onset

Children	Adult
Bullous impetigo	Atypical erythema multiforme
Bullous papular urticaria	Bullous pemphigoid
Childhood Bullous pemphigoid	Bullous systemic lupus erythematosus
Dermatitis herpetiformis	Dermatitis herpetiformis
Epidermolysis bullosa	Excoriated nodular prurigo
varicella	Steven johnson syndrome
	Toxic epidermal necrolysis

Linear IgA Bullous Dermatitis Following Aspirin Therapy

In a one-month cardiology follow-up visit, aspirin was readministered to prevent any cardiac complications of mucocutaneous lymph node syndrome. Skin lesions reappeared in less than 72 hours that included new bullous lesions in the trunk and acral regions. Therefore, aspirin immediately discontinued again and dapsone continued.

DISCUSSION

Linear IgA Bullous Dermatitis (LABD) is a rare autoimmune bullous dermatosis, but the most common autoimmune bullous dermatosis in children.^{2-5,8}

The immune system produces IgA antibodies which are incorrectly and linear deposited in the top layer of the skin and can cause damage to the structure of the skin, as a result, a blister appears.^{1,2,8}

LABD may be triggered by some causes as prodromal diseases including upper airway or urinary tract infections, brucellosis, salmonella enteritis, immunization (varicella or influenza vaccine), systemic autoimmune diseases (systemic lupus erythematosus, psoriasis, rheumatoid arthritis, dermatomyositis, Crohn's disease, ulcerative colitis), malignancies (Hodgkin's disease, B cell lymphoma, Bladder cancer, esophageal cancer) and others.¹⁻⁴ Drugs such as antibiotics, analgesics, antihypertensives, antiepileptics, or immunosuppressants have been identified as potential causative agents to develop LABD.¹⁻³ Antibiotics and NSAIDs are most frequent in children.⁴

Because LABD is clinically indistinguishable from other autoimmune bullous dermatoses, other differentials should be considered.^{1,2,4} (Table 1). Diagnosis of LABD requires a high index of suspicion and early confirmation with dermopathologic studies and specific staining techniques like DIF.^{1-3,8} Histologically, subepidermal blisters are observed in association with neutrophilic and eosinophilic infiltration, which is also observed in bullous pemphigoid and dermatitis herpetiform.^{1,2,4,5} Although, the clinical presentation with "string of pearls" appearance is highly characteristic for LABD, but a definitive diagnosis is based on DIF, which is pathognomonic for LABD, revealing linear deposits of IgA on the BMZ.^{1,2,8} Mucosal involvement was seen in 45.5% children and 14.8% adult patients with LABD, but there is no mucosal involvement in our patient.^{4,9}

Early diagnosis is important for proper management

because discontinuing the culprit drug is most crucial.⁶ It may be challenging to identify the causative agent of LABD because many patients are treated with multiple drugs.^{1,2,4} The use of the Naranjo algorithm to estimate the probability of adverse drug reaction can help in establishing the correct diagnosis.^{3,6,10}

In our presenting case, there were many findings highly suggestive of aspirin-induced LABD such as the appearance of characteristic lesions one week after administration of aspirin, rapid clearance of the lesions after the withdrawal of the drug, lack of mucosal involvement, reappearing new lesions after readministration of aspirin and IgA deposition and not IgG and C3 in BMZ in DIF study. To establish the diagnosis of aspirin-induced LABD, we applied the Naranjo algorithm, based on the answer to 10 questions, to reach a correct "causality assessment" between the suspected drug (aspirin) and the adverse event. Naranjo probability scale implies an adverse drug reaction score of <2: doubtful; 2 - 4: possible; 5 - 8: probable; >9: definite.¹⁰ We achieved a score of 6 in this case which determined the probable causative role of aspirin.

Up to date, there are only a few case reports of NSAID-induced LABD including only one case of the aspirin-induced disease. NSAIDs such as piroxicam, diclofenac, and naproxen are some culprits that have been previously reported.¹¹⁻¹⁴ In 2017, Gatto et al, reported the first case of aspirin-induced LABD with a possible association, following aspirin use in the management of cold in a two-year-old boy.¹⁴ In other forms of autoimmune bullous dermatoses, Durda et al reported a case of bullous pemphigoid related to aspirin in a 76-year-old man in Turkey in the 2010.¹⁵

The pathogenesis of LABD remains unclear. However, more studies are needed for a better understanding of the pathogenesis, trigger factors, and optimal treatment of LABD.

CONFLICT OF INTEREST

The authors declare no conflicts of interest.

ACKNOWLEDGEMENTS

We would like to thank the colleagues of the Allergy and Clinical Immunology unit of Iran University of Medical Sciences and the parents of the

patient for their precious collaboration.

REFERENCES

1. Egan CA, Zone JJ. Linear IgA bullous dermatosis. *Int J Dermatol.* 1999;38(11):818-27.
2. Fortuna G, Marinkovich MP. Linear immunoglobulin A bullous dermatosis. *Clin Dermatol.* 2012;30(1):38-50.
3. Lammer J, Hein R, Roenneberg S, Biedermann T, Volz T. Drug-induced linear IgA bullous dermatosis: a case report and review of the literature. *Acta DermVenereol.* 2019;99(5-6):508-15.
4. Pereira S, Martins A, Oliveira T, Monteiro V. Dermatosebolhosaiga linear: relato de um casoexuberante e revisão da literatura. *Nascer e Crescer.* 2018;27(4):238-42.
5. Souza BC, Fregonesi NC, Tebcherani AJ, Sanchez AP, Aoki V, Fernandes JC. Linear IgA bullous dermatosis: report of an exuberant case. *An Bras Dermatol.* 2013;88(6):67-70.
6. Lings K, Bygum A. Linear IgA bullous dermatosis: a retrospective study of 23 patients in Denmark. *Acta dermato-enerologica.* 2015;95(4):466-71.
7. Mintz EM, Morel KD. Treatment of chronic bullous disease of childhood. *Dermatol Clin.* 2011;29(4):699.
8. Patsatsi A. Chronic bullous disease or linear IgA dermatosis of childhood—revisited. *J Genet Syndr Gene Ther.* 2013;4(151):2.
9. Genovese G, Venegoni L, Fanoni D, Muratori S, Berti E, Marzano AV. Linear IgA bullous dermatosis in adults and children: a clinical and immunopathological study of 38 patients. *Orphanet J Rare Dis.* 2019;14(1):115.
10. Naranjo CA, Busto U, Sellers EM, Sandor P, Ruiz I, Roberts EA, et al. A method for estimating the probability of adverse drug reactions. *Clinical Pharmacology & Therapeutics.* 1981 Aug;30(2):239-45.
11. Bouldin MB, Clowers-Webb HE, Davis JL, McEvoy MT, Davis MD. Naproxen-associated linear IgA bullous dermatosis: case report and review. In *Mayo Clinic Proceedings* 2000 Sep 1 (Vol. 75, No. 9, pp. 967-970). Elsevier.
12. Plunkett RW, Chiarello SE, Beutner EH. Linear IgA bullous dermatosis in one of two piroxicam-induced eruptions: a distinct direct immunofluorescence trend revealed by the literature. *J Am Acad Dermatol.* 2001;45(5):691-6.
13. Camilleri M, Pace JL. Linear IgA bullous dermatosis induced by piroxicam. *Journal of the E Acad Dermatol Venereol.* 1998;10(1):70-2.
14. Gatto A, Guerriero C, Moretta G, Valentini P, Giorgio V, Lazzareschi I, Rigante D. Linear IgA bullous dermatosis in a two-year-old child: possible association with aspirin. *EJ Dermatol.* 2017;27(4):417-8.
15. Durdu M, Baba M, Seçkin D. A case of bullous pemphigoid induced by aspirin. *J Am Acad Dermatol.* 2011;65(2):443-4.