

## CASE REPORT

Iran J Allergy Asthma Immunol

October 2020; 19(5):545-549.

Doi: 10.18502/ijaai.v19i5.4472

# Is It Drug or Food Allergy? A Case Report

Zaruhi Kalikyan

*Department of Clinical Immunology and Allergology, Yerevan State Medical University  
after Mkhitar Heratsi, Yerevan, Republic of Armenia*

*Received: 19 April 2020; Received in revised form: 23 July 2020; Accepted: 10 August 2020*

## ABSTRACT

Sometimes allergic reactions caused by various food allergens often hidden in the composition of medications can mistakenly be diagnosed as drug allergies. Such reactions can especially be unexpected if antihistamines—virtually designed to treat allergy symptoms, are imitated. We present the case of a 37-year-old female patient with cutaneous allergic reaction initially diagnosed as drug allergy to desloratadine/aerius, a desloratadine-containing antihistamine medication. The diagnostic search began with the anamnestic data of the patient about an allergy to cooked corn in her childhood, current seasonal allergic rhinitis, and hand dermatitis probably related to her professional activity. Skin tests and additional laboratory examinations led to diagnosing corn/maize allergy manifested as both food (mainly) and pollen allergy. Besides, it was concluded that hand dermatitis also can be caused by cornstarch contained in medical gloves. Finally, based on the results of a drug challenge test performed with two desloratadine-containing medications—desloratadine/aerius containing cornstarch as an excipient and desloratadine/lordestinenot containing cornstarch, the causative significance of corn was confirmed. Thus, the initial diagnosis of drug allergy was changed to that of food allergy.

**Keywords:** Drug hypersensitivity; Food hypersensitivity; Histamine antagonists

## INTRODUCTION

Histamine antagonists are the main medications used to treat allergies so the hypersensitivity reactions to them are unexpected and very rare<sup>1</sup>. Nevertheless, we found a few reports about allergic reactions to histamine antagonists<sup>1-4</sup> for the last several years. We also came across several publications stating that

potential allergic reactions did not relate to the active substance of the drug, but its excipients such as lactose, gelatin, chemical dyes, food colorings, gluten, soy, peanuts oil, etc.<sup>5-7</sup> Despite the frequent use of cornstarch as an excipient in oral medications, we did not find any report about allergic reactions caused by it during peroral treatment, and only a few publications that we found on cornstarch contained in medical gloves<sup>8,9</sup> referred to it as a causative factor of some allergy-like conditions. As a whole, hypersensitivity to corn/maize is not a common type of allergy as well.<sup>10</sup> We present a case of diagnostic search for a causative allergen that ended up with an altered initial diagnosis of drug hypersensitivity to food allergy.

---

**Corresponding Author:** Zaruhi Kalikyan, MD, PhD,  
Department of Clinical Immunology and Allergology, Yerevan State  
Medical University after Mkhitar Heratsi, 2 Koryun St, Yerevan,  
Republic of Armenia. Tel: (+37 493) 118 845, E-mail:  
zkalikyan@yandex.ru

### CASE REPORT

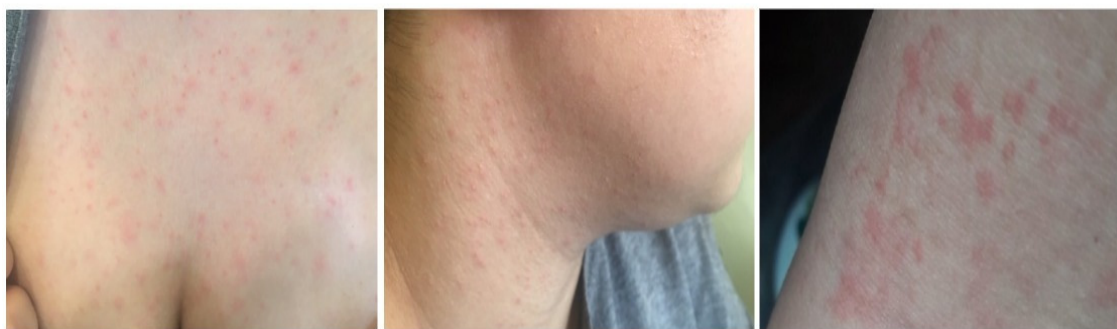A 37-year-old female patient applied to our clinic with complaints of a very itchy rash localized on her upper extremities, chest, and neck. The rashes on her neck appeared 2 days ago about 2 hours after using 1 tablet (5 mg) of the antihistamine medication desloratadine/aerius (Schering-Plough Labo N.V., Belgium). The drug was recommended at a pharmacy on account of her exacerbated allergic rhinitis. Upon the first administration of the medication, an itchy rash appeared in her neck area, then spread to her chest during the day. The patient continued to take the medication and the next day rashes appeared on her upper limbs and as itching became even stronger, she had to apply to a clinic. According to her anamnesis, the patient had had several episodes of an itchy rash in her childhood, caused by cooked corn, after which she stopped using it. In addition, throughout her life, the patient had had many occasional isolated itchy rashes associated with food but she was not able to name specific foods. Of her other allergic conditions, the patient mentioned the rhinitis with seasonal exacerbations in June–August and hand dermatitis associated, in her opinion, with her professional activities (nail stylist), despite that she had always been working with medical gloves on. The patient had never consulted a doctor previously and had used desloratadine/aerius to treat her allergic symptoms. Familial history was burdened, the patient's mother had been suffering from bronchial asthma. An objective examination showed a maculopapular rash in the area

of the patient's chest, neck, and hands, there were traces of scratches in some places (Figure 1). The skin on her hand was dry; a slight exfoliation was observed. In addition, there were mild rhinorrhea and redness of eyes.

The condition of the patient's skin returned to normal in 7 days upon the withdrawal of desloratadine/aerius. Exacerbation of allergic rhinitis was treated without using histamine antagonists, prescribing symptomatic treatment with oximethazoline, 0.1% nasal spray, and conjunctival symptoms-Cromoglicic acid, 2% ophthalmic solution, instead. A common hypoallergenic diet was recommended as well.

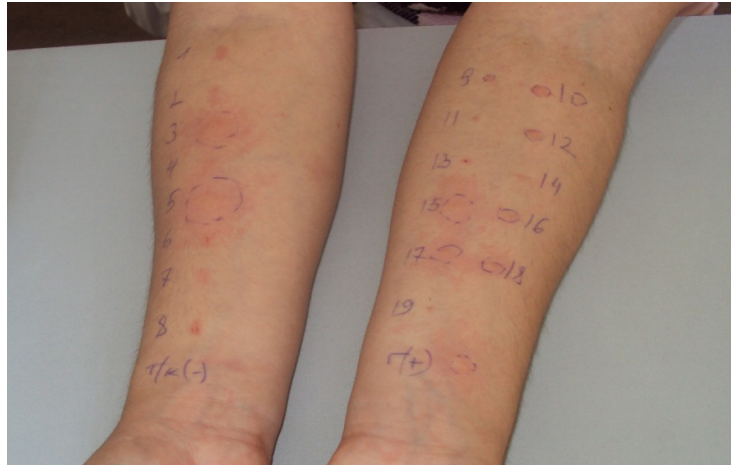
All further diagnostic examinations were performed by the written informed consent of the patient following the principles of the Helsinki declaration.

Skin prick tests (SPT) with basic food allergens and aeroallergens were performed after the complete dissolution of the symptoms. The allergens for testing were chosen based on the anamnesis. Standard industrial water-saline extracts of dust, dust mite, cat hair, sheep hair, feather, egg, chicken, beef, and fish (DiaterLaboratorio, Spain); mix-allergens of grass pollen, weeds pollen, and tree pollen (Biomed after I.Mechnikov, Russia) and the prick-to-prick technique with fresh vegetables, nuts, and kiwi as well as with corn and wheat powder were used.<sup>11</sup> Positive results were obtained with weeds pollen, grass pollen, egg, fish, corn, wheat powder, tree nut, peanut by the measure of  $\geq 3$  mm in comparison with negative control (Figure 2).



**Figure 1. Maculopapular rash on the chest, neck, and hand of the patient**

## Drug or Food Allergy?



**Figure 2. The results of skin prick tests**

**Right hand: 1. Dust – negative; 2. Dust mite – negative; 3. Weeds pollen– positive (4+); 4. Tree pollen – negative; 5. Grass pollen – positive (4+); 6. Cat hair – negative; 7. Sheep hair– negative; 8. Feather– negative; T/k(-) Negative test-control (0.9% Saline solution) - negative;**

**Left hand: 9. Chicken - suspicious (±); 10. Egg – positive (2+); 11. Beef – negative; 12. Fish - positive(2+); 13. Fresh tomato – negative; 14. Fresh carrot– negative; 15. Fresh corn – positive (4+); 16. Wheat powder - positive (2+); 17. Peanut – positive (3+); 18. Tree nut – positive (2+); 19. Kiwi– negative; H(+)**Positive test-control (1% Histamine solution)– positive (3+).****

Patch tests were performed in 14 days after SPTs according to the current recommendations for cosmetic materials testing<sup>12</sup> with five different professional nail styling industrial solutions (NeoNail, Poland): gel-polish (pure), acid primer (5% water dilution), liquid/monomer (5% water dilution), acryl-gel (5% water dilution), nail-polish remover (10% oil dilution), by open techniques on the hands. At the time of patch-testing, no symptoms of dermatitis were observed. No contact with tested solutions and medical gloves was allowed for 20 days before and 3 days after testing. The evaluation was carried out after 48 and 72 hours and all tests were negative.

Additionally, the specific IgE (ImmunoCAP, Phadia-100 (ThermoScientific, Sweden)) was defined as the allergens with the most expressive positive SPTs. The results were as follows: mix of grass pollen (gx1) - 6.61 kUA/l (positive), weeds pollens (w1, w6, w9) – 0.03 kUA/l, 0.09 kUA/l, 0.02kUA/l, respectively (negative) and the corn (f8) – 16.4 kUA/l (positive).

Two months later the single-blind drug challenge was implemented with 2 medications containing the active substance desloratadine according to the current guidelines and in compliance with all safety rules under the control of patient condition.<sup>13</sup> Not any medication was taken for 14 days before the challenge procedures. There was a 5-day interval between the two medication

challenges. The following results were registered: (A) desloratadine/lordestine, 5 mg tablets (Gedeon Richter, Hungary)–all doses negative; (B) Desloratadine/Aerius, 5 mg tablets (Schering-Plough Labo N.V., Belgium): (i) 1.25 mg (1/4 of a tablet)– negative; (ii) 2.5 mg (1/2 of a tablet)– negative; and (iii) 5 mg (1 tablet, standard dose)– positive with the symptoms of itching and mild rash on the neck.

Drug challenge procedures with histamine antagonists were performed within the framework of the research grant "Drug allergy in Armenia: the objectives and the ways of their solution" by the financial support of the state committee of science of Republic of Armenia (Grant № 18T-3B157) which is approved by the committee of bioethics of Yerevan state medical university after Mkhitar Heratsi (Approval no 5/13.12.2018).

## DISCUSSION

The search for a possible cause of an acute allergic reaction was initiated based on the assumption that though histamine antagonists are the main antiallergic drugs, hypersensitivity reactions to them might develop as well. According to our findings, most often allergic reactions develop to the piperazine derivatives (hydroxyzine, cetirizine, levocetirizine), fexofenadine,

ebastine.<sup>1-4</sup>

There is just one publication about the side effects of drugs on hypersensitivity to desloratadine, the active substance of desloratadine/aerius (Schering-Plough Labo N.V., Belgium) like what has been used in our case.<sup>14</sup> Regarding the possibility of drug hypersensitivity to histamine antagonists and particularly desloratadine, we canceled the use of desloratadine/aerius and did not prescribe any other histamine antagonist.

Subsequently, the history of the patient showed that similar reactions to cooked corn she had experienced in her childhood and that she also had been suffering from seasonal allergic rhinitis worsening in June-August. The publications we found indicated that major maize allergen-induced allergic reactions were not common<sup>15</sup> and could be grouped into (i) food allergy due to ingestion,<sup>16</sup> (ii) pollen-induced respiratory allergy<sup>17</sup>, and (iii) occupational asthma or dermatitis due to inhalation or handling of maize flour.<sup>18</sup> Besides, not only pollen-food maize allergy but also cross-reactions with other crops, soybeans, etc. and different grass and weeds pollens were quite common.<sup>18-20</sup> The diagnostic search led us to confirm IgE hypersensitivity of our patient to corn grains (by SPT and ImmunoCAP) as a food allergen, as well as to grass pollen (by SPTs and ImmunoCAP) and weeds pollen(only by SPT) as pollen allergen exhibiting pronounced cross-reactivity with maize pollen. ImmunoCap was negative to weeds pollen that can be dependent on a slight difference in compositions of weeds pollen in the mix-allergen extract tested by SPTs and ImmunoCAP. However, though our patient did not use corn, she often experienced episodes of itchy rashes not connected with seasonal exacerbation of her allergic rhinitis but rather associated with food intake. This can be explained by both cross-reactivities with corn and polysensitization to some other food allergens detected by SPTs (peanut, tree nut, wheat powder, egg, fish). Besides, corn can be a hidden allergen.

Another interesting feature was identified in connection with the professional activity of the patient, who was a nail stylist and often dealt with various solutions, although she worked with medical gloves on. According to some publications, cornstarch that is now used instead of talc in powdered gloves can sometimes cause allergy-like symptoms, both for those who put them on and for those to whom various manipulations are performed using gloves.<sup>8,9</sup> In our case, since the

patch-tests with professional solutions were negative, we concluded that the symptoms of hand dermatitis can also be a result of sensitization to corn.

And finally, we come back to the question of the causative value of desloratadine/aerius. In the literature available we found several publications stating the occurrence of allergic reactions to inactive ingredients of medications, and the most common causes of such reactions were gelatin, food coloring, additives, soy, gluten, etc.<sup>5-7</sup> However, there were only scarce mentions of cornstarch and without any reference to any case report. In our case, since the composition of desloratadine/aerius includes cornstarch, as reported by the manufacturer (Schering-Plough Labo N.V., Belgium), the drug challenge—"gold standard" in the diagnosis of drug hypersensitivity,<sup>13</sup> was performed with an aim to exclude the causative significance of the active ingredient desloratadine and confirm the impact of cornstarch. For this purpose, we decided to carry out the challenge also using another histamine antagonist containing active ingredient desloratadine, desloratadine/lordesine with no content of cornstarch excipient as reported by the manufacturer (Gedeon Richter, Hungary). The negative results of the challenge with desloratadine/lordesine and positive result of the challenge with desloratadine/aerius finally confirmed the causative significance of cornstarch in the development of allergic reaction in our patient.

Thus, we found out that the cause of acute allergic cutaneous reaction was not the antihistamine medication desloratadine/aerius itself, but cornstarch contained in it as an excipient. Therefore, the initial diagnosis of drug hypersensitivity was changed to that of food allergy to corn. Based on the diagnosis, a corn-free diet with taking into account of cross-reactions and limiting other identified food allergens was recommended to the patient. It was also recommended to replace powdered medical gloves with powder-free gloves, and always pay attention to the instructions of the medication and food labels for the presence of any kind of corn in them. The issue of allergen-specific immunotherapy (ASIT) with maize pollen is currently under consideration.

This case shows that sometimes food allergy to excipients may mimic the drug hypersensitivity even to Histamine antagonists, so treatment must be prescribed only by a physician based on the patient's detailed history.

**CONFLICT OF INTEREST**

The authors declare no conflicts of interest.

**ACKNOWLEDGEMENTS**

We express gratitude to all organizations that have assisted our work.

**REFERENCES**

1. Shakouri AA, Bahna SL. Hypersensitivity to antihistamines. *Allergy Asthma Proc.* 2013;34: 488–496.
2. Viñas M, Castillo MJ, Hernández N, Ibero M. Cutaneous drug eruption induced by antihistamines. *Clin Exp Dermatol.* 2014;39(8):918-920.
3. Rodríguez del Río P, González-Gutiérrez ML, Sánchez-López J, Nuñez-Acevedo B, Bartolomé Alvarez JM, Martínez-Cóccera C. Urticaria caused by antihistamines: report of 5 cases. *J Investig Allergol Clin Immunol.* 2009;19(4):317–20.
4. Sánchez Morillas L, Rojas Pérez-Ezquerria P, ReañoMartos M, Sanz ML, Laguna Martínez JJ. Urticaria due to antihistamines. *J Investig Allergol Clin Immunol.* 2011; 21(1): 66-68. Erratum in: *J Investig Allergol Clin Immunol.* 2011; 21(2):2 p following 161.
5. Reker D, Blum SM, Steiger C, Anger KE, Sommer JM, Fanikos J, Traverso G. “Inactive” ingredients in oral medications. *Sci Transl Med.* 2019;11(483):eaau6753.
6. AudicanaBerasategui MT, BarasonaVillarejo MJ, Corominas Sánchez M, De Barrio Fernández M, García Avilés MC, García Robaina JC, et al. Potential hypersensitivity due to the food or food additive content of medicinal products in Spain. *J Investig Allergol Clin Immunol.* 2011; 21(7):496-506.
7. Kelso JM. Potential food allergens in medications. *J Allergy Clin Immunol.*2014;133:1509-18.
8. Edlich RF, Long WB 3rd, Gubler DK, Rodeheaver GT, Thacker JG, Borel L, et al. Dangers of cornstarch powder on medical gloves: seeking a solution. *Ann Plast Surg.* 2009;63(1):111-5.
9. Seggev JS, Mawhinney TP, Yunginger JW, Braun SR. Anaphylaxis due to cornstarch surgical glove powder. *Ann Allergy.*1990;65:152–5.
10. Scibilia J, Pastorello EA, Zisa G, Ottolenghi A, Ballmer-Weber B, Pravettoni V, et al. Maize food allergy: a double-blind placebo-controlled study. *Clin Exp Allergy.* 2008;38(12):1943-1949.
11. Heinzerling L, Mari A, Bergmann K-Ch, Bresciani M, Burbach G, Darsow U, et al. The skin prick test - European standards. *Clin Transl Allergy.* 2013; 3(1):3.
12. Nigam PK. Adverse reactions to cosmetics and methods of testing. *Indian J Dermatol VenereolLepr.* 2009;75(1):10-8.
13. Chiriac AM, Demoly P. Drug provocation tests: up-date and novel approaches. *Allergy Asthma Clin Immunol.* 2013;9(1):12.
14. Walsh GM. Antihistamines (H1 receptor antagonists). In J. K. Aronson (Ed.), *Side Effects of Drugs Annual: A worldwide yearly survey of new data in adverse drug reactions.* Elsevier Science. 2011;33:345-51.
15. Venter C, Skypala I, Dean T. Maize allergy: what we have learned so far. *Clin Exp Allergy.*2008;38:1844-6.
16. Pastorello EA et al. Maize food allergy: lipid-transfer proteins, endochitinases, and alpha-zein precursor are relevant maize allergens in double-blind placebo-controlled maize-challenge-positive patients. *Anal Bioanal Chem.* 2009;395(1):93-102.
17. Gonzalo-Garijo MA, Perez-Calderon R, Munoz-Rodriguez A, Tormo-Molina R, Silva-Palacios I. Hypersensitivity to maize pollen. *Allergy.* 2004;59(3):365.
18. Weichel M, Glaser AG, Ballmer-Weber BK, Schmid-Grendelmeier P, Cramer R. Wheat and maize thioredoxins: a novel cross-reactive cereal allergen family related to baker's asthma. *J Allergy Clin Immunol.* 2006;117(3):676-81.
19. Lehrer SB, Reese G, Malo JL, Lahoud C, Leong-Kee S, Goldberg B. Corn allergens: IgE antibody reactivity and cross-reactivity with rice, soy, and peanut. *Int Arch Allergy Immunol.* 1999;118(2-4):298-9.
20. Weber RW. Cross-reactivity of pollen allergens. *Curr Allergy Asthma Rep.* 2004;4(5):401–8.