

## CASE REPORT

Iran J Allergy Asthma Immunol

February 2020; 19(1):94-101.

Doi:

# A Novel Non-frameshift ADA Deletion Detected by Whole Exome Sequencing in an Iranian Family with Severe Combined Immunodeficiency

Taravat Talebi<sup>1</sup>, Alireza Biglari<sup>1</sup>, Mohammad Shahrooei<sup>2,3</sup>, Majid Changi-Ashtiani<sup>4</sup>, Hossein Dinmohammadi<sup>1</sup>, Shadi Sadat Navabi<sup>3</sup>, Nima Parvaneh<sup>5</sup>, Xavier Bossuyt<sup>2,6</sup>, Tina Shahani<sup>1</sup>, and Hassan Rokni-Zadeh<sup>7</sup>

<sup>1</sup> Department of Genetics and Molecular Medicine, School of Medicine, Zanjan University of Medical Sciences (ZUMS), Zanjan, Iran

<sup>2</sup> Clinical and Diagnostic Immunology, Department of Microbiology and Immunology, KU Leuven, Leuven, Belgium

<sup>3</sup> Specialised Immunology Laboratory of Dr. Shahrooei, Ahvaz, Iran

<sup>4</sup> School of Mathematics, Institute for Research in Fundamental Sciences (IPM), Tehran, Iran

<sup>5</sup> Department of Pediatrics, Division of Allergy and Clinical Immunology, Tehran University of Medical Sciences, Tehran, Iran

<sup>6</sup> Department of Laboratory Medicine, University Hospitals Leuven, Leuven, Belgium

<sup>7</sup> Department of Medical Biotechnology, School of Medicine, Zanjan University of Medical Sciences (ZUMS), Zanjan, Iran

Received: 10 April 2019; Received in revised form: 8 August 2019; Accepted: 14 August 2019

## ABSTRACT

Severe combined immunodeficiency (SCID) comprises a heterogeneous group of genetic disorders caused by early defects in the development and function of T cells. Other lymphocyte lineages (B and/or natural killer cells) are variably affected. With a worldwide frequency of approximately 1:50,000 live births, SCID may result from diverse mutations in over 16 genes.

Whole-exome sequencing (WES) provides an opportunity for parallel screening of all those genes. This approach is also useful for genetic diagnosis in parents whose infant expired before genetic testing.

Here, we describe a heterozygous novel non-frameshift deletion (c.587\_598del p.196\_199del) in the adenosine deaminase (ADA) gene identified by WES in healthy parents of an expired child with SCID. The mutation was subsequently confirmed to be homozygous in the deceased baby whose left-over blood sample volume was insufficient for direct WES analysis.

In conclusion, we here describe a novel mutation in ADA, a well-known SCID gene.

**Keywords:** Adenosine deaminase; Severe combined immunodeficiency; Whole exome sequencing

---

**Corresponding Authors:** Hassan Rokni-Zadeh, PhD;  
Department of Medical Biotechnology, School of Medicine,  
Zanjan University of Medical Sciences (ZUMS), Zanjan, Iran.  
Tel: (+98 930) 5837 014, E-mail: hassan.roknozadeh@gmail.com

---

Tina Shahani, PhD;  
Department of Genetics and Molecular Medicine, School of  
Medicine, Zanjan University of Medical Sciences (ZUMS), Zanjan,  
Iran. Tel: (+98 93) 3440 1737, E-mail: tina.shahani@zums.ac.ir

### INTRODUCTION

Human primary immunodeficiency disorders (PIDs) affect the function and/or development of the immune system.<sup>1</sup> PIDs include about 330 disorders of different prevalence among several populations. As the most severe type of PIDs, severe combined immunodeficiency (SCID)<sup>2</sup> is a heterogeneous genetic disorder characterized by defects in cellular and/or humoral immunity.<sup>3</sup> There are several types of SCID with heterogeneous clinical presentations caused by mutations in various genes that are necessary for the development and function of T and B lymphocytes.<sup>4</sup> Therefore, affected patients are usually presented with severe recurrent infections, skin rashes, chronic diarrhea, failure to thrive, and lymphopenia within the first year of life.<sup>5</sup> Newborn screening with T-cell receptor excision circles (TREC) test allows pre-symptomatic diagnosis and effective treatment.<sup>6</sup> Despite its effectiveness in the diagnosis and management of SCID, this test is not applied in many countries including Iran.

SCID is inherited in an X-linked, autosomal recessive or even autosomal dominant fashion.<sup>7</sup> Accurate diagnosis is also possible with genetic testing which provides a potential ground for appropriate genetic counseling, prenatal screening, and treatment. Since over 16 genes have been reported to be involved in SCID, the accurate genetic diagnosis has been technically challenging, time-consuming, and expensive; using conventional diagnostic methods.<sup>8,9</sup> On the contrary, whole-exome sequencing (WES) provides an accurate, timely, and cost-effective diagnosis<sup>10-12</sup> and has become a rapid first-line genetic approach to evaluate complex PIDs.<sup>11</sup> In this study, WES was applied for the diagnosis of SCID in a selected Iranian family with healthy parents; giving birth to two infants who were died in their first year of life and a history of three abortions.

### MATERIALS AND METHODS

#### Family Information

We studied a family with consanguineous marriage suffering from PID who had been referred to the children's medical center of Tehran University of Medical Sciences. In this family, a 5-months-old boy (proband) was expired with recurrent fever, pneumonia, diarrhea, and failure to thrive who was suspected for

SCID (Figure 1). The first child of the same parents, a girl, was died two years earlier (without a genetic diagnosis) at the age of 4 months following recurrent infections. Although the parents reported a similar disease course for both children, no clinical sample or document was available from their first child. Both children had received the regularly scheduled vaccination, including Bacillus Calmette-Guérin (BCG) vaccine, at birth. As depicted in the pedigree (Figure 1), a history of spontaneous abortions and early death was reported without a family history of immunodeficiency disorders.

Finally, due to the death of the selected boy (proband) before starting any genetic diagnosis, further WES testing was performed on samples from his parents.

Whole blood samples were received from the consent from each individual. The study was conducted according to the Helsinki declaration and approved by the Research Ethics Committee of Zanjan University of Medical Sciences (ZUMS.REC.1395.208).

#### WES and Data Analyses

The peripheral blood was received from the parents. Genomic DNA was isolated from whole blood; using Cinna Pure DNA kit (Iran). Exome capture and sequencing were performed on gDNA by Macrogen (Seoul, South Korea); using standard protocols on Illumina HiSeq 4000 (San Diego, CA, USA, 101-bp paired-end reads). The library was prepared; using SureSelect XT Library Prep Kit (Agilent Technologies, CA, USA). We used BWA to map a collection of reads to the reference genome (version b37) and variants were called and annotated; using GATK and ANNOVAR, respectively.<sup>13</sup> Focusing on heterozygous variants, a minimum allele frequency of <5% in the 1000 Genome, ExAc, and gnomAD was used for filtration. A list of genes involved in SCID and PID was checked. Several amino acid change predictors such as Mutation Taster, SIFT, Polyphen, and CADD were also employed.

#### Segregation Studies

PCR amplification and product purification were done based on standard protocols. The PCR products were sequenced; using the Sanger sequencing method (applied Biosystems 3500G). The Geneious software (Geneious 10.2.2, Biomatters Ltd. New Zealand) was used to design specific primers. The protein sequences were obtained from NCBI.

## RESULTS

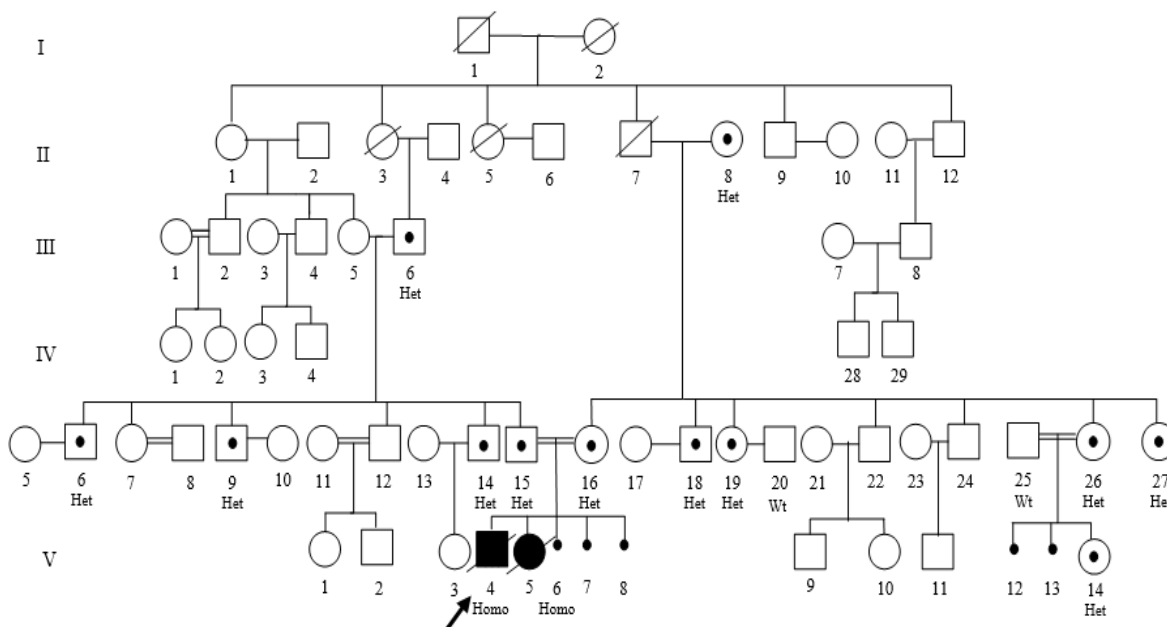
## Clinical Information

The studied boy was born at term by cesarean delivery (Figure 1). Beginning at two months, he developed failure to thrive, and persistent oral thrush, and was admitted several times due to fever, diarrhea, and severe pneumonia that poorly responded to antibiotics.

At 3 months of age, he was admitted with fever and signs of severe pneumonia. The absence of pharyngeal tonsils was notable in physical examination. No organomegaly was detected. The chest x-ray demonstrated fine milliary pattern in both lung fields, also hila and lung fields were congested (Figure 2). The chest computed tomographic (CT) scan revealed the patchy subpleural ground-glass opacities in both lungs with thick interlobular septa which could indicate acute

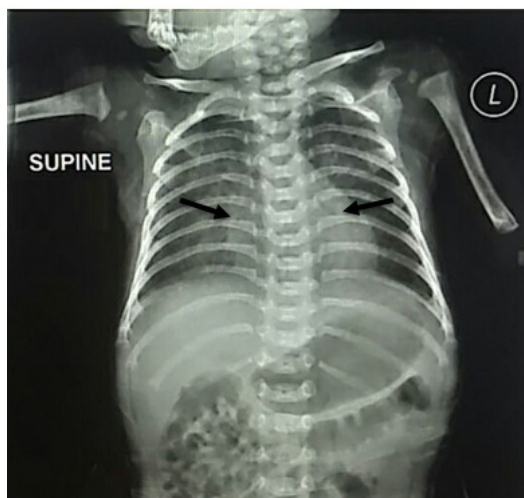infection. Bronchoalveolar lavage (BAL) of lungs revealed gram negative-bacilli and gram-positive cocci on gram staining. Moreover, the culture result was positive for *Candida albicans* and coagulase-negative staphylococci. BAL fluid was negative for acid-fast bacilli and CMV. Blood culture was negative as well. Broad-spectrum antibiotics were applied against gram-positive and gram-negative organisms.

Laboratory studies showed lymphopenia, neutropenia, and eosinophilia (Table 1). Immunophenotyping of peripheral blood lymphocytes revealed a T<sub>B</sub>NK<sup>+</sup>SCID phenotype. The serum levels of IgE, IgG, IgM, and IgA were reduced. Liver aminotransferases were elevated to 2 times higher than the normal range. He was discharged with prophylactic trimethoprim-sulfamethoxazole, acyclovir, and monthly intravenous immunoglobulin.



**Figure 1.** Pedigree of the studied family with severe combined immunodeficiency (SCID) disorder. The black arrow is pointing to the proband. His parents' DNA samples were used for whole-exome sequencing (WES). Circle and square symbols represent female and male family members, respectively. Affected individuals are illustrated by black filled symbols and unaffected ones by open symbols. Identified variants in the Adenosine deaminase (*ADA*) gene for each of the participants in this study are indicated as Wt (Wild type), Homo (Homozygote) and Het (Heterozygote). Carriers are represented by a small circle inside the shape. Deceased members are illustrated by diagonal slash on the symbol. Aborted fetuses are shown by a small black circle.

## WES Identifies a Novel Mutation in SCID



**Figure 2.** The chest x-ray of the proband (V-4) at 3 months of age indicated the miliary pattern in both lung fields. The arrows indicate the position of hila and lung congestion.

**Table 1. Laboratory findings for the pedigree's proband at 3 months of age**

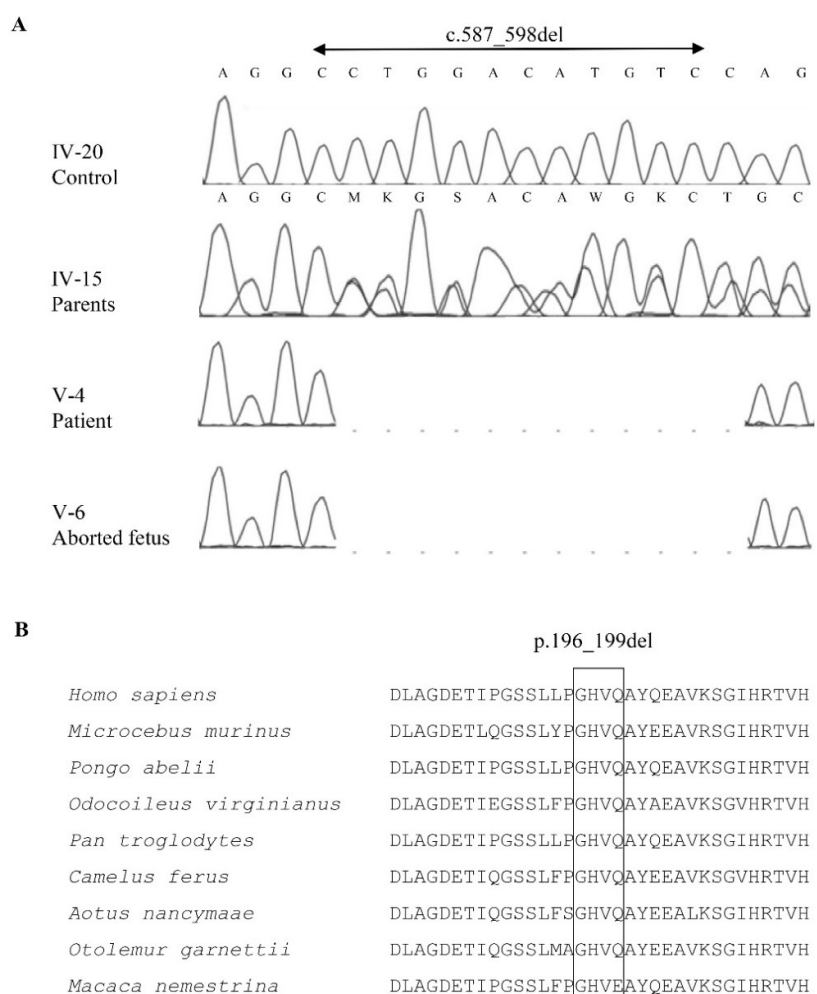
Test	Result	Reference Range
Red blood cell	4750000	3100000-4500000 cell/ $\mu$ L
White blood cell	2600	4500-11000 cell/ $\mu$ L
Lymphocytes	260	3400-11300 cell/ $\mu$ L
Neutrophils	960	1100-5600 cell/ $\mu$ L
Eosinophils	1000	<800 cell/ $\mu$ L
Hemoglobin	10.6	9.5-13.5 g/dL
Hematocrit	39.7	29-41 %
Platelet	495000	150000-450000 cell/ $\mu$ L
IgA	<10	10-94 mg/dL
IgG	73	142-1245 mg/dL
IgM	<10	14-212 mg/dL
IgE	1.0	<11 IU/mL
CD3 <sup>+</sup>	4.3	59 – 85 %
CD4 <sup>+</sup>	4.2	30 – 60 %
CD8 <sup>+</sup>	4.3	11 – 38 %
CD16 <sup>+</sup>	16.6	8-22 %
CD56 <sup>+</sup>	0.1	2-10 %
CD19 <sup>+</sup>	0.1	5-15 %
AST	137	5-40 IU/L
ALT	67	5-40 IU/L
AFP	10499	<8.5 IU/mL
Gamma-GT	235	3-55 IU/L

Ig, immunoglobulin; AST, aspartate aminotransferase; ALT, alanine aminotransferase; AFP, Alpha-fetoprotein; Gamma-GT, Gamma-glutamyl transferase.

However, the baby was expired at the age of five months after another episode of lung infection before reaching a precise genetic diagnosis.

The clinical diagnosis of SCID and family history prompted us to search for the genetic cause of the disease; using WES. Due to the lack of sufficient left-over blood sample from the patient, the healthy parents were subjected to WES. Through WES, screening for heterozygous pathogenic variants was common in both parents. Candidate variants were then subjected to PCR-Sanger sequencing in the small amount of DNA sample which was left from the expired baby (pedigree's proband).

As a result, a novel heterozygous non-frameshift deletion (c.587\_598del, p.196\_199del) was identified in the sixth exon of the adenosine deaminase gene (*ADA*) of both parents and was further confirmed by PCR-Sanger sequencing. The identified genetic variation was not found in any databases, including the 1000Genome projects, esp6500, ExAC, and gnomAD. Interestingly, the proband was homozygous for the same variety which results in a deletion of 4 amino acids including, Gly, His, Val, and Gln (Figure 3A). As shown in Figure 3B, amino acid positions were conserved throughout different vertebrate species, implying their essential function.



**Figure 3. (A) Sequencing chromatograms of *ADA* mutation. Parents carry a heterozygous c.587\_598del mutation. A homozygous c.587\_598del was completely co-segregated with affected individuals in this family. M, C or A; K, G or T; S, C or G; R, A or G; W, A or T. (B) Conservation analysis of affected *ADA* region among different species.**

## WES Identifies a Novel Mutation in SCID

Following that, we examined 16 other members of the pedigree (Figure 1) for that variation; using PCR-based Sanger sequencing. Detection of heterozygous c.587\_598del mutation in 10 other family members confirmed that the deletion segregated with the affected phenotype in this family (Figure 1).

In addition to *ADA* mutation, a novel non-synonymous *CR2* variation (NM\_001006658:exon14:c.G2624A, p.C875Y) was detected but based on most predictors including CADD (score: 12), it could not be a deleterious mutation.

### DISCUSSION

In this study, a novel homozygous c.587\_598del (p.196-199del) *ADA* mutation was identified as the underlying cause of SCID in an Iranian family. The mutation was first identified as heterozygous in parents through WES and was then confirmed in the left-over DNA sample of their baby who was expired before being referred for genetic analysis.

The prevalence of SCID has been estimated to be more than 1 per 100,000 live births.<sup>14</sup> The number of autosomal recessive forms are potentially higher in societies with a high rate of consanguineous marriages. However, the actual incidence of the disease is not clear as many patients die before a definite diagnosis.<sup>15</sup>

In an Iranian registry, SCID has been documented as a common disorder (21.1 % of PIDs) (16). Iranian SCID patients mainly display an autosomal recessive inheritance pattern.<sup>16</sup> Of those, 34.9% are reported as having T-B-NK+ SCID with a mutation in the *RAG2* or *RAG1* genes. Fourteen percent of the SCID patients are said to be X-linked SCID (XL-SCID). This distribution of SCID subtypes differs from Europe and America, where XL-SCID is the most common form.<sup>5,17</sup>

In this study, Sanger sequencing of consanguineous parents for *RAG1* and *RAG2* genes was negative. So, the clinical symptoms and the family history of early infant death prompted us to study the causative genetic defect of the disease by using WES.

*ADA* gene (20q13.12); encoding adenosine deaminase (ADA: EC 3.5.4.4), is involved in the deamination of adenosine and deoxyadenosine to inosine or deoxyinosine, respectively.<sup>18</sup> ADA deficiency is found in 15-20% of SCID patients.<sup>14,15</sup> The most common clinical manifestations of ADA

deficient SCID patients are pneumonia, recurrent infections, oral candidiasis, chronic diarrhea, skin rashes, and failure to thrive within the first months of life; needing pediatric emergency care in most cases.<sup>19</sup> The observed phenotype in the studied proband is well-consistent with the above-mentioned clinical manifestations.

As mentioned before, the detected four amino acid deletion has occurred in exon 6 of *ADA*. Based on the currently existing knowledge, this exon does not encode any specific protein domain. However, four likely pathogenic variations in this exon including c.603C>G, p.Tyr201Ter, c.532delG:p.Val178Terfs, c.532dupG:p.Val178Glyfs and c.529G>A:p.Val177Met has already been reported in the ClinVar database from SCID patient studies. Interestingly, none of those variants were located within four amino acids deleted in our patient. Moreover, the amino acids 196 to 199 affected in this patient were highly conserved among various species (Figure 3B). Altogether, these results imply that exon 6 might have an important role in the proper function of ADA.

Since SCID is a life-threatening syndrome, early diagnosis plays a key role in the management of the disease.<sup>20</sup> This could be performed with pre-symptomatic screening<sup>21</sup>; especially in patients of consanguineous parents with a history of recurrent infections and early death in their previous children. To do so, WES could be useful in addition to newborn screening using dried blood spots (DBS) that are currently applied in some developed countries. Newborn screening is proposed as a first-approach, potentially accelerating definitive treatment and preventing the administration of live vaccines.<sup>15</sup> Live vaccines such as the BCG vaccine which are part of the routine vaccination program at birth in some countries such as Iran are a common cause of death in SCID patients.<sup>22</sup> In the selected family of the present study, however, no record of BCG-related death was found in the two deceased infants, although both had been vaccinated with BCG.

As previously stated concerning the high rate of consanguinity in the Iranian population, we recommend performing WES and delayed vaccination in suspected cases. This will not only improve the survival rate<sup>23</sup> but also help with a prenatal diagnosis for future pregnancies of the family. Besides, it will increase the rate of a precise genetic diagnosis. The rate of definite

genetic diagnosis in CID patients is 7.9% in Iran<sup>24</sup> when conventional methods are applied. WES enables to increase the diagnosis rate and potentially leads to more appropriate treatment.<sup>24</sup> A major advantage of WES is its applicability for parental carrier detection when the affected baby is unavailable. Although there are several studies taking such a parental-based approach, to our knowledge, none of them have been described for PID patients. For instance, Çalışkan, *et al.* reported a novel *TECR* mutation for autosomal recessive non-syndromic mental retardation (NSMR) in a consanguineous family by WES performed on parents.<sup>25</sup> Similarly, Maroofian, et al could diagnose nephrosialidosis resulting from a mutation in the *NEUI* gene.<sup>26</sup>

In conclusion, our results indicate that WES could be a useful technique for timely identification of the genetic cause of SCID in a prob and through analysis of carrier parents.

#### ACKNOWLEDGEMENTS

We thank the patient's family for their participation in this study. The study was supported by Zanjan University of Medical Sciences (ZUMS) grant No. A-12-835-14 and ethic committee code of ZUMS.REC.1395.208.

#### REFERENCES

- Picard C, Bobby Gaspar H, Al-Herz W, Bousfiha A, Casanova JL, Chatila T, et al. International Union of Immunological Societies: 2017 Primary Immunodeficiency Diseases Committee Report on Inborn Errors of Immunity. *J Clin Immunol* 2018; 38(1):96-128.
- Van der Burg M, Gennery AR. Educational Paper. The Expanding Clinical and Immunological Spectrum of Severe Combined Immunodeficiency. *Eur J Pediatr* 2011; 170(5):561-71.
- Fischer A. Severe Combined Immunodeficiencies (SCID). *Clin Exp Immunol* 2000; 122(2):143-9.
- Tasher D, Dalal I. The Genetic Basis of Severe Combined Immunodeficiency and its Variants. *Appl Clin Genet* 2012; 5:67-80.
- Fazlollahi M, Pourpak Z, Hamidieh A, Movahedi M, Houshmand M, Badalzadeh M, et al. Clinical, Laboratory and Molecular Findings of 63 Patients with Severe Combined Immunodeficiency. A Decade's Experience. *J Invest Allergol Clin Immunol* 2017; 27(5):299-304.
- Kwan A, Abraham RS, Currier R, Brower A, Andruszewski K, Abbott JK, et al. Newborn Screening for Severe Combined Immunodeficiency in 11 Screening Programs in the United States. *JAMA* 2014; 312(7):729-38.
- Cossu F. Genetics of SCID. *Ital J Pediatr* 2010; 36(1):76.
- Ameratunga R, Woon S-T, Neas K, Love DR. The Clinical Utility of Molecular Diagnostic Testing for Primary Immune Deficiency Disorders: a Case-Based Review. *Allergy Asthma Clin Immunol* 2010; 6(1):12.
- Govindaraj GM, Vellarikkal SK, Jayarajan R, Ravi R, Verma A, Chakkiyar K, et al. Case Report: Whole Exome Sequencing Identifies Variation c. 2308G>A p. E770K in *RAG1* Associated with B-T-NK+ Severe Combined Immunodeficiency. *F1000Res* 2016; 5:2532.
- Chou J, Ohsumi TK, Geha RS. Use of Whole-Exome and Genome Sequencing in the Identification of Genetic Causes of Primary Immunodeficiencies. *Curr Opin Allergy Clin Immunol* 2012; 12(6):623-8.
- Gallo V, Dotta L, Giardino G, Cirillo E, Lougaris V, D'Assante R, et al. Diagnostics of Primary Immunodeficiencies through Next-Generation Sequencing. *Front Immunol* 2016; 7:466.
- Fischer A, Notarangelo LD, Neven B, Cavazzana M, Puck JM. Severe Combined Immunodeficiencies and Related Disorders. *Nat Rev Dis Primers* 2015; 1:15061.
- Shirkani A, Shahrooei M, Azizi G, Rokni-Zadeh H, Abolhassani H, Farrokhi S, et al. Novel Mutation of ZAP-70-related Combined Immunodeficiency: First Case from the National Iranian Registry and Review of the Literature. *Immunol Invest* 2017; 46(1):70-9.
- Kelly BT, Tam JS, Verbsky JW, Routes JM. Screening for Severe Combined Immunodeficiency in Neonates. *Clin Epidemiol* 2013; 5(1):363-9.
- Fallah S, Mesdaghi M, Mansouri M, Babaei D, Karimi A, Fahimzad SA, et al. Severe Combined Immunodeficiency: A Case Series and Review from a Tertiary Pediatric Hospital. *Iran J Allergy Asthma Immunol* 2018; 17(2):201-7.
- Aghamohammadi A, Mohammadinejad P, Abolhassani H, Mirminachi B, Movahedi M, Gharagozlou M, et al. Primary Immunodeficiency Disorders in Iran: Update and New Insights from the Third Report of the National Registry. *J Clin Immunol* 2014; 34(4):478-90.
- Picard C, Moshous D, Fischer A. The Genetic and Molecular Basis of Severe Combined Immunodeficiency. *Curr Pediatr Rep* 2015; 3(1):22-33.
- Alunni S, Orrù M, Ottavi L. A Study on the Inhibition of Adenosine Deaminase. *J Enzyme Inhib Med Chem* 2008; 23(2):182-9.
- Rivers L, Gaspar HB. Severe Combined

## WES Identifies a Novel Mutation in SCID

- Immunodeficiency: Recent Developments and Guidance on Clinical Management. *Arch Dis Child* 2015;100(7):667-72.
20. Stephan J, Vlekova V, Le Deist F, Blanche S, Donadieu J, De Saint-Basile G, et al. Severe Combined Immunodeficiency: a Retrospective Single-Center Study of Clinical Presentation and Outcome in 117 Patients. *J Pediatr* 1993; 123(4):564-72.
  21. Chan A, Scalchunes C, Boyle M, Puck JM. Early vs. Delayed Diagnosis of Severe Combined Immunodeficiency: a Family Perspective Survey. *Clin Immunol* 2011; 138(1):3-8.
  22. Shirvani F, Chavoshzadeh Z, Arjmand R, Karimi A. Four-Month-Old Boy with Fever, Hepatosplenomegaly and Diffuse Pulmonary Infiltrations. *Arch Clin Infect Dis* 2012; 7(2):72-4.
  23. Sawyer S, Hartley T, Dyment D, Beaulieu C, Schwartzentruber J, Smith A, et al. Utility of Whole-Exome Sequencing for Those Near the End of the Diagnostic Odyssey: Time to Address Gaps in Care. *Clin Genet* 2016; 89(3):275-84.
  24. Latif AH, Tabassomi F, Abolhassani H, Hammarström L. Molecular Diagnosis of Primary Immunodeficiency Diseases in a Developing Country: Iran as an Example. *Expert Rev Clin Immunol* 2014; 10(3):385-96.
  25. Çalışkan M, Chong JX, Uricchio L, Anderson R, Chen P, Sougnez C, et al. Exome Sequencing Reveals a Novel Mutation for Autosomal Recessive Non-Syndromic Mental Retardation in the *TECR* Gene on Chromosome 19p13. *Hum Mol Genet* 2011; 20(7):1285-9.
  26. Maroofian R, Schuele I, Najafi M, Bakey Z, Rad A, Antony D, et al. Parental Whole-Exome Sequencing Enables Sialidosis Type II Diagnosis due to an *NEU1* Missense Mutation as an Underlying Cause of Nephrotic Syndrome in the Child. *Kidney Int Rep* 2018; 3(6):1454-63.