

## Original Article

# The Clinical and Molecular Findings of Patients with Multisystem Inflammatory Syndrome in Children (MIS-C)

Farimah Fayyaz<sup>1,2</sup>, Gholamreza Azizi<sup>3\*</sup>, Marjan Vakili<sup>4</sup>, Saeed Nikkhah<sup>4</sup>, Yasaman Aminpour<sup>4</sup>, Saba Alijani<sup>5</sup>, Mohammad Shahrooei<sup>6</sup>, Homa Sadri<sup>3,4\*</sup>

<sup>1</sup> Colorectal Research Center, Iran University of Medical Sciences, Tehran, Iran

<sup>2</sup> Network of Immunity in Infection, Malignancy and Autoimmunity (NIIMA), Universal Scientific Education and Research Network (USERN), Tehran, Iran

<sup>3</sup> Non-communicable Diseases Research Center, Alborz University of Medical Sciences, Karaj, Iran

<sup>4</sup> Department of Pediatrics, Imam Ali Hospital, Alborz University of Medical Sciences, Karaj, Iran

<sup>5</sup> Student Research Committee, Alborz University of Medical Sciences, Karaj, Iran

<sup>6</sup> Department of Microbiology and Immunology, Clinical and Diagnostic Immunology, KU Leuven, Leuven, Belgium

Received: 18 May 2022; Accepted: 11 June 2022

## Abstract

**Background:** several children with COVID-19 disease present with fever, gastrointestinal symptoms, rash, conjunctivitis, mucosal changes, shock, and myocardial dysfunction, called multisystem inflammatory syndrome in children (MIS-C), similar to incomplete Kawasaki disease or toxic shock syndrome. The unclear pathophysiology of MIS-C prompts clinical and genetic evaluation of the patients.

**Method:** In the present study, patients with MIS-C disease who were referred by medical specialists of Imam Ali Hospital of Alborz in 2020-2021 were included. The clinical manifestations and laboratory findings of enrolled patients were evaluated, and the genetic analysis was performed by whole exome sequencing (WES), further confirmed by Sanger sequencing.

**Results:** Among 11 patients diagnosed with MIS-C, six patients (54.5%) were male, and the mean (SD) age of participants was 6.55 ( $\pm 2.81$ ) years. The most prevalent clinical presentations included fever (100%), rash (82%), bilateral non-purulent conjunctivitis (73%), and mucous membrane changes (64%). The only patient with genetic alterations was an 8-year-old boy with a homozygous missense variant of the ATP6A1 gene and a heterozygous likely pathogenic canonical splice site variant of the M1B1 gene.

**Conclusion:** Although the young age of patients with MIS-C and their autoinflammatory presentations are similar to patients with inborn errors of immunity, the results indicate that most patients with MIS-C do not have genetic mutations.

**Keywords:** Multisystem Inflammatory Syndrome in Children; MIS-C; SARS-CoV-2; COVID-19

\*Corresponding Authors: Homa Sadri

Non-communicable Diseases Research Center, Alborz University of Medical Sciences, Karaj, Iran

E-mail: [Homasadri7@gmail.com](mailto:Homasadri7@gmail.com)

Gholamreza Azizi, PhD

Non-communicable Diseases Research Center, Vice Chancellor for Research, Alborz University of Medical Sciences, Karaj, Iran

E-mail: [azizi1357g@gmail.com](mailto:azizi1357g@gmail.com)

## How to cite this article

Fayyaz F, Azizi G, Vakili M, Nikkhah S, Aminpour Y, Alijani S, et al. The Clinical and Molecular Findings of Patients with Multisystem Inflammatory Syndrome in Children (MIS-C). *Immunology and Genetics Journal*, 2022; 5(2): 82-88. DOI: <https://doi.org/10.18502/igj.v5i2.15099>

Copyright © 2022 Tehran University of Medical Sciences. Published by Tehran University of Medical Sciences.



This work is licensed under a Creative Commons Attribution-NonCommercial 4.0 International license (<https://creativecommons.org/licenses/by-nc/4.0/>). Non-commercial uses of the work are permitted, provided the original work is properly cited.

## Introduction

Since December 2019, the Coronavirus Disease 2019 (COVID-19) outbreak has led to a pandemic with high morbidity and mortality rates. Although COVID-19 usually has mild symptoms in children (1), the reports of severe complications have attracted attention. A low rate of children who tested positive for SARS-CoV-2 infection manifested with fever, gastrointestinal symptoms, rash, conjunctivitis, mucosal changes, shock, and myocardial dysfunction similar to incomplete Kawasaki disease or toxic shock syndrome (2). The Centers for Disease Control and Prevention (CDC) termed this condition a Multisystem Inflammatory Syndrome in Children (MIS-C) (3).

The pathophysiology of MIS-C is not yet fully clear. The immune dysregulation associated with SARS-CoV-2 is the probable etiology; however, the mechanism is unknown (4). The overlapping clinical features with Kawasaki disease have prompted an investigation into a possible shared pathophysiologic pathway. Although the exact etiology of Kawasaki disease is unknown, it is speculated that genetic predisposition, immunomodulation, and infectious triggers have significant roles in its pathophysiology (5). The genetic predisposition involved in Kawasaki disease is evidenced by racial predisposition and familial aggregation (6). The prognosis of MIS-C is not yet clear, and the existing case series demonstrate that despite the severe clinical course of the disease, most patients survive and recover (7). However, the lack of knowledge in MIS-C may result in delayed diagnosis and a worse prognosis.

Therefore, a better understanding of its pathophysiology and possible etiologic factors could lead to a new diagnostic approach, better outcomes, and prevention. In this study, we aimed to evaluate the genetic, laboratory, and clinical manifestations of patients with MIS-C.

## Patients and Methods

### Study Design

The present study included patients with MIS-C disease who were referred by medical specialists (Rheumatologists and Immunologists) of Imam Ali Hospital of Alborz in 2020-2021.

This study was reviewed and approved by the ethical committee of Alborz University of Medical Sciences. Potential participants were first made

aware of the project by their referring physician. Then the participation consent was obtained from the patients or their parents who fulfilled the inclusion criteria to be enrolled in the study.

### Inclusion and Exclusion Criteria

The inclusion criteria were established based on the World Health Organization (WHO) case definition (8).

Individuals aged <19 years with fever for 3 or more days; AND at least two of the following: 1) Rash or bilateral non-purulent conjunctivitis or mucous membrane changes, 2) hypotension or shock, 3) signs of myocardial dysfunction, valvulitis, pericarditis, or coronary abnormalities, 4) evidence of coagulopathy, 5) acute gastrointestinal problems; AND elevated markers of inflammation, including ESR, CRP, or procalcitonin; AND absence of other etiology; AND a history of close contact with COVID-19 or positive SARS-CoV-2 RT-PCR, serology or antigen test.

The presence of an acquired abnormality, such as HIV infection, chemotherapy, or malignancy, may be grounds for possible exclusion if, in the lead investigator's opinion, such a disease process interfered with the evaluation. Severely debilitated health status or poor venous access may also preclude obtaining sufficient specimens for analysis.

### Data Collection

The patient's medical records documenting the clinical manifestations and laboratory findings were retrieved. For genetic analysis, 4 ml of venous blood was collected from the included patients, from which DNA was extracted for whole exome sequencing (WES), further confirmed by Sanger sequencing.

### Statistical Analysis

The data were entered into the SPSS version 26.0 (SPSS Inc., IBM Company). Categorical and continuous variables were demonstrated as frequency (percentage) and mean (standard deviation (SD)), respectively.

## Results

Among 11 patients diagnosed with MIS-C, six patients (54.5%) were male, and the mean (SD) age of participants was 6.55 ( $\pm 2.81$ ) years. None

of the patients had a positive SARS-CoV-2 RT-PCR at the time of admission, whereas four patients (36.4%) had a positive IgG serology. All the patients were admitted to the standard ward, and none of them were transferred to the Intensive Care Unit (ICU). The mean (SD) time between the onset of symptoms and admission and hospitalization duration were 3.18 ( $\pm 1.40$ ) and 8.70

( $\pm 2.98$ ) days, respectively (Table 1).

Regarding the clinical presentations, aside from fever which was seen in all the patients, nine patients (82%) had rash, eight patients (73%) had conjunctivitis, and seven patients (64%) had mucous membrane changes. Other clinical manifestations are illustrated in Figure 1. The laboratory findings demonstrated that lymphopenia, and

Table 1. Demographic and characteristics of enrolled patients with MIS-C

Variables	Result*	
Age [years]	6.55 (2.81)	
Sex	Male	6 (54.5)
	Female	5 (45.5)
Positive SARS-CoV-2 RT-PCR	0 (0)	
Positive IgG Serology	4 (36.4)	
Close Contact with a COVID-19 patient	5 (45.5)	
The interval between symptoms onset and hospitalization [days]	3.18 (1.40)	
Hospitalization Duration [days]	8.70 (2.98)	

\*Categorical variables are presented as frequency (percentage), and continuous variables as mean (standard deviation)

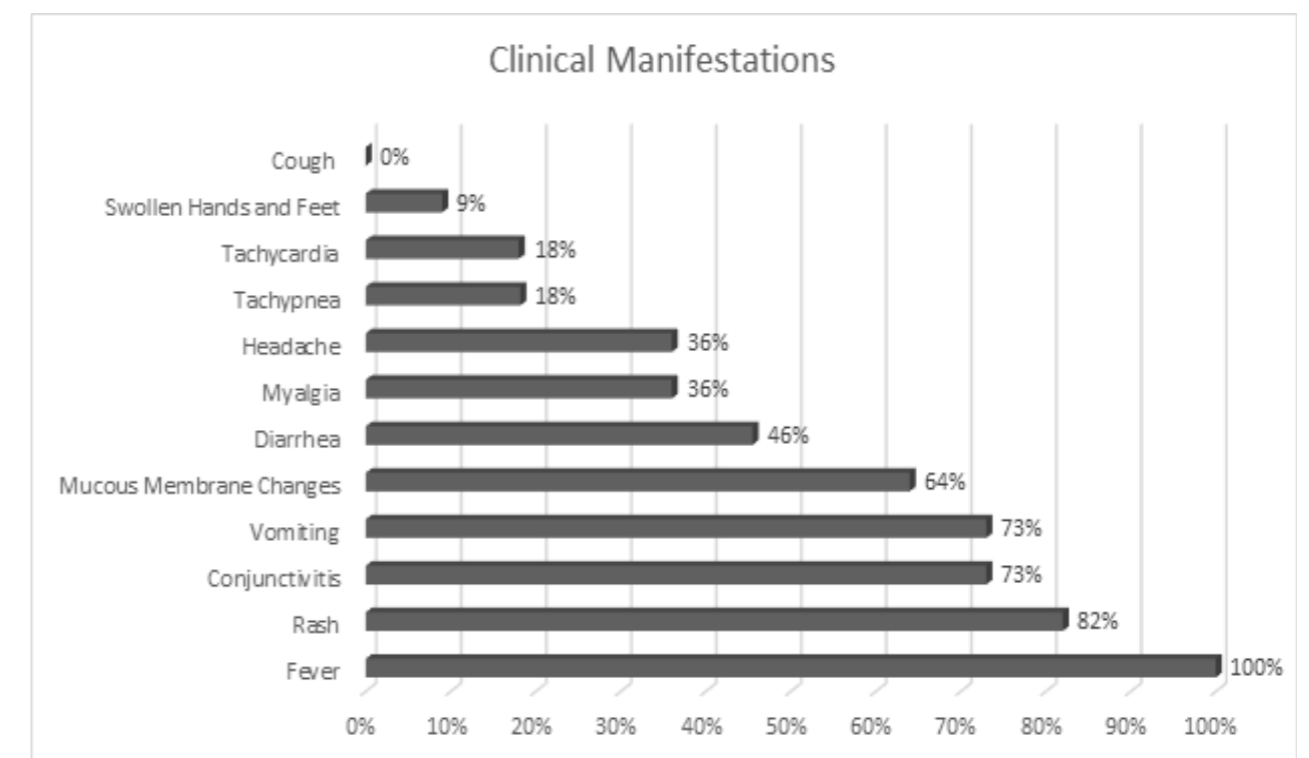


Figure 1. Clinical presentations and their frequency in enrolled patients with MIS-C



elevated CRP, ferritin, LDH, AST, ALT, Cr, and fibrinogen were present among the enrolled patients (Table 2). All patients had normal left ventricular ejection fraction (LVEF) without pericardial effusion or coronary artery abnormalities.

### Molecular Findings

DNA samples of included patients were sequenced by the NGS technique, and the candidate genes of the immunodeficiency panel for disease-causing mutations were checked. No pathology was identified in the enrolled patients, except

in one patient who had a homozygous missense variant of the ATP6AP1 gene, reported to result in immunodeficiency-47 with a recessive X-linked inheritance pattern and classified as a variant of uncertain significance (VUS). In addition, the same patient had a heterozygous likely pathogenic canonical splice site variant of the M1B1 gene (c. 1238-2A>G) which is related to left ventricular noncompaction-7 with an autosomal inheritance (Table 3). The identified patient was an 8-year-old boy without previous hospital admission, born to consanguineous parents, who presented

Table 2. Laboratory findings of the enrolled patients with MIS-C

Laboratory Findings	Mean (SD)	Min – Max
WBC (x10 <sup>9</sup> /L)	0.92 (4.30)	3.47 – 16.60
Hb (gr/dL)	11.93 (0.90)	10.30 – 13.60
Platelets (x10 <sup>3</sup> /μL)	183.55 (66.90)	116 – 313
Polymorphonuclear Leukocytes (x10 <sup>9</sup> /μL)	8.26 (3.58)	2.85 – 13.60
Lymphocytes (x10 <sup>9</sup> / μL)	0.97 (0.70)	0.80 – 0.32
CRP (mg/L)	143.85 (47.18)	67.60 – 212.90
Ferritin (ng/mL)	610.32 (400.89)	209.06 – 1193.37
LDH (IU/L)	611.01 (375.05)	280.70 – 1634.00
AST (U/L)	87.60 (104.41)	23.00 – 370.00
ALT (UL)	72.80 (71.53)	20.00 – 260.00
Cr (mg/dL)	2.25 (3.04)	0.60 – 9.60
Amylase (U/L)	44.42 (68.23)	4.20 – 212.20
Fibrinogen (mg/dL)	525.33 (131.38)	370.00-725.00

Table 3. The identified variant in M1B1 gene description

Gene/ Transcript	Variant Location	Variant	Chromosome Position (GRCh37)	Zygoty	Related Phenotype	OMIM Number	Inheritance Pattern	Variant Classification
M1B1	Intron 8	c. 1238-2A>G	Chr18 19.379.800	Het	Left ventricular noncompaction-7	615092	AD	Likely pathogenic

Het: Heterozygous; AD: Autosomal Dominant

with fever, diarrhea, and vomiting a week before referral. When referred to the rheumatologist, he was dehydrated and had periorbital edema, bilateral non-purulent conjunctivitis, and hematuria. He was admitted to the PICU and was hydrated and treated with Cefotaxime, Clindamycin, and

Methylprednisolone. In his echocardiography, the EF was in the normal range, and a mild TR and PFO were observed. His laboratory findings are presented in Table 4.

### Discussion

Children with MIS-C generally manifest fe-

Table 4. Laboratory findings of the patient with ATP6AP1 and M1B1 variants

Laboratory Findings	Result
WBC (x10 <sup>9</sup> /L)	16.35
Hb (gr/dL)	10.3
Platelets (x10 <sup>3</sup> /μL)	116
Polymorphonuclear Leukocytes (x10 <sup>9</sup> /μL)	13.6
Lymphocytes (x10 <sup>9</sup> / μL)	0.8
CRP (mg/L)	135
LDH (IU/L)	1634
AST (U/L)	370
ALT (UL)	260
Cr (mg/dL)	5.88
D-Dimer (μg/mL)	>1
Fibrinogen (mg/dL)	441

ver, involvement of at least two organ systems, elevated inflammatory markers, and evidence of current or recent SARS-CoV-2 infection (9). In the present study, 11 patients with MIS-C were included, among which the main clinical features were fever (100%), rash (82%), bilateral non-purulent conjunctivitis (73%), and vomiting (73%). In a study by Dufort et al., the most prevalent clinical presentations of patients with MIS-C were fever (100%), tachycardia (97%), gastrointestinal symptoms (80%), rash (60%), and conjunctivitis (56%) (10). Due to the high prevalence of COVID-19 in Iran and the significant number of patients referred with Kawasaki disease and MIS-C, a retrospective study was carried out in Tehran on 45 children with MIS-C. The most common clinical manifestations included fever, abdominal pain, nausea and vomiting, and rash (11).

Several studies have demonstrated that approximately 60% of patients with MIS-C have positive serology tests and negative SARS-CoV-2 RT-PCR tests. Moreover, a low number of patients with MIS-C (5 to 10%) have both negative serology and SARS-CoV-2 PCR tests, and the diagnosis of MIS-C is accomplished by the history of children's close contact with a patient diagnosed

with COVID-19 in the past four weeks (12). In the present study, none of the patients had a positive SARS-CoV-2 RT-PCR test, four out of five patients with available serology tests had positive tests, and five patients gave a history of recent close contact with a COVID-19 patient.

Several studies were recently published regarding the genetic evaluation of patients with MIS-C. In a study on 45 patients with MIS-C and 25 children with COVID-19 as the control group in the United Arab Emirates and Jordan, WES results showed that deleterious heterozygous variants in immune-related genes, including TLR3, TLR6, IL22RA2, IFNB1, IFNA6 were present in 19 patients, among which seven patients had multiple variants. The number of detected genetic variants was significantly higher in patients with MIS-C compared to the control group (13). Since inborn genetic defects and autoantibodies against IFN1 can cause severe pneumonia in COVID-19 disease, they can also influence the pathophysiology of MIS-C. Therefore, in a recent case report by Abolhassani et al., WES analysis was performed on the DNA sample of a three-year-old child who died of COVID-19 and had a combination of severe COVID-19 pneumonia and MIS-C. The results demonstrated a deleterious homozygous mutation in the IFNAR1 gene (14). In another study performed in a hospital in the USA, 39 patients with MIS-C underwent genetic evaluation, demonstrating that 25.4% of patients had heterozygous missense mutations in primary hemophagocytic lymphohistiocytosis (LYST, STXBP2, PRF1, UNC13D, AP3B1) or DOXK8 gene (15). In another single-center study in the USA, 18 patients with MIS-C went through WES analysis. Two patients without any significant history of infections had a homozygous deleterious mutation in XIAP (X-linked inhibitor of apoptosis) and CYBB genes. Moreover, another patient had a heterozygous mutation in the SOCS1 gene, an essential negative regulator of interferons type 1 and 2 (16). Concerning the epigenetic alterations in MIS-C, in a study by Davalos et al., 43 patients with MIS-C, 69 healthy children, and 15 children with COVID-19 disease without MIS-C were evaluated for 850,000 CpG sites of the human genome for DNA methylation variants. The results demonstrated that DNA methylation load was correlated to MIS-C in 33 CpG loci, half of

which were located in ZEB2, SH2D1B, VWA8, HLA-DRB1, CUL2, and AIM2 genes. This DNA methylation profile is also observed in Kawasaki disease (17). In the present study, the genetic evaluation of patients demonstrated that one patient, an 8-year-old boy with consanguineous presenting with fever, diarrhea and vomiting, periorbital edema, bilateral non-purulent conjunctivitis, and hematuria, had a homozygous missense variant of the ATP6AP1 gene, reported to result in immunodeficiency-47 with a recessive X-linked inheritance pattern and classified as a variant of uncertain significance (VUS), and a heterozygous likely pathogenic canonical splice site variant of the M1B1 gene (c. 1238-2A>G) which is related to left ventricular noncompaction-7 with an autosomal inheritance.

The reason behind the absence of immune-related genetic mutations in the majority of patients with MIS-C in the present study could be that 1) the genes involved in MIS-C pathophysiology are not evaluated in the immunodeficiency panel and it would require using high-resolution WES, or 2) epigenetic alterations are responsible for the immune-related manifestation of MIS-C, which WES does not assess.

In addition to the absence of high-resolution WES and epigenetic analysis, other limitations of the present study include the lack of evaluation of genotype association with phenotype due to the absence of a sufficient number of patients with genetic mutations.

In conclusion, although the young age of patients with MIS-C and their autoinflammatory presentations are similar to patients with inborn errors of immunity, the results of the present study and recent publications indicate that the majority of patients with MIS-C do not have genetic mutations.

### Conflict of interest

The authors have no relevant financial or non-financial interests to disclose.

### Acknowledgments

Research reported in this publication was supported by vice chancellor for research, Alborz University of Medical Sciences, under grant No. 4280

### References

1. Castagnoli R, Votto M, Licari A, Brambilla I, Bruno R, Perlini S, et al. Severe Acute Respiratory Syndrome Coronavirus 2 (SARS-CoV-2) Infection in Children and Adolescents: A Systematic Review. *JAMA Pediatr.* 2020;174(9):882-89.
2. Riphagen S, Gomez X, Gonzalez-Martinez C, Wilkinson N, Theocharis P. Hyperinflammatory shock in children during COVID-19 pandemic. *Lancet.* 2020;395(10237):1607-08.
3. Centers for Disease Control and Prevention. Multisystem Inflammatory Syndrome in Children (MIS-C) Associated with Coronavirus Disease 2019 (COVID-19) 2020 [Available from: <https://emergency.cdc.gov/han/2020/han00432.asp>].
4. Godfred-Cato S, Bryant B, Leung J, Oster ME, Conklin L, Abrams J, et al. COVID-19-Associated Multisystem Inflammatory Syndrome in Children - United States, March-July 2020. *MMWR Morb Mortal Wkly Rep.* 2020;69(32):1074-80.
5. Dergun M, Kao A, Hauger SB, Newburger JW, Burns JC. Familial occurrence of Kawasaki syndrome in North America. *Arch Pediatr Adolesc Med.* 2005;159(9):876-81.
6. Uehara R, Yashiro M, Nakamura Y, Yanagawa H. Clinical features of patients with Kawasaki disease whose parents had the same disease. *Arch Pediatr Adolesc Med.* 2004;158(12):1166-69.
7. Whittaker E, Bamford A, Kenny J, Kaforou M, Jones CE, Shah P, et al. Clinical Characteristics of 58 Children With a Pediatric Inflammatory Multisystem Syndrome Temporally Associated With SARS-CoV-2. *JAMA.* 2020;324(3):259-69.
8. WHO. Multisystem Inflammatory Syndrome in Children and Adolescents with COVID-19 2020 [Available from: <https://www.who.int/newsroom/commentaries/detail/multisystem-inflammatory-syndrome-in-children-and-adolescents-with-covid-19>].
9. Gottlieb M, Bridwell R, Ravera J, Long B. Multisystem inflammatory syndrome in children with COVID-19. *Am J Emerg Med.* 2021 Nov;49:148-152. doi: 10.1016/j.ajem.2021.05.076.
10. Dufort EM, Koumans EH, Chow EJ, Rosenthal EM, Muse A, Rowlands J, et al. Multisystem Inflammatory Syndrome in Children in New York State. *N Engl J Med.* 2020;383(4):347-58.
11. Mamishi S, Movahedi Z, Mohammadi M, Ziaee V, Khodabandeh M, Abdolsalehi MR, et al. Multisystem inflammatory syndrome associated with SARS-CoV-2 infection in 45 children: a first report from Iran. *Epidemiol Infect* [Internet]. 2020 2020/08//; 148:[e196 p.]. Available from: <http://europepmc.org/abstract/MED/32854812>
12. Son MBF, Friedman K. COVID-19: Multisystem inflammatory syndrome in children (MIS-C) clinical features, evaluation, and diagnosis. upToDate. Waltham.(Accessed on August 19, 2021); 2021.
13. Abuhammour W, Yavuz L, Jain R, Abu Hammour K, Al-Hammouri GF, El Naofal M, et al. Genetic and Clinical Characteristics of Patients in the Middle East With Multisystem Inflammatory Syndrome in Children. *JAMA Netw Open.* 2022;5(5):e2214985.
14. Abolhassani H, Landegren N, Bastard P, Materna M, Modaresi M, Du L, et al. Inherited IFNAR1 Deficiency in a Child with Both Critical COVID-19 Pneumonia and Multisystem Inflammatory Syndrome. *J Clin Immunol.* 2022;42(3):471-83.
15. Vagreicha A, Zhang M, Acharya S, Lozinsky S, Singer A, Levine C, et al. Hemophagocytic Lymphohistiocytosis Gene Variants in Multisystem Inflammatory Syndrome in Children. *Biology.* 2022; 11(3).
16. Chou J, Platt CD, Habiballah S, Nguyen AA, Elkins M, Weeks S, et al. Mechanisms underlying genetic susceptibility to multisystem inflammatory syndrome in children (MIS-C). *J Allergy Clin Immunol* 2021;148(3):732-38 e1.
17. arcía-Salido A, de Carlos Vicente JC, Belda Hofheinz S, Balcells Ramírez J, Slöcker Barrio M, Leóz Gordillo I, et al. Spanish Pediatric Intensive Care Society working group on SARS-CoV-2 infection. Severe manifestations of SARS-CoV-2 in children and adolescents: from COVID-19 pneumonia to multisystem inflammatory syndrome: a multicentre study in pediatric intensive care units in Spain. *Crit Care.* 2020 Nov 26;24(1):666.