

# An Observational Study on The Role of Magnetic Resonance Imaging in The Evaluation of Soft Tissue Tumors with Histopathological Correlation at Tertiary Care Centre

Sriramula Sripriya<sup>1</sup>, Tejaswini Mogalagunta<sup>1\*</sup>, Sunitha Bajaj<sup>2</sup>, Sudha Bindu T<sup>3</sup>, Madhavi T<sup>4</sup>

<sup>1</sup>MBBS, MD Radio-diagnosis, Junior resident at Department of Radio-diagnosis from Osmania Medical College, Hyderabad, India.

<sup>2</sup>MBBS, MD, DNB Radio-diagnosis, Professor and HOD at Department of Radio-diagnosis from Osmania Medical College, Hyderabad, India.

<sup>3</sup>MBBS, MD Radio-diagnosis, Professor at Department of Radio-diagnosis from Osmania Medical College, Hyderabad, India

<sup>4</sup>MBBS, MD Radio-diagnosis, Assistant Professor at Department of Radio-diagnosis from MNJ Institute of Oncology and Regional Cancer Centre, Hyderabad, India

\*Corresponding Author: Tejaswini Mogalagunta, MBBS, MD Radio-diagnosis, Junior resident at Department of Radio-diagnosis from Osmania Medical College, Hyderabad, India. Email: drtejaswinimg@gmail.com

Received 2024 July 20; Accepted 2024 August 31.

## Abstract

**Background:** The primary aim of this study is to evaluate the role of magnetic resonance imaging (MRI) in the assessment of soft tissue tumors with histopathological correlation at a tertiary care center.

**Methods:** An observational study was conducted on 75 patients (n = 75) in the Department of Radiodiagnosis over 18 months. The targeted population comprised patients who presented to the Radiodiagnosis Department for radiological imaging of soft tissue tumors.

**Results:** Out of 75 cases, 20% were found to have benign tumors, while 80% were found to have malignant tumors. The most frequent benign tumor was fibromatosis, with n = 10 cases (13.33%), and the most common malignant tumor was synovial sarcoma, with n = 14 cases (18.66%). The benign age group ranged from 11 to 20 years. T2-weighted heterogeneous hyperintensity was noted more frequently in malignant lesions, demonstrating a high positive predictive value; that is, 83% of malignant tumors exhibited changes on diffusion-weighted imaging/ apparent diffusion coefficient (DWI/ADC). Low-grade malignant lesions showed no restrictions. Most benign lesions displayed restrictions, with a high positive predictive value of 98.14%, specificity of 93.33%, and sensitivity of 88.33%.

**Conclusions:** Soft tissue tumors can be detected and locally staged using MRI; thus, this technique has proven its value. Intralesional hemorrhage and calcification are two parameters that have been shown to have no substantial association with cancer. Due to its high sensitivity, MRI is a viable option for evaluating soft tissue tumors.

**Keywords:** MRI; Soft-Tissue Tumors; Radiology; Computed Tomography

## 1. Background

Soft tissues comprise a significant part of the human body; however, approximately 1% of all neoplasms are soft tissue tumors (STT), which are extremely uncommon. Benign tumors are far more common than malignant ones, with a ratio of approximately 100 to 1. Soft-tissue sarcomas (STS) can develop in various locations throughout the body (1).

Different types of STS include malignant fibrous histiocytoma, liposarcoma, fibrosarcoma, synovial sarcoma, malignant peripheral nerve sheath tumor (MPNST), leiomyosarcoma, rhabdomyosarcoma, clear cell sarcoma, epithelioid sarcoma, alveolar soft part sarcoma, angiosarcoma, spindle cell sarcoma, unclassified sarcomas, and undifferentiated soft-tissue sarcomas (2).

Radiologists routinely encounter soft-tissue lesions in clinical practice. Despite developments in imaging tech-

nology, it is still difficult to characterize these soft-tissue lesions (3). When evaluating soft tissue tumors, magnetic resonance (MR) imaging has emerged as a crucial cross-sectional imaging investigation. To evaluate soft tissue tumors, magnetic resonance imaging (MRI) is the study of choice due to its superiority over ultrasonography and computed tomography (CT) in characterizing tumor extent and connection to surrounding tissues (4). Magnetic resonance imaging can be used to narrow the differential diagnosis for lesions that display indeterminate characteristics and determine the diagnosis for the subset of determinate lesions that have typical clinical and imaging features (3).

The MRI plays a pivotal role in guiding surgical approaches by describing affected areas from healthy ones, distinguishing tumors from surrounding fat and mus-



cles, and identifying lesions about adjacent neurovascular bundles. Timely diagnosis of soft tissue tumors is crucial, as delays can exacerbate the prognosis of malignant cases, leading to local complications, increased surgical morbidity, and a higher risk of metastasis. With MRI's unparalleled precision, we ensure a seamless and effective approach to treatment, maximizing the chances of positive patient outcomes (5).

## 2. Objectives

Therefore, the primary aim of the study was to evaluate the role of MRI in the evaluation of soft tissue tumors with histopathological correlation at tertiary care centers.

## 3. Methods

In this study, a total of 75 patients were enrolled. The target group of the study consisted of patients who presented for imaging of soft tissue tumors. The study was conducted over 18 months in the radiodiagnosis department of a tertiary care center.

**Inclusion criteria:** Patients of all ages who presented with soft tissue swelling to the Surgery Department of Osmania General Hospital and MNJ Cancer Hospital.

**Exclusion criteria:** Patients with claustrophobia and swellings due to:

- Trauma
- Infective etiology
- Hernias
- Bone and joint disease
- Metastasis

- Bone malignancies infiltrating surrounding soft tissue

### 3.1. Methodology

Patients with soft tissue swelling who presented to the hospital for clinical evaluation had their participation in the study approved after obtaining their written consent. Patient information was recorded using a proforma, including the onset and progression of symptoms and the duration of the swelling. The hospital's 1.5 Tesla MRI machines were used to evaluate these individuals, and the scan results were documented. Features observed on MRI were measured and recorded, including tumor size, shape, margins, extent, signal intensity, signal homogeneity, enhancement pattern, appearance sequence, evidence of necrosis, and tumor extensions. A definitive diagnosis was reached based on the aforementioned criteria, and if surgical excision was recommended, a tissue sample was sent for histological analysis following the operation (treatment). The histopathological report was then correlated with the MRI diagnosis for confirmation. A non-soft-tissue tumor histopathological examination (HPE) diagnosis was not included.

## 4. Results

The present study comprised a total of 75 patients. Among the 75 cases, 42 (56%) were male and 33 (44%) female. Malignant lesions were most common in males (58.33%) and in the 21 - 30 and 41 - 50 age groups (23.33%). Benign lesions were more frequent in the 11 - 20 age group (26.66%) (Table 1).

**Table 1.** Gender and age Distribution a

Variables	Benign	Malignant	Total
<b>Gender</b>			
Male	7 (46.66)	35 (58.33)	42 (56)
Female	8 (53.33)	25 (41.66)	33 (44)
<b>Total</b>	15 (100)	60 (100)	75 (100)
<b>Age (y)</b>			
1 - 10	2 (13.33)	3 (5)	5 (6.66)
11 - 20	4 (26.66)	6 (10)	10 (13.33)
21 - 30	3 (20)	14 (23.33)	17 (22.66)
31 - 40	2 (13.33)	2 (3.33)	4 (5.33)
41 - 50	2 (13.33)	14 (23.33)	16 (21.33)
51 - 60	1 (6.66)	12 (20)	13 (17.33)
61 - 70	0 (0)	7 (11.66)	7 (9.33)
71 - 80	1 (6.66)	2 (3.33)	3 (4)
<b>Total</b>	15 (100)	60 (100)	75 (100)

<sup>a</sup> Values are expressed as No. (%).

Pain was the main symptom in malignant cases (93.5%), while swelling was more common in benign cases (80%). Other symptoms were more frequent in malignant cases

(31.60%), as noted in Figure 1. Additional symptoms observed included itching, burning sensation, weight loss, and headache.

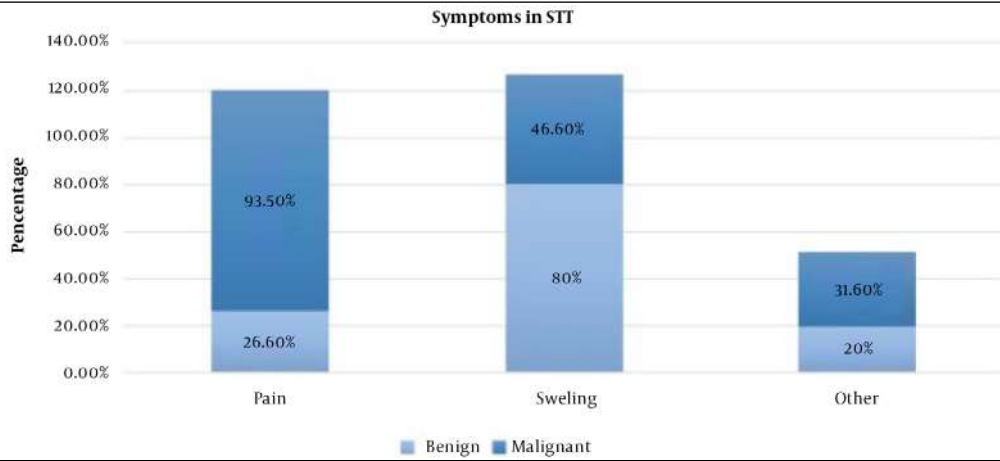


Figure 1. Shows the symptoms of soft tissue tumor (STT).

Figures 2 and 3 show that the distribution of malignant tumors was highest in synovial sarcoma (18.67%) and lowest in fibromyxoid sarcoma, leiomyosarcoma, and fibrosarcoma (1.33% each).

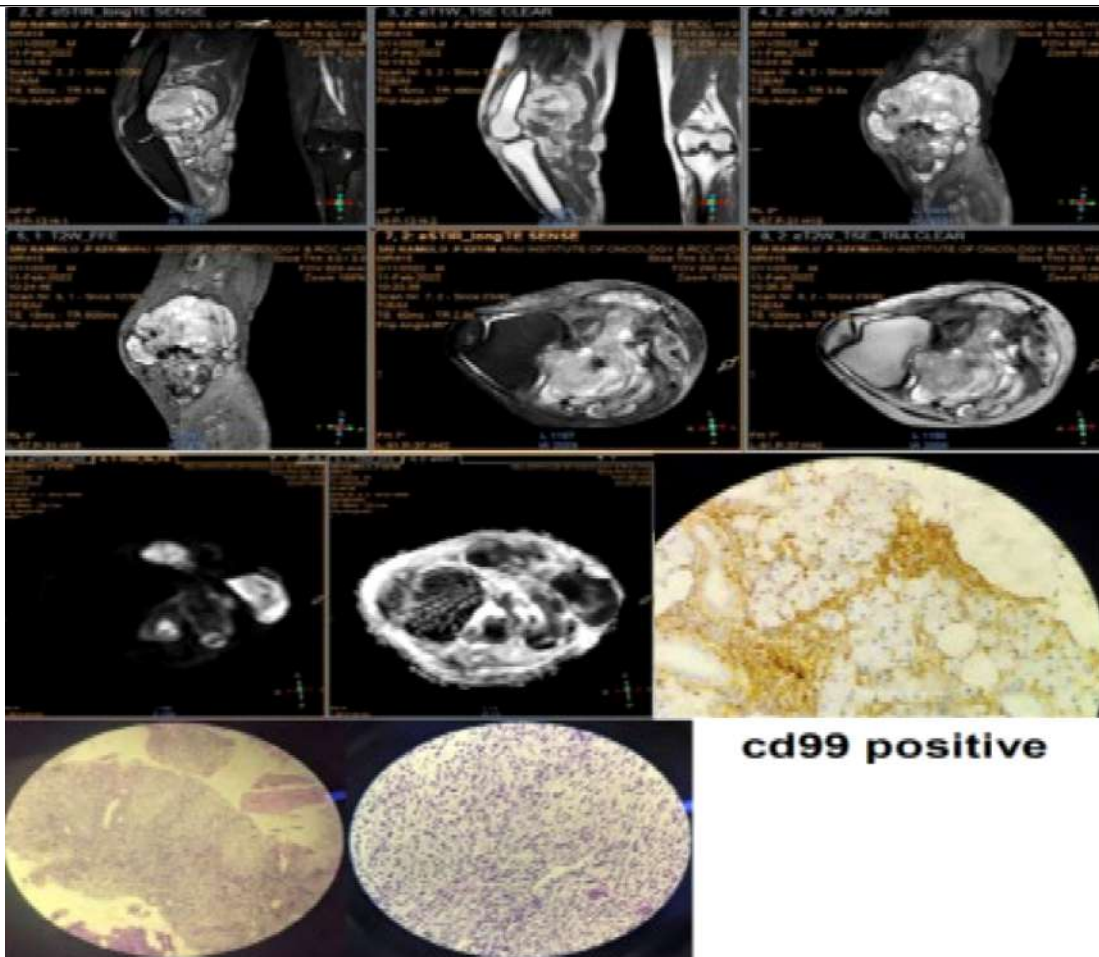


Figure 2. Synovial sarcoma showing on magnetic resonance imaging (MRI) 18 × 10 × 9 cm lobulated T1w heterogenous, T2w short tau inversion recovery (STIR) heterogeneously hyper intense lesion noted in subcutaneous, intermuscular planes over posterior aspect of right knee showing haemorrhages and calcifications. On histopathological examination (HPE) & IHC- synovial sarcoma.

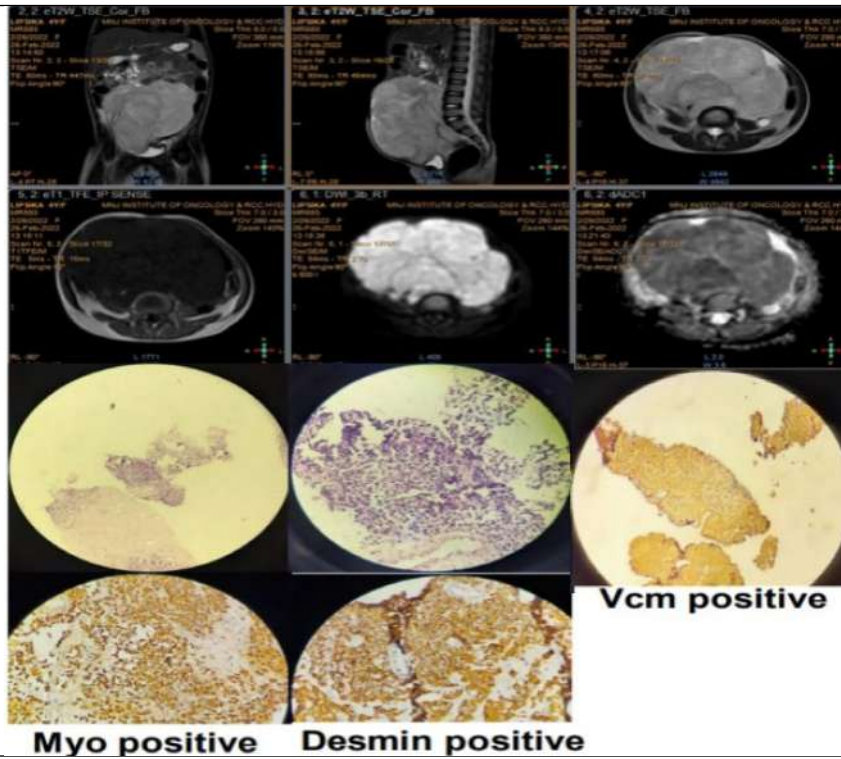


Figure 3. Rhabdomyosarcoma showing on magnetic resonance imaging (MRI) large lobulated T1w hypointense T2w, short tau inversion recovery (STIR) hyperintense lesion measuring 13 × 12 × 9 cm noted in peritoneal cavity showing restriction on diffusion-weighted imaging/apparent diffusion coefficient (DWI/ADC). On histopathological examination (HPE) & IHC - rhabdomyosarcoma.

Figures 4, 5, and 6 show that the distribution of benign other types accounted for 6.67% each. tumors was highest in fibromatosis (66.67%), while all

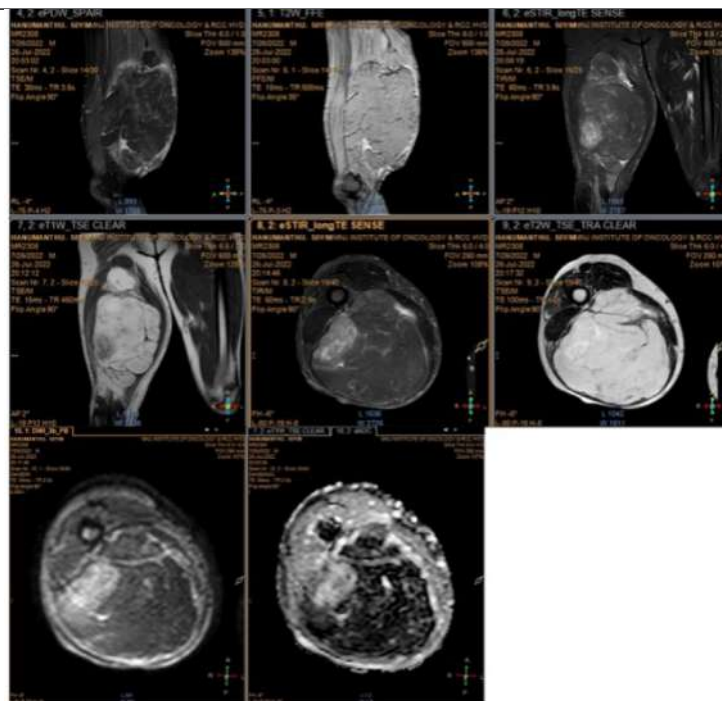


Figure 4. Atypical lipomatous tumor showing on magnetic resonance imaging (MRI) large lobulated heterogenous T1w, T2w hyperintense lesion, SPAIR/short tau inversion recovery (STIR) hypointense lesion measuring 14 × 25 × 13 cm noted over posterior aspect of right thigh. On histopathological examination (HPE) & IHC - atypical lipomatoustumor.



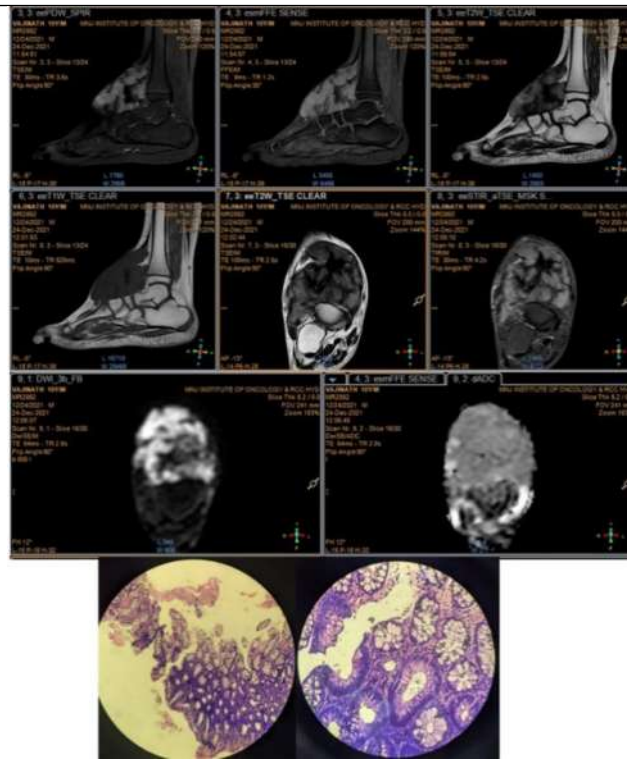


Figure 5. Benign fibromatosis showing on magnetic resonance imaging (MRI) 6 × 3 × 4 cm well defined T1w hypo, T2w, short tau inversion recovery (STIR) heterogeneously hyperintense lesion noted in subcutaneous, inter and intramuscular planes over dorsum of hind foot. On histopathological examination (HPE) it came out as spindle cell tumor. On IHC - fibromatosis.

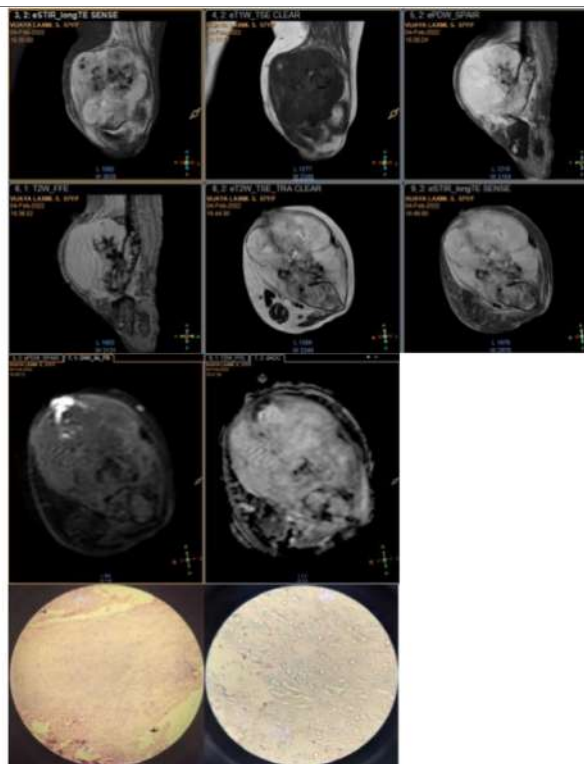


Figure 6. Chondrosarcoma showing on magnetic resonance imaging (MRI) large multilobulated heterogenous T1w hypointense T2w, short tau inversion recovery (STIR) hyperintense lesion noted arising from left hip region showing marrow infiltration and bone destruction into left femur. On histopathological examination (HPE) - chondrosarcoma.

The accuracy of T2w heterogeneous hyperintensity in distinguishing malignant from benign lesions showed a sensitivity of 73.30%, specificity of 40%, positive predictive value (PPV) of 83%, and negative predictive value (NPV) of 27.70%. The role of diffusion-weighted imaging/apparent

diffusion coefficient (DWI/ADC) in distinguishing between benign and malignant lesions demonstrated a sensitivity of 88.33%, specificity of 93.33%, PPV of 98.14%, and NPV of 66.66% (Table 2).

**Table 2.** Accuracy of T2w Heterogeneous Hyper Intensity and Diffusion-Weighted Imaging/Apparent Diffusion Co Efficient to Distinguish Malignant and Benign Lesions

Variables	Malignant (%)	Benign (%)
<b>T2w Heterogeneous Hyperintense</b>		
Yes	44 (73.33)	9 (60.00)
No	16 (26.67)	6 (40.00)
<b>Total</b>	<b>60 (100.00)</b>	<b>15 (100.00)</b>
<b>Sensitivity</b>		73.30%
<b>Specificity</b>		40%
<b>PPV</b>		83%
<b>NPV</b>		27.70%
<b>DWI/ADC</b>		
(+) True restriction; n = 54	53 (88.33)	1 (6.66)
(-) No restriction; n = 21	7 (11.60)	14 (93.33)
<b>Total, n = 75</b>	<b>60 (100)</b>	<b>15 (100)</b>
<b>Sensitivity</b>		88.33%
<b>Specificity</b>		93.33%
<b>PPV</b>		98.14%
<b>NPV</b>		66.66%

<sup>2</sup> Abbreviations: DWI/ADC, diffusion-weighted imaging/apparent diffusion coefficient; PPV, positive predictive value; NPV, negative predictive value.

The role of peritumoral edema in distinguishing malignant from benign lesions showed a sensitivity of 81.66%, specificity of 66.66%, PPV of 90.70%, and NPV of 47.60%. The

sensitivity of MRI diagnosis was 95%, with a specificity of 86%, PPV of 96.6%, and NPV of 81.25% (Table 3).

**Table 3.** Role of Peritumoral Edema to Distinguish Malignant and Benign Lesions and Accuracy of Magnetic Resonance Imaging to Distinguish Malignant and Benign Lesions

Variables	Histopathological Diagnosis		
	Malignant	Benign	Total
<b>MRI Diagnosis</b>			
<b>Malignant</b>	<b>49</b>	<b>5</b>	<b>54</b>
<b>Benign</b>	<b>11</b>	<b>10</b>	<b>21</b>
<b>Total</b>	<b>60</b>	<b>15</b>	<b>75</b>
<b>Sensitivity</b>		<b>95.00%</b>	
<b>Specificity</b>		<b>86.00%</b>	
<b>PPV</b>		<b>96.60%</b>	
<b>NPV</b>		<b>81.25%</b>	
<b>Peritumoral Edema</b>			
<b>Positive</b>	<b>49</b>	<b>5</b>	<b>54</b>
<b>Negative</b>	<b>11</b>	<b>10</b>	<b>21</b>
<b>Total</b>	<b>60</b>	<b>15</b>	<b>75</b>
<b>Sensitivity</b>		<b>81.66%</b>	
<b>Specificity</b>		<b>66.66%</b>	
<b>PPV</b>		<b>90.70%</b>	
<b>NPV</b>		<b>47.60%</b>	

<sup>2</sup> Abbreviations: MRI, magnetic resonance imaging; PPV, positive predictive value; NPV, negative predictive value.

The accuracy of margins in differentiating between benign and malignant lesions showed a sensitivity of 70%, specificity of 86.60%, PPV of 95.45%, and NPV of 41.90%. Margins were found to have a statistically significant association in predicting malignant lesions (P-value 0.0001), as determined by the chi-square test (15.89).

The distribution of STTs indicated that the lower limb was the most common site for both benign (53.33%) and malignant (56.66%) lesions. Larger lesions (> 8 cm) were more prevalent in both malignant (61.66%) and benign (53.33%) cases. Sensitivity and specificity for lesion size were 61.66% and 53.33%, respectively, with a PPV of 84% and an NPV of 25.80%.

Calcifications were observed in 12% of the total cases. Hemorrhages were present in 10.66% of cases overall, while necrosis was found in 10.66% of the total cases. Regarding extensions, bone destruction was detected in 12% of all cases, neurovascular invasion in 5.3%, and marrow infiltration in 5.3% of the total cases. Muscle infiltration was noted in 12% of the cases, regional lymph node involvement in 10.6%, and distant lung metastasis in 2.6% of the cases.

## 5. Discussion

In the present study, the most common age ranges for both malignant and benign lesions were between 21 - 30 and 41 - 50 years old. Benign lesions were more common in females, while malignant ones were more frequent in males. In contrast, Kransdorf and Murphey (6) reported the most prevalent age range for both benign and malignant cases to be between 16 and 25 years, though this differs from the findings of Sen et al. (3), who found the average age to be 20 years. The variance in the most prevalent age range may be attributed to differences in sample size and geographic dispersion.

In this study, patients with malignant lesions reported significantly higher levels of pain (93.3%) and swelling (46.6%) compared to those with benign lesions. The incidence of tumors in the lower extremities was approximately 56%. Lower limbs were also the most common site for both malignant (56.6%) and benign (53.3%) tumors. These results are consistent with previous research by Sen et al. (3) and Harish et al. (4), which also showed that lower limb injuries are the most common.

The intensity and homogeneity of the MR signal using various pulse sequences are frequently employed as independent factors in predicting malignancy. Although high signal intensity on T2w images is a sensitive metric, its lack of specificity is a limitation (5).

In the study conducted by Chen et al. (7), it was reported that the sensitivity for detecting malignant lesions with the presence of heterogeneous hyperintensity on T2w imaging was 73%, the specificity was 40%, the PPV was 83%, and the NPV was 28%. Similarly, a study by Sen et al. (3) recorded a sensitivity of 41.9%, specificity of 69.0%, PPV of 60%, and NPV of 52.0%. Additionally, Sen et al. (3) found 67% sensitivity, 50% specificity, 58% PPV, and 59% NPV in their research.

Datir et al. (8) also reported a sensitivity of 100% and a specificity of 50%.

T1-weighted scans showed 17% of benign tumors to be hypointense, 58% to be hyperintense, and 85% to be hyperintense on T2w imaging, as reported by Hermann et al. (9). On T1w images, 40% of malignant tumors were hyperintense, while on T2w images, 100% of the tumors showed this characteristic. The reported sensitivity was 72%, and the specificity was 87%. Consistent with these findings, the majority of lesions in the present study were hypointense to isointense on T1w, while practically all lesions were hyperintense on T2w.

The present research found that using DWI/ADC for the benign/malignant distinction yielded a sensitivity of 88%, specificity of 93%, PPV of 98%, and NPV of 66%. Studies by Pekcevik et al. (10) and Jeon et al. (11) demonstrated the usefulness of DWI/ADC in distinguishing between malignant and benign lesions.

A higher level of sensitivity (70%), specificity (87%), PPV (95%), and NPV (42%) indicates that tumor margins are accurate in distinguishing malignancy. Margins have been found to have a statistically significant association in predicting malignant lesions (P-value 0.0001), as determined by the chi-square test. Further research by Sen et al. (3) and similarly strong associations discovered by Chen et al. (7) and Datir et al. (8) support these findings.

Chen et al. (7) conducted a study to evaluate the role of osseous involvement in predicting malignancy, observing lower sensitivity (35.5%), poorer NPV (51.2%), but greater specificity (75%) and PPV (61%). In contrast, Daniel Jr III et al. (12) reported high sensitivity (83.3%), specificity (84%), PPV (83%), and NPV (84%). In the present study, 1 in 12 STTs revealed osseous involvement or bone degradation, ranging from 6.6% in benign lesions to 13.3% in malignant ones.

Rare, specific, but insensitive indicators of malignancy were identified by De Schepper (13), including involvement of nearby bones, extracompartmental distribution, and encasement of the neurovascular bundle. According to research by Crim et al. (14), neurovascular bundle involvement was found in 4% of benign tumors and 18% of malignant tumors. Berquist et al. (15) reported neurovascular bundle involvement in 78% of malignant tumors. In the study by Chen et al. (7), high sensitivity (73%) and a PPV of 60% were reported, but poor specificity (37%) and an NPV of 51%. However, Daniel Jr III et al. (12) observed better results with sensitivity (83%), specificity (88%), PPV (86%), and NPV (85%) compared to the previous studies.

The researchers suggested that pressure necrosis might explain the lone instance of bone damage detected in a benign lesion. Bone erosions were observed in 12% of all STTs. Only around 5% of tumors showed signs of marrow infiltration and neurovascular invasion. Two cases exhibited distant lung metastases. Muscle tissue infiltration was observed in 12% of patients, and lymph node deposits in regional lymph nodes were found in 10.5% of cases. The size criteria of > 5 cm and uneven borders had a sensitivity of 85%, as demonstrated by the research of Moulton et al. (16).

## 5.1. Conclusions

Based on the results of the present study, MRI was reported to be a reliable imaging method for detecting and locally staging soft-tissue tumors. The MRI offers several advantages, including its ability to identify the origin of a lesion, map its growth in relation to surrounding structures, and assess a tumor's operability by determining whether it has spread beyond its original compartment, such as involvement of osseous, neurovascular, or soft tissue structures.

Parameters such as size > 8 cm, T2w heterogeneous hyperintensity, restriction on DWI/ADC, osseous and neurovascular involvement, peritumoral edema, intralesional necrosis, and ill-defined margins were found to have greater sensitivity, specificity, and PPV for predicting malignancy. In contrast, intralesional hemorrhage and calcification were found to have no significant association with malignancy. Therefore, due to its high sensitivity in detecting soft tissue tumors, MRI remains the technique of choice for their evaluation.

However, it is important to note that when radiologic findings are unclear, MRI cannot reliably distinguish between benign and malignant tumors in all cases. In a select group of tumors, magnetic resonance imaging may be able to provide a definitive diagnosis. When a definitive diagnosis is not possible, a well-organized differential diagnosis can be established by integrating information on tumor occurrence based on site and age, along with relevant clinical history and radiologic findings.

### Acknowledgment

We gratefully acknowledge Neuron Institute of Applied Research for their generous help in editing and technical help.

**Authors' contributions:** 1. Dr. Sriramula Sripriya: Conceptualization, formal analysis, resources

2. Dr. Tejaswini Mogalagunta: Validation, Formal analysis

3. Dr. Sunitha Bajaj: Writing original Draft, Data curation, Methodology, resources

4. Dr. Sudha Bindu T: Formal analysis, Writing - Review

5. Dr. Madhavi T: Methodology, Formal analysis

**Conflict of Interests:** No competing interest was recorded

**Data Reproducibility:** not mentioned

**Ethical Approval:** Patients consent was taken.

**Funding/Support:** There is no funding for the research

**Informed Consent:** Patients with soft tissue swelling who presented to the hospital for clinical evaluation had their participation in the study approved after obtaining their written consent

## References

- Weiss SW, Goldblum JR. General considerations. *Enzinger and Weiss's soft tissue tumors*. Philadelphia, PA: Mosby; 2001. p. 1-19.
- Faizi NA, Thulkar S, Sharma R, Sharma S, Chandrashekhara S, Shukla NK, et al. Magnetic resonance imaging and positron emission tomography-computed tomography evaluation of soft tissue sarcoma with surgical and histopathological correlation. *Indian J Nucl Med*. 2012;**27**(4):213-20. [PubMed ID:24019649]. [PubMed Central ID:3759080]. <https://doi.org/10.4103/0972-3919.115390>.
- Sen J, Agarwal S, Singh S, Sen R, Goel S. Benign vs malignant soft tissue neoplasms: limitations of magnetic resonance imaging. *Indian J Cancer*. 2010;**47**(3):280-6. [PubMed ID:20587903]. <https://doi.org/10.4103/0019-509X.64725>.
- Harish S, Lee JC, Ahmad M, Saifuddin A. Soft tissue masses with "cyst-like" appearance on MR imaging: Distinction of benign and malignant lesions. *Eur Radiol*. 2006;**16**(12):2652-60. [PubMed ID:16670867]. <https://doi.org/10.1007/s00330-006-0267-5>.
- Marett-Nielsen K, Aggerholm-Pedersen N, Safwat A, Jorgensen PH, Hansen BH, Baerentzen S, et al. Prognostic factors for local recurrence and mortality in adult soft tissue sarcoma of the extremities and trunk wall: a cohort study of 922 consecutive patients. *Acta Orthop*. 2014;**85**(3):323-32. [PubMed ID:24694277]. [PubMed Central ID:4062802]. <https://doi.org/10.3109/17453674.2014.908341>.
- Kransdorf MJ, Murphey MD. Radiologic evaluation of soft-tissue masses: a current perspective. *AJR Am J Roentgenol*. 2000;**175**(3):575-87. [PubMed ID:10954433]. <https://doi.org/10.2214/ajr.175.3.1750575>.
- Chen CK, Wu HT, Chiou HJ, Wei CJ, Yen CH, Chang CY, et al. Differentiating benign and malignant soft tissue masses by magnetic resonance imaging: role of tissue component analysis. *J Chin Med Assoc*. 2009;**72**(4):194-201. [PubMed ID:19372075]. [https://doi.org/10.1016/S1726-4901\(09\)70053-X](https://doi.org/10.1016/S1726-4901(09)70053-X).
- Datir A, James SL, Ali K, Lee J, Ahmad M, Saifuddin A. MRI of soft-tissue masses: the relationship between lesion size, depth, and diagnosis. *Clin Radiol*. 2008;**63**(4):373-8; discussion 9-80. [PubMed ID:18325355]. <https://doi.org/10.1016/j.crad.2007.08.016>.
- Hermann G, Abdelwahab IF, Miller TT, Klein MJ, Lewis MM. Tumour and tumour-like conditions of the soft tissue: magnetic resonance imaging features differentiating benign from malignant masses. *Br J Radiol*. 1992;**65**(769):14-20. <https://doi.org/10.1259/0007-1285-65-769-14>.
- Pekcevik Y, Kahya MO, Kaya A. Characterization of Soft Tissue Tumors by Diffusion-Weighted Imaging. *Iran J Radiol*. 2015;**12**(3):e15478. [PubMed ID:26557269]. [PubMed Central ID:4632135]. <https://doi.org/10.5812/iranradiol.15478v2>.
- Jeon JY, Chung HW, Lee MH, Lee SH, Shin MJ. Usefulness of diffusion-weighted MR imaging for differentiating between benign and malignant superficial soft tissue tumours and tumour-like lesions. *Br J Radiol*. 2016;**89**(1060):20150929. [PubMed ID:26892266]. [PubMed Central ID:4846217]. <https://doi.org/10.1259/bjr.20150929>.
- Daniel Jr III A, Ullah E, Wahab S, Kumar Jr V. Relevance of MRI in prediction of malignancy of musculoskeletal system—a prospective evaluation. *BMC Musculoskelet Disord*. 2009;**10**:125. [PubMed ID:19811663]. [PubMed Central ID:2766372]. <https://doi.org/10.1186/1471-2474-10-125>.
- De Schepper AM. Grading and Characterization of Soft Tissue Tumors. In: De Schepper AM, Parizel PM, De Beuckeleer L, Vanhoenacker F, editors. *Imaging of Soft Tissue Tumors*. Berlin, Heidelberg: Springer; 2001. p. 123-41.
- Crim JR, Seeger LL, Yao L, Chandnani V, Eckardt JJ. Diagnosis of soft-tissue masses with MR imaging: can benign masses be differentiated from malignant ones? *Radiology*. 1992;**185**(2):581-6. [PubMed ID:1410377]. <https://doi.org/10.1148/radiology.185.2.1410377>.
- Berquist TH, Ehman RL, King BF, Hodgman CG, Ilstrup DM. Value of MR imaging in differentiating benign from malignant soft-tissue masses: study of 95 lesions. *AJR Am J Roentgenol*. 1990;**155**(6):1251-5. [PubMed ID:2122675]. <https://doi.org/10.2214/ajr.155.6.2122675>.
- Moulton JS, Blebea JS, Dunco DM, Braley SE, Bisset III GS, Emery KH. MR imaging of soft-tissue masses: diagnostic efficacy and value of distinguishing between benign and malignant lesions. *AJR Am J Roentgenol*. 1995;**164**(5):1191-9. [PubMed ID:7717231]. <https://doi.org/10.2214/ajr.164.5.7717231>.