

## CASE BASED LEARNING POINTS

DOI: <https://doi.org/10.18502/fem.v7i2.12774>

# Endometriosis as a rare cause of small bowel obstruction

Tooraj Zandbaf<sup>1</sup>, Mohammad Ebrahim Kalantari<sup>2</sup>, Soheil Ahmadyar<sup>3</sup>, Ali Esparham<sup>3\*</sup>

1. Department of General Surgery, Faculty of Medicine, Mashhad Medical Sciences, Islamic Azad University, Mashhad, Iran.

2. Surgical Oncology Research Center, Mashhad University of Medical Sciences, Mashhad, Iran.

3. Student Research Committee, Faculty of Medicine, Mashhad University of Medical Sciences, Mashhad, Iran.

\*Corresponding author: Ali Esparham; Email: [Esparhama962@mums.ac.ir](mailto:Esparhama962@mums.ac.ir)

Published online: 2023-04-04

Cite this article as: Zandbaf T, Kalantari ME, Ahmadyar S, Esparham A. Endometriosis as a rare cause of small bowel obstruction. *Front Emerg Med.* 2023;7(2):e21.

## 1. Case presentation

A 30-year-old married woman with a history of infertility was referred to the general surgery department with complaints of occasional and intermittent left lower abdominal and left inguinal pain. Abdominal examination was normal and there was no obvious bulging in the left inguinal region. Routine laboratory tests were normal. Abdominal and pelvic ultrasonography revealed a left inguinal hernia with a defect of 15 millimeters (mm) and did not report any other pathological points. The patient was a candidate for laparoscopic trans-abdominal preperitoneal (TAPP) inguinal hernia repair.

During the operation, pneumoperitoneum was performed through the umbilical region using a Veress needle, and after inserting a 10 mm umbilical port and exploring the abdomen, blood was seen in the pelvis. It was determined that the bleeding was from the mesentery of the small intestine (a known iatrogenic complication caused by Trocar or Veress needle). Two more 5 mm ports were inserted, the mesenteric bleeding was ligated using a ligature, and it was decided to continue the surgery laparoscopically. No obvious hernia was seen in the exploration of the inguinal area. After intra-abdominal blood suction, it was determined that there was a retroperitoneal hematoma in zone one. The patient's vital signs were still stable. After some patience, it became clear that the hematoma was expanding, so a decision was made to perform a laparotomy. Zone one was explored, and it was found that there was a perforation in front of the inferior vena cava, and there was heavy bleeding, so after controlling the proximal and distal vein, the perforation site was repaired using Prolen threads.

In pelvic exploration, there was extensive adhesion in the region of the ovaries, fallopian tubes, and uterus, but there was no mass in the ovaries. Full abdominal exploration was performed. There was a mass in the small intestine 15 centimeters (cm) from the ileocecal valve, which caused an almost complete obstruction (Figure 1). Considering the patient's stable vital signs, a decision was made to resect the mass, and anastomose of the small intestine. At the end of the surgery and after washing the abdomen, the opened peritoneum was repaired on the vein, and two drains were placed in the pelvis.

On the third day of surgery and after bowel habits returned, a liquid diet was started. On the fifth day, the patient had a good general condition, so the drains were removed and she was discharged. The histopathology examination of the small intestine mass showed endometriosis. The patient was referred to a gynecologist for consultation and treatment.

## 2. Learning points

Endometriosis is referred to the existence of endometrial glands and stroma outside the uterine cavity. It is a chronic inflammatory disorder caused by estrogen, which affects women during their reproductive cycle and may lead to pelvic pain and infertility.

Endometriosis appears to have a 5% prevalence, with a peak

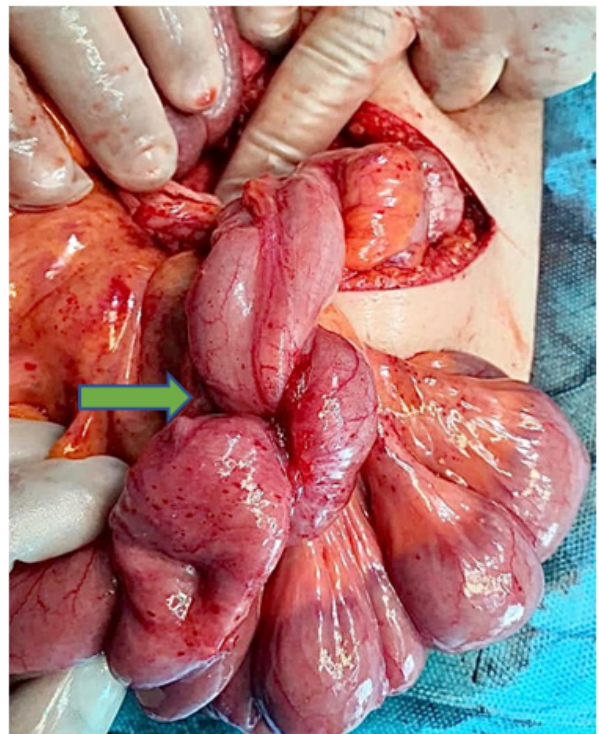


Figure 1 Mass in the small intestine (arrow)

between the ages of 25 and 35. The condition appears to be expected in adolescent women suffering from chronic pelvic pain. Numerous theories have been proposed regarding its etiology and pathogenesis including: the retrograde menstrual blood flow (regurgitation theory); endometrial tissue spreading through blood or lymphatic vessels (metastatic theory); coelomic epithelium transforming into endometrial tissue (metaplastic theory); bone marrow stem cells differentiating into endometrial tissue at heterotopic anatomical sites (current stem cell theory) (1,2).

Endometriotic locations might be intra or extraperitoneal. The most frequent intraperitoneal sites include ovaries (30%), uterosacral and large ligaments (18%–24%), and fallopian tubes (20%). However, there are other sites that each of them comprise less than 1% of the reported endometriosis such as navel, round ligament, inguinal hernia sac, pelvic peritoneum, pouch of Douglas, gastrointestinal tract, vagina and recto-vaginal septum, and abdominal scars following caesarian section or other gynecological surgeries (3). Intestinal endometriosis accounts for 3%–37% of all endometrioses; of these, 50%–90% involve the rectosigmoid portion and 2%–16% affect the small intestine area. Small intestinal obstruction caused by endometriosis is uncommon and some studies have shown that the rate of intestinal endometriosis causing obstruction is only 1% (4).

Although bowel endometriosis can be completely asymptomatic, it can also cause mass formation, rectal pain, nausea and vomiting, colicky abdominal pain and, in rare cases, intestinal obstruction. Endometriosis of the bowel often manifests as a solitary nodule with a diameter higher than 1 cm, invading the bowel's muscular layer and adjacent structures. Clinical symptoms, physical examination, biological testing, and imaging modalities are all non-specific in diagnosing endometriosis, hence, endometriosis should be ruled out in young female patients with chronic abdominal discomfort (5).

Because of clinical similarities to other causes of small intestinal obstruction, such as inflammatory bowel disease, irritable bowel syndrome, infectious and ischemic colitis, and cancer, the preoperative diagnosis remains challenging. With the local invasion and fast growth, intestinal endometriosis can mimic adenocarcinoma. The results of radiological imaging may be ambiguous. As the disease does not affect the mucosa, endoscopy and barium enema are ineffective. On the other hand, magnetic resonance imaging appears to have a higher sensitivity. Laparoscopy is the gold standard and only histology can confirm the diagnosis (3).

Usually, endometriosis is managed with medication, and surgery is reserved for those in whom the initial conservative approach fails.

However, considering the difficulty of preoperative diagnosis, intestinal endometriosis is mainly treated via surgery (6). Endometriosis should be considered an uncommon cause of small intestinal obstruction in women of reproductive age. The lack of pathognomonic clinical and radiological signs

make preoperative diagnosis challenging. In women of reproductive age, however, a high level of suspicion is required (3). Because it is difficult to discriminate between intestinal endometriosis and bowel cancer intraoperatively, oncological resection should be undertaken (4). Close follow-up is still required since the prognosis of intestinal endometriosis with lymph node involvement, is unknown (6).

### 3. Declarations

#### 3.1. Acknowledgement

The authors would like to express their profound gratitude to medical personnel involved in the treatment of this patient in Imam Zaman Hospital.

#### 3.2. Authors' contribution

The authors meet the four criteria for authorship based on the recommendations of the International Committee of Medical Journal Editors (ICMJE).

#### 3.3. Conflict of interest

All authors have declared that they have no conflict of interests.

#### 3.4. Funding

None.

#### 3.5. Consent for publication

The patient's written consent was obtained for the publication of this article.

### References

- Vercellini P, Viganò P, Somigliana E, Fedele L. Endometriosis: pathogenesis and treatment. *Nat Rev Endocrinol.* 2014;10(5):261–75.
- Zepeda MR, Win SK. A rare case of endometriosis of the small bowel. *Case Rep Pathol.* 2021;2021:6676855.
- Sali PA, Yadav KS, Desai GS, Bhole BP, George A, Parikh SS, et al. Small bowel obstruction due to an endometriotic ileal stricture with associated appendiceal endometriosis: a case report and systematic review of the literature. *Int J Surg Case Rep.* 2016;23:163–8.
- Kobayashi K, Yamadera M, Takeo H, Murayama M. Small bowel obstruction caused by appendiceal and ileal endometriosis: a case report. *J Surg Case Rep.* 2022;2022(6):rjac282.
- Dhannoon A, Bajwa A, Kunna M, Canney A, Nugent E. Beyond borders: a case report of small bowel obstruction secondary to undiagnosed florid endometriosis. *Int J Surg Case Rep.* 2022;93:106994.
- Koyama R, Aiyama T, Yokoyama R, Nakano S. Small bowel obstruction caused by ileal endometriosis with appendiceal and lymph node involvement treated with single-

incision laparoscopic surgery: a case report and review of the literature. *Am J Case Rep.* 2021;22: e930141.