

## CASE REPORT

DOI: <https://doi.org/10.18502/fem.v7i1.11699>

# Removing a pin from the urethra of a 14-year-old male patient: a case report

Adem Tunçekin<sup>1,2\*</sup>, Mehmet Demir<sup>1</sup>, İsmail Yağmur<sup>1</sup>, Eyyup Sabri Pelit<sup>1</sup>, Bülent Katı<sup>1</sup>, Halil Çiftçi<sup>1</sup>

1. Urology Department, Faculty of Medicine, Harran University, Şanlıurfa, Turkey.

2. Urology Department, Şanlıurfa Training and Research Hospital, Şanlıurfa, Turkey.

\*Corresponding author: Adem Tunçekin; Email: [dr\\_adem65@hotmail.com](mailto:dr_adem65@hotmail.com)

Published online: 2022-12-31

**Abstract:** The diagnosis and treatment of foreign bodies in the urogenital system are difficult and it's rare in children; It may also cause secondary injuries. In this article, we present a 14-year-old male patient who was admitted to the emergency outpatient clinic with complaints of difficulty in voiding and dysuria. He was diagnosed with a pin in the urethra and treated using an endoscopic method. He was hospitalised for foreign body removal after he admitted in his anamnesis about insertion a pin into his urethra the day before his complaints started. A pin was seen in the urethra on the urethrocystoscopy, and was successfully removed. Since foreign body in the urogenital system is rare in children, it is necessary to suspect, in order to make the diagnosis. In most cases, endoscopic intervention is sufficient. Psychiatric consultation should be requested for the patients, especially for pediatrics.

**Keywords:** Foreign Bodies; Male; Natural Orifice Endoscopic Surgery; Pediatrics; Pin; Urethra

Cite this article as: Tunçekin A, Demir M, Yağmur İ, Sabri Pelit E, Katı B, Çiftçi H. Removing a pin from the urethra of a 14-year-old male patient: a case report. *Front Emerg Med.* 2023;7(1):e9.

## 1. Introduction

Although the presence of foreign bodies in the urogenital system is rare in children, the number of cases has been increasing in recent years. The diagnosis and management of foreign bodies involves some difficulties (1). Depending on the size, shape, and length of stay of foreign objects in the body, it can cause a wide variety of complications such as chronic infection, perforation, injury to neighbouring organs, petrification of the foreign body, urinary tract fistulas, and even cancer (2). Although the management of the cases varies according to the shape, size, location, and complication of the foreign body, endoscopic methods are usually sufficient (3). We aimed to present a pediatric patient who presented to the emergency department with complaint of dysuria, was diagnosed with a pin in the urethra, and treated using an endoscopic method.

## 2. Case presentation

A 14-year-old male patient was admitted to our emergency outpatient clinic with complaints of difficulty in voiding and dysuria. The first anamnesis obtained from the patient and his relatives was unremarkable. The abdominal and urogenital examinations were normal. Microscopic haematuria was detected in the complete urinalysis. A direct urinary system radiography was then taken of the patient. An opacity of approximately 2 millimetres (mm) was observed in the penile urethra localized on the graph (Figure 1A).

A lateral pelvic X-ray was also taken later. On the lateral

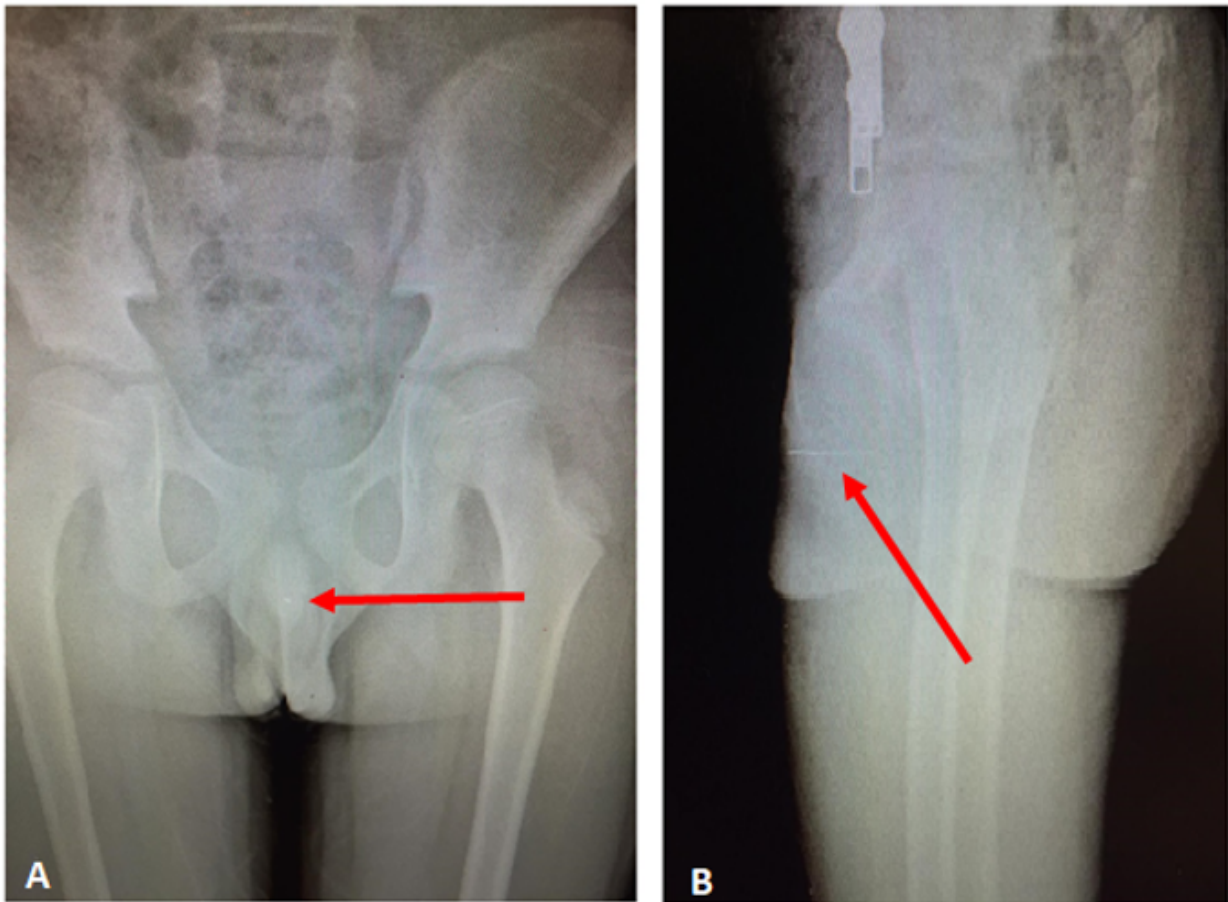
radiograph, a 3 centimetre (cm) linear radiopacity was observed (Figure 1B). It was thought that it might be a urethral foreign body. An anamnesis was taken again from the child without his family being present. He was hospitalized for a foreign body removal after he admitted that he had inserted a pin into his urethra the day before. The patient underwent urethrocystoscopy (11Fr Karl Storz, Germany). A pin was seen in the membranous urethra in the urethrocystoscopy (Figure 2). The pin was pushed into the bladder to avoid traumatizing the urethra. During the removal from the bladder, the foreign body was removed from the needle head with forceps, in order not to damage the urethra (Figure 3A-C). The patient's urethral catheter was removed after 24 hours. The 14-year-old, who was urinating comfortably, was given antibiotic and anti-inflammatory treatments and discharged with recommendation of a child psychiatrist counselling. No urethral stenosis was observed in the postoperative first week and second month control visits.

## 3. Discussion

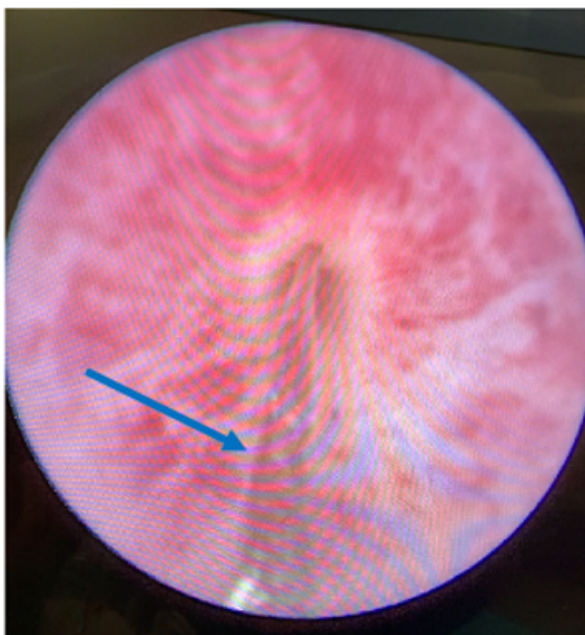
The presence of a foreign body in the urogenital system in children is a rare condition compared with adults. However, there has been an increase in such incidents. A child putting an object up his urethra may be an indicator of an underlying psychiatric disorder (4).

Cases in which foreign bodies such as pens, screws, wires, cables and needles were removed have been reported previously (5). In our case, a pin was detected in the urethra.

In the presence of a urethral foreign body, patients usually



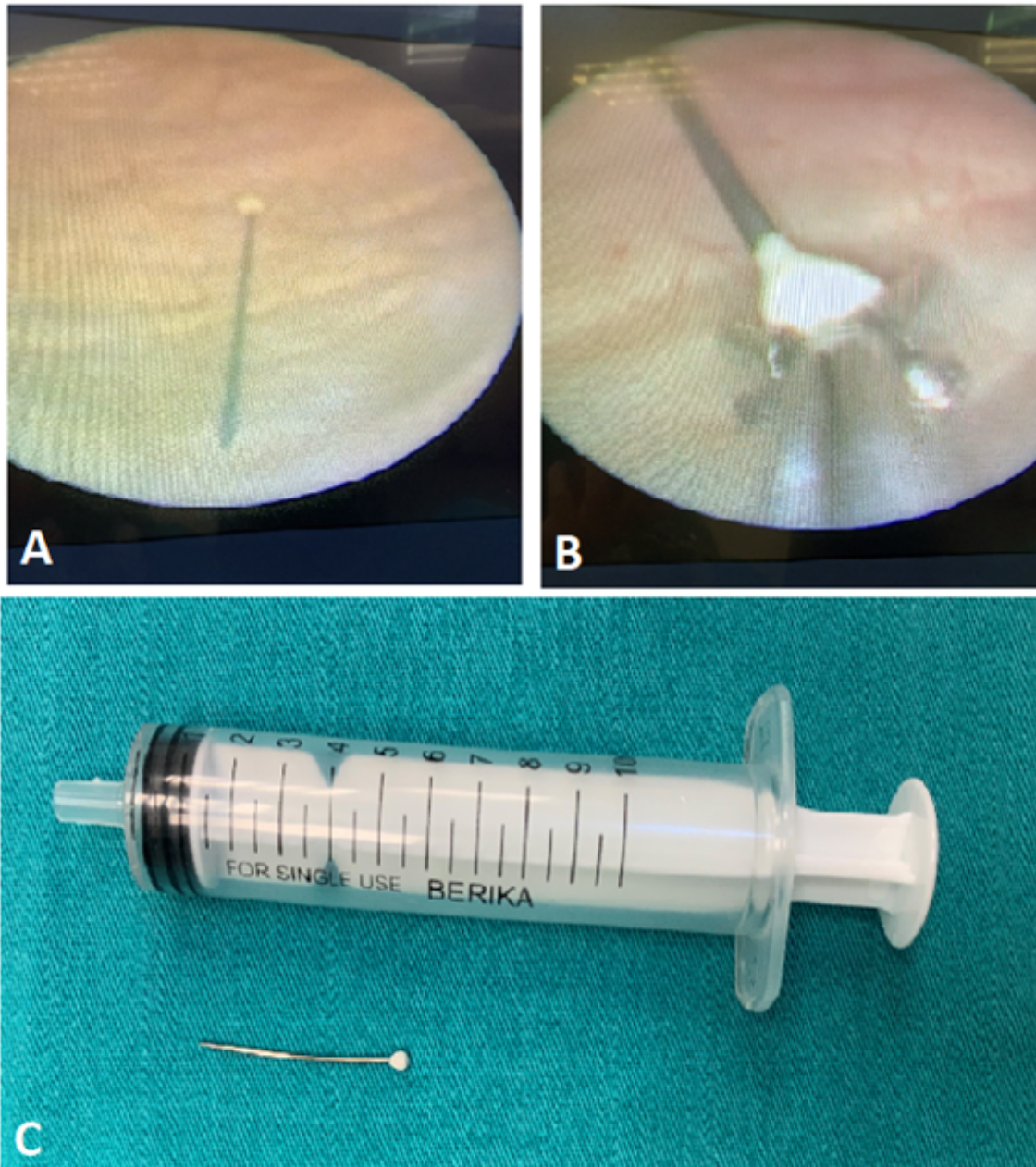
**Figure 1** A: Anteroposterior pelvis radiograph, 2 mm opacity (arrow); B: Lateral pelvis radiograph; 3 cm opacity (arrow).



**Figure 2** View of the pin (arrow) in the membranous urethra in the urethrocytoscopy.

present with lower urinary tract symptoms. Although frequency of voiding and burning in urination are among the most common causes of admission, haematuria, difficulty in voiding and acute urinary retention may also be seen. Since these symptoms can be seen in many diseases, it is not easy to diagnose the presence of a foreign body (6). The diagnosis is usually made through a detailed anamnesis, physical examination, X-ray, and ultrasonography, but computed tomography may be required on a rare occasion (7). Like in our case, pediatric patients may be afraid of their families and may not give information about the foreign body during the anamnesis. For this reason, especially in children, a careful anamnesis should be taken without judging the child, and if necessary, without his family being present.

A high rate of success in the removal of foreign bodies from the urogenital system is achieved through endoscopic methods. However, endoscopic treatments can be difficult in children due to the size of the urethra. While the success rate is higher in girls due to the short urethra, endoscopic methods may fail in boys due to the structure of the urethra, and open surgery may be required. In a study by Abdelhamid et al., a high rate of success was achieved with the endoscopic treatment in girls, while the success rates of open surgery were found to be higher in boys (8). In our case, the pin was suc-



**Figure 3** A: Image of a pin in the bladder in urethrocytoscopy; B: Removal of the pin by holding it from the head with forceps; C: Extracorporeal image of a successfully removed pin.

cessfully removed with no complications.

#### 4. Conclusion

Since the presence of a foreign body in the urogenital system is rare in children, it is necessary to first suspect it in order to make the diagnosis. Surgical intervention may vary according to the shape and size of the foreign bodies. In most cases, endoscopic intervention is sufficient. In order not to miss an underlying psychiatric disorder, a child psychiatric consultation should be requested for the patients.

#### 5. Declarations

##### 5.1. Acknowledgment

None.

##### 5.2. Authors' contribution

The authors meet all criteria for authorship based on the recommendations of the International Committee of Medical Journal Editors (ICMJE).

##### 5.3. Conflict of interest

None.

#### 5.4. Funding

None.

#### 5.5. Consent for publication

We obtained the patient's parents' consent for publishing the case with no identifiable personal information.

### References

1. He Y, Zhang W, Sun N, Feng G, Ni X, Song H. Experience of pediatric urogenital tract inserted objects: 10-year single-center study. *J of Pediatr Urol.* 2019;15(5), 554.e1-8.
2. Loeser A, Gerharz EW, Riedmiller H. Chronic perforation of the urinary bladder by self-inserted foreign body. *Int Urogynecol J Pelvic Floor Dysfunct.* 2007;18(6):689-90.
3. Naidu K, Chung A, Mulcahy M. An unusual urethral foreign body. *Int J Surg Case Rep.* 2013;4(11):1052-4.
4. Aliabadi H, Cass AS, Gleich P, Johnson CF. Self-inflicted foreign bodies involving lower urinary tract and male genitals. *Urology.* 1985;26(1):12-6.
5. Van Ophoven A, deKernion JB. Clinical management of foreign bodies of the genitourinary tract. *J Urol.* 2000;164(2):274-87.
6. Rafique M. Intravesical foreign bodies: review and current management strategies. *Urol J.* 2008; 5(4):223-31.
7. Bansal A, Yadav P, Kumar M, Sankhwar S, Purkait B, Jhanwar A, et al. Foreign bodies in the urinary bladder and their management: a single-centre experience from North India. *Int Neurourol J.* 2016;20(3):260-9.
8. Fath Elbab TK, Abdelhamid AM, Galal EM, Anwar AZ, Malek MA, Tawfiek ER. Management of intravesical self-inflicted sharp objects in children: 10-year single-center experience. *Pediatr Urol.* 2016;12(2):97.e1-5.