



# Mass-like presentation of primary angiitis of the central nervous system: A clinical note

Received: 03 Dec. 2023  
Accepted: 04 Feb. 2024

Faramarz Roohollahi<sup>1</sup>, Mohamad javad Abbaspour<sup>1</sup>, Mohamadreza Hajiabadi<sup>2,3</sup>, Hiva Saffar<sup>4</sup>, Morteza Faghih-Jouibari<sup>1</sup>, Mostafa Farzin<sup>5</sup>

<sup>1</sup> Neurological Surgery Department, Shariati Hospital Complex, Tehran University of Medical Sciences, Tehran, Iran

<sup>2</sup> Brain and Spinal Cord Injury Research Center, Shariati Hospital Complex, Tehran University of Medical Sciences, Tehran, Iran

<sup>3</sup> Department of Neurosurgery, School of Medicine, Tehran University of Medical Sciences, Tehran, Iran

<sup>4</sup> Pathology Department, Shariati Hospital Complex, Tehran University of Medical Sciences, Tehran, Iran

<sup>5</sup> Brain and Spinal Cord Injury Research Center, Neuroscience Institute, Tehran University of Medical Sciences, Tehran, Iran

## Keywords

Tuberculosis; Vasculitis; Central Nervous System

Primary angiitis of the central nervous system (PACNS) is a rare condition. Middle-aged men are more likely to be affected by PACNS. The mean age of onset is 50 years.<sup>1</sup> About 5% of PACNS cases present as a mass lesion.<sup>2</sup> There is no specific lab data or clinical finding to confirm PACNS; therefore, biopsies are central to the diagnosis process.<sup>3</sup> There are limited data regarding the management and prognosis of mass-like PACNS.

A 24-year Afghan girl presented to our emergency department with complaints of headache, confusion, and left-side hemiparesis. She was a known case of type 1 diabetes mellitus (DM) and idiopathic thrombocytopenic purpura (ITP). There was no history of night sweats or weight loss. She had no fever and inflammatory markers were normal. The brain computed

tomography (CT) scan showed one lesion with significant edema in the right frontal and temporal lobes. The patient underwent a frontal craniotomy, and the frontal lesion was resected. After surgery, she was fully conscious, and her weakness improved. Despite initial improvement, the intensity and duration of her headaches gradually increased. Pathologic findings were not conclusive and main pathologic finding was necrosis. As the patient was deteriorating and there was a suspicious history of tuberculosis (TB) contact, and the purified protein derivative (PPD) skin test was positive, we decided to start anti-TB treatment after consulting the infectious specialist.

**How to cite this article:** Roohollahi F, Abbaspour M, Hajiabadi M, Saffar H, Faghih-Jouibari M, Farzin M. Mass-like presentation of primary angiitis of the central nervous system: A clinical note. *Curr J Neurol* 2024; 23(2): 131-3.

She improved clinically and discharged but anti-TB treatment continued. She remained in stable condition. After six months, she stopped taking her medications without informing us.

Four months after partial TB treatment, the patient was readmitted with confusion, seizure, and hemiparesis. The brain magnetic resonance imaging (MRI) revealed a lesion with extensive peripheral edema in the right frontal and temporal lobes with mass effect and midline shift (Figure 1A, 1B).

PACNS diagnosis was confirmed. We started high-dose methyl-prednisolone for five days. The headache was relieved gradually. She was discharged with oral prednisolone. After 12 months of follow-up, she had no new symptoms. In the last brain MRI, the size of the lesion was reduced, and there was no new lesion (Figure 1C).

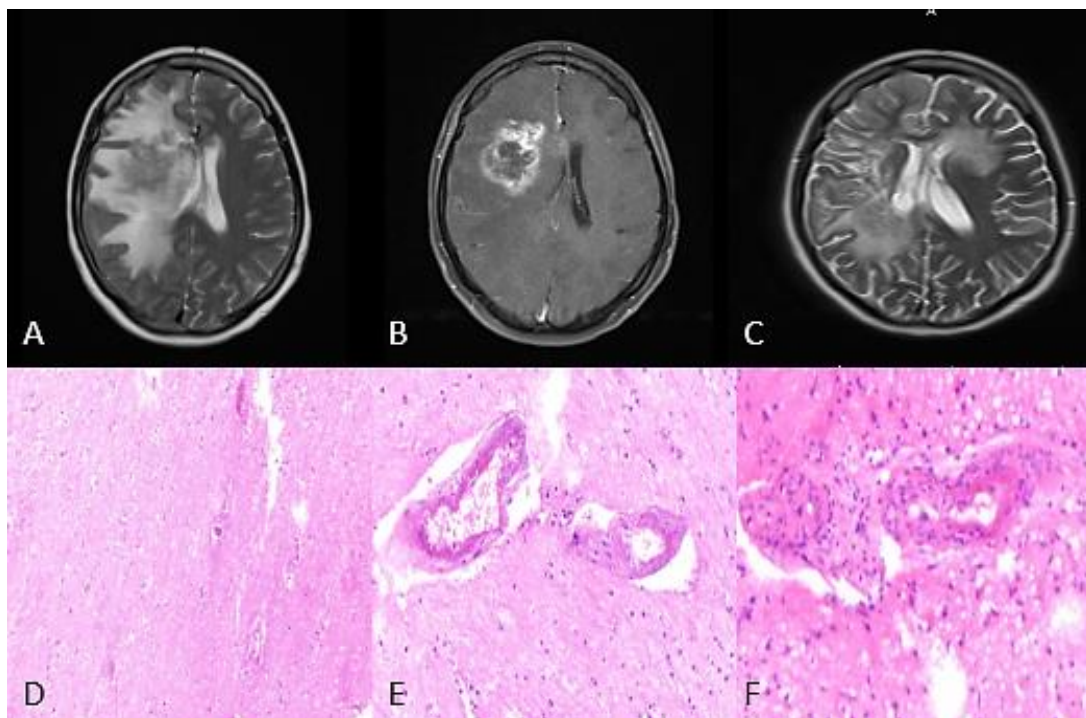
The patient underwent a right frontal decompressive craniotomy. A biopsy was taken from the frontal lesion. Full evaluations were done to exclude systemic vasculitis, infection, and inflammatory etiologies. TB-polymerase chain reaction (TB-PCR) was negative. The pathology exam showed small and medium-sized vessels involvement with the proliferation of the intimal

layer, thickening of the medial layer, inflammatory cell infiltration, and deposition of fibrinous material. Findings were consistent with “vasculitis” (Figure 1D-F).

An infectious angiitis that can mimic PACNS, especially in developing countries, is central nervous system (CNS) vasculitis secondary to TB. One percent of patients with TB exhibit CNS vasculitis symptoms. It is usually secondary to TB meningitis which affects basal cisterns in the brain.<sup>4</sup> Although there were clues (history of DM and TB contact) in favor of TB infection in our case, negative TB-PCR and the second biopsy result excluded TB-related CNS vasculitis.

Constitutional symptoms are not common in PACNS, despite systemic vasculitis.<sup>3</sup> Tumor-like presentation in PACNS is not common. About 5% of cases present as mass lesions.<sup>2</sup> Headache, encephalopathy, and atypical recurrent symptoms are the three main presentations of PACNS.<sup>5</sup>

No single specific factor in clinical evaluations or imaging studies confirms PACNS. It is essential to exclude tumors, infections, and systemic vasculitis, which can mimic mass-like PACNS. The biopsy is an essential part of the diagnosis process.<sup>3,6</sup>



**Figure 1.** A) Second admission pre-operation brain magnetic resonance imaging (MRI) (T2 sequence); B) Second admission pre-operation brain MRI (T1 with contrast sequence); C) Axial brain MRI after 1-year follow-up; D) Hematoxylin and eosin (H&E) stain, pale and vague vacuolated areas with karyolysis consistent with “acute infarct”; E) Deposition of smudgy amorphous fibrinous material within intimal layer; F) Proliferation of intimal layer and thickening of medial layer with inflammatory cell infiltration of vessel wall (vasculitis)

Early diagnosis and treatment can improve outcomes. Steroids are the mainstay of treatment. Cyclophosphamide will be added in refractory cases. 12 to 18 months of treatment usually leads to disease control.<sup>7</sup>

Although we have a better understanding of the pathologic features of PACNS, but diagnosis and treatment approaches have not been improved enough over the past decade.<sup>8</sup>

Remission can be achieved in PACNS but early diagnosis is essential. PACNS can be seen in all age

groups. Presentations are varying and not specific. A biopsy is required for diagnosis, especially in mass-like presentation. Steroids are crucial for the control of symptoms.

#### Conflict of Interests

The authors declare no conflict of interest in this study.

#### Acknowledgments

None.

#### References

- Heldner MR, Jung S, El-Koussy M, Fischer U, Arnold M. Primary angiitis of the central nervous system. *Gefasschirurgie* 2019; 24(2): 135-43.
- Molloy ES, Singhal AB, Calabrese LH. Tumour-like mass lesion: An under-recognised presentation of primary angiitis of the central nervous system. *Ann Rheum Dis* 2008; 67(12): 1732-5.
- Hajj-Ali RA, Singhal AB, Benseler S, Molloy E, Calabrese LH. Primary angiitis of the CNS. *Lancet Neurol* 2011; 10(6): 561-72.
- Younger DS, Coyle PK. Central nervous system Vasculitis due to Infection. *Neurol Clin* 2019; 37(2): 441-63.
- Calabrese LH, Mallek JA. Primary angiitis of the central nervous system. Report of 8 new cases, review of the literature, and proposal for diagnostic criteria. *Medicine (Baltimore)* 1988; 67(1): 20-39.
- Harris KG, Tran DD, Sickels WJ, Cornell SH, Yuh WT. Diagnosing intracranial vasculitis: the roles of MR and angiography. *AJNR Am J Neuroradiol* 1994; 15(2): 317-30.
- Salvarani C, Brown RD, Jr., Calamia KT, Christianson TJ, Weigand SD, Miller DV, et al. Primary central nervous system vasculitis: Analysis of 101 patients. *Ann Neurol* 2007; 62(5): 442-51.
- Rice CM, Scolding NJ. The diagnosis of primary central nervous system vasculitis. *Pract Neurol* 2020; 20(2): 109-14.