



Podcast

Received: 11 Sep. 2023
Accepted: 10 Nov. 2023

Long-term subclinical severe hyperCKemia associated with a rare VPS13A gene mutation in an Iranian patient: Case report

Seyed Jalaeddin Hadei¹, Bardiya Ghaderi-Yazdi¹, Shahriar Nafissi^{1,2}

¹Department of Neurology, Shariati Hospital, Tehran University of Medical Sciences, Tehran, Iran

²Neuromuscular Research Center, Tehran University of Medical Sciences, Tehran, Iran

Keywords

VPS13A Protein Human; Genetic Testing; Chorea-Acanthocytosis; Neuromuscular Disease; Creatine Kinase; Movement Disorders

A 24-year-old man with very mild weakness of the lower extremities following intense exercise, since the age of 15, presented to us with no problem with his normal daytime activities nor any significant progression over time. In addition, he has not experienced any numbness, abnormal sensations, or hearing or vision changes. He also denied dropped eyelid, diplopia, difficulty swallowing, abnormal speech, and dyspnea. The patient complained that in the last 4 years, irregular and non-stereotyped movements around the mouth and eyebrows, which were controllable, have developed. The patient has been experiencing cognitive disorders since two years ago, including the inability to do several tasks. He did not report systemic manifestation, such as, weight loss, fever,

rash, arthralgia, and bladder dysfunction. His past medical history was otherwise unremarkable and according to parent reports, he had normal birth history. There was no other person in his family with similar symptoms. Parents were second-degree relatives.

On physical examination, he was found to have mild cognitive impairment as indicated by Mini-Mental State Examination (MMSE) 25/30 with impaired calculation and recall. The cranial nerve examination was unremarkable. Abnormal irregular choreiform movements were notable in facial muscles which the patient was able to stop for a while. Perioral dyskinesia and mild dysarthria were evident. The motor exam was otherwise unremarkable.

How to cite this article: Hadei SJ, Ghaderi-Yazdi B, Nafissi S. Long-term subclinical severe hyperCKemia associated with a rare VPS13A gene mutation in an Iranian patient: Case report. Curr J Neurol 2024; 23(1): 86-8.

Deep tendon reflexes were diminished. Sensory examination demonstrated normal pain, temperature, and touch sensation along with normal position and vibration. There were no anomalies in Romberg's test as well as in the cerebellar exam, gait, and stance.

Lab work revealed high levels of lactate dehydrogenase (LDH) (1017 IU/l, normal value: 105-331 IU/l), creatine kinase (CK) (13690 mcg/l, normal value: 10-12 mcg/l), aldolase (210 U/l, normal range: 1.0-7.5 U/l), aspartate transaminase (AST) (110 U/l, normal value: 10-40 U/l), and alanine transaminase (ALT) (130 U/l, normal value: 10-40 U/l). Needle electromyography (EMG) was consistent with non-irritable myopathic process, and nerve conduction studies (NCSs) were normal. Brain magnetic resonance imaging (MRI) without contrast illustrated mild atrophy of caudate bilaterally (Figure 1). There was no evidence of acanthocytosis on the peripheral blood smear (PBS). Whole exome sequencing revealed a pathogenic homozygote mutation in VPS13 gene [Chr9 (GRCh37): g.79932615G>A].

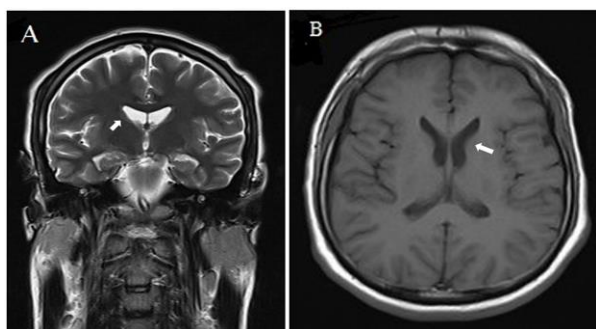


Figure 1. A) Coronal T2-weighted and B) axial T1-weighted magnetic resonance images showing bilateral atrophy of the caudate (arrows)

VPS13A (vacuolar protein sorting-associated protein 13A) is a known gene on chromosome 9q21 that encodes the protein chorein. Frameshift, deletion, insertion, splice site, duplication, and missense are known mutations of this gene. Mutation of VPS13A causes down-regulation of chorein's expression in neuronal tissue and red blood cells (RBCs). Chorea-acanthocytosis (ChAc) is the result of homozygote or compound heterozygote mutation in the VPS13A gene and chorein deficiency and is associated with movement disorder and the presence of acanthocytes in blood.¹⁻³

ChAc is a rare adult-onset progressive neurodegenerative disorder with diverse and heterogeneous manifestations. Characteristically,

there is a movement disorder including chorea, dystonia, orofacial dyskinesia, writing jitter, tics, and parkinsonism. Axonal sensory neuropathy, dilated cardiomyopathy, epilepsy, dysarthria, dysphagia, and neuropsychiatric symptoms [e.g., self-mutilation, mood disorders, obsessive-compulsive disorder (OCD), cognitive decline, and behavioral problems] are common in these patients.³⁻⁵

HyperCKemia without clinical myopathy is an important paraclinical finding. Acanthocyte counts might be variable between 5% and 50% and are sometimes absent until the later course of the disease. Therefore, although specific, it should not be a compulsory part of diagnosis.³ Brain MRI may show atrophy in the caudate nucleus, while impaired glucose metabolism in basal ganglia is demonstrable by fluorodeoxyglucose (FDG)-positron emission tomography (PET).⁴

The usual clinical and laboratory findings may not be enough to diagnose ChAc in some cases, especially within the first years of the disease. ChAc can manifest as a wide range of symptoms, myopathy, neuropathy, cognitive impairment, and movement disorders. It should also be mentioned that in the early years of the disease, symptoms may be very mild, and acanthocytosis cannot be seen in PBS. As part of the diagnosis process, in addition to a thorough history, physical examination, routine laboratory evaluations, and brain imaging, genetic testing is recommended in suspicious cases. An Iranian study by Karkheiran et al. identified three cases of this disease, confirmed by molecular western blotting in 2012.⁵

Our patient had a unique phenotype and presented as mild limb weakness after intense exercise and severe hyperCKemia (13690 mcg/l), with normal daily activities for the first few years. As far as we are aware, this level of hyperCKemia in VPS13A mutations has not been reported in the literature. The movement disorder appeared after several years, and even then, no acanthocytes were seen on the PBS. Furthermore, we reported a very rare mutation of VPS13A. It is worthy of notice that our case is the first reported case of VPS13A gene mutation amongst the Iranian population.

Conflict of Interests

The authors declare no conflict of interest in this study.

Acknowledgments

None.

References

1. Ueno S, Maruki Y, Nakamura M, Tomemori Y, Kamae K, Tanabe H, et al. The gene encoding a newly discovered protein, chorein, is mutated in chorea-acanthocytosis. *Nat Genet* 2001; 28(2): 121-2.
2. Walker RH, Schulz VP, Tikhonova IR, Mahajan MC, Mane S, Arroyo MM, et al. Genetic diagnosis of neuroacanthocytosis disorders using exome sequencing. *Mov Disord* 2012; 27(4): 539-43.
3. Walker RH. Untangling the thorns: Advances in the neuroacanthocytosis syndromes. *J Mov Disord* 2015; 8(2): 41-54.
4. Huang S, Zhang J, Tao M, Lv Y, Xu L, Liang Z. Two case reports of chorea-acanthocytosis and review of literature. *Eur J Med Res* 2022; 27(1): 22.
5. Karkheiran S, Bader B, Roohani M, Danek A, Shahidi GA. Chorea-acanthocytosis: report of three cases from Iran. *Arch Iran Med* 2012; 15(12): 780-2.