

A case of type II fucosidosis- diagnosed with neuroradiological and dysmorphological findings

Received: 17 June 2023
Accepted: 10 Aug. 2023

Sanjay M. Khaladkar, Satvik Dhirawani, Aastha Agarwal, Vijetha Chanabasanavar, Tejvir Singh

Department of Radiodiagnosis, Dr. D. Y. Patil Medical College and Research Centre, Pune, Maharashtra, India

Keywords

Pediatrics; Neurology; Lysosomal Storage Diseases;
Magnetic Resonance Imaging; Inborn Errors of
Metabolism

Fucosidosis is a rare autosomal recessive lysosomal storage disorder caused by the deficiency of alpha-L-fucosidase which results in accumulation of fucose rich glycoproteins and glycolipids within the lysosomes in skin, peripheral nerves, brain, heart, and other visceral organs. It is caused by biallelic pathogenic variants in FUCA1 gene localized on chromosome 1p36.11 which causes deficiency of alpha-L-fucosidase.¹ Manifestations of fucosidosis are progressive motor and mental deterioration, growth retardation, dysmorphic facies, skin changes such as angiokeratoma corporis diffusum, recurrent respiratory tract infections, seizures, and visceromegaly. It is categorized into two types. Type 1 presents early in infancy with rapid neurological deterioration and early death. Type 2 has a late onset and survives longer.² Here, we present a case of a 12-year-old boy brought with

history of neuroregression, coarse facies, and short stature with features typical of fucosidosis on magnetic resonance imaging (MRI) of the brain and lumbar spine who was later diagnosed with a definitive diagnosis of fucosidosis on whole exome sequencing.

A 12-year-old boy was brought by his parents with a history suggestive of neuroregression. He was second order born to a third-degree consanguineous marriage. He had recurrent episodes of fever and upper respiratory tract infections. He had normal development of milestones till 9 months of age. At age of 6 years, his mother noticed a change of gait with limb length discrepancy. At age of 10 years, the child had difficulty in sitting. Currently, the child can sit independently and speak only bisyllables with no sentence formation with cognitive delay.

How to cite this article: Khaladkar SM, Dhirawani S, Agarwal A, Chanabasanavar V, Singh T. A case of type II fucosidosis-diagnosed with neuroradiological and dysmorphological findings. Curr J Neurol 2023; 22(4): 265-7.

Clinically, patient had coarse facies with hepatomegaly and short stature. His hemogram, liver function, and renal function tests were normal. Urinary glycosaminoglycans (GAGs) were elevated (6.9). Two-dimensional (2D) echo revealed dilated left atrium and left ventricle with moderate mitral regurgitation.

Brain MRI (Figure 1) which was done in view of neurodegeneration showed changes of mild generalized cerebral atrophy with prominence of cortical sulci and ventricular system. Ill-defined hyperintensities on T2-weighted and fluid-attenuated inversion recovery (FLAIR) imaging were noted in bilateral periventricular white matter

and bilateral fronto-parieto-temporal subcortical white matter, appearing hyperintense on T1-weighted imaging (T1WI) without diffusion restriction on diffusion-weighted imaging (DWI). Areas of marked T2 hypointensity were noted in bilateral globus pallidus, substantia nigra, and red nucleus showing signal dropout on magnitude sequence of susceptibility-weighted images (SWI) and appearing bright on phase images. Whole spine MRI screening with T2-weighted imaging (T2WI) (Figure 1) was done which showed platyspondyly with anterior beaking at L3-L5 vertebral levels, biconcave-shaped vertebrae from D12 to L3 levels, and hypoplastic odontoid process.

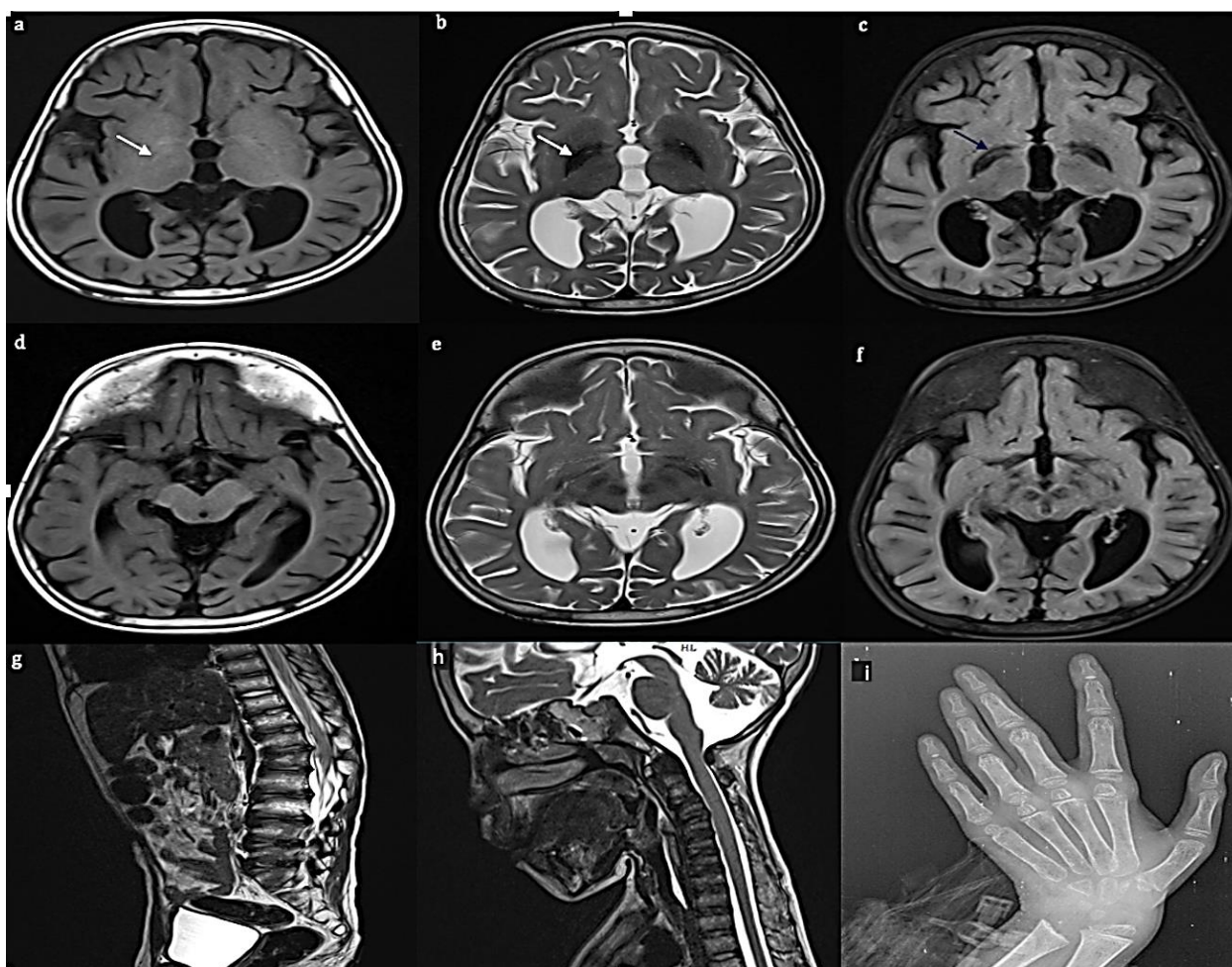


Figure 1. Axial brain T1 magnetic resonance imaging (MRI) (a), T2 (b), and fluid-attenuated inversion recovery (FLAIR) (c) images at the level of basal ganglia showing bilateral globus pallidus appearing hyperintense on T1-weighted imaging (T1WI), markedly hypointense on T2-weighted imaging (T2WI) (marked by white arrow) and FLAIR. There is curvilinear hyperintensity within basal ganglia on T2 and FLAIR images (marked by blue arrow). There is associated prominence of cortical sulci and ventricles which represents generalized cerebral atrophy; axial brain T1 MRI (d), T2 (e), and FLAIR (f) images at the level of mid brain showing substantia nigra and red nuclei appearing hypointense on T2WI and FLAIR (marked by white arrow); sagittal dorsolumbar spine T2 MRI (g) image showing platyspondyly with anterior beaking at L3-L5 vertebral levels; sagittal cervical spine T2 MRI (h) image showing reduced vertebral body heights of C3 to C7 vertebrae with hypoplastic odontoid process; posteroanterior (PA) view of wrist radiograph (i) showing delayed ossification of carpal bones and mild proximal tapering of metacarpals

In view of these findings, the possibility of mucopolysaccharidosis/metabolic disorders like lysosomal storage disorders was considered. Hand radiograph (Figure 1) showed delayed ossification of carpal bones and proximal tapering of metacarpals. Above-mentioned bony changes were suggestive of dysostosis multiplex. In view of the above clinical and radiological findings, differential diagnoses of mucopolysaccharidosis type IV, fucosidosis (lysosomal storage disease), and GM1 gangliosidosis were considered. Whole exome sequencing revealed FUCA1 gene located on the short arm of chromosome 1p36-p34 which helped us to arrive at the definitive diagnosis of fucosidosis.

Previously studied literature has shown that fucosidosis affects the skull, spine, pelvis, epiphysis of long tubular bones, and metacarpals and shows features collectively known as dysostosis multiplex. Lower thoracic and lumbar vertebrae show flattening with anterior beaking along with kyphosis or scoliosis.^{2,3} On neuroimaging, hypomyelination is observed in periventricular and subcortical white matter with resultant progressive, confluent, symmetric signal abnormalities. Grey matter changes are observed in globus pallidus manifested by marked hypointensity on T2WI and FLAIR and marked hyperintensity on T1WI. A curvilinear T2 hyperintense area within the lentiform nucleus can also be observed.³ Underlying mechanism of T2 hypointensity in globus pallidus is unclear. Proposed explanations include deposition of glycolipids and triglyceride

(TG), accumulation of calcifications or iron following sub-acute haemorrhage, and accumulation of paramagnetic substances like manganese caused by chronic liver dysfunction. The exact cause of signal abnormalities is unclear due to the lack of demonstration of calcification on computed tomography (CT) and the rarity of bilateral symmetrical haemorrhage in globus pallidus.⁴ Magnetic resonance (MR) spectroscopy shows a decrease in N-acetyl aspartate (NAA)/choline, increase in choline/creatinine, increase in myo-inositol/creatinine, and presence of lactate reflecting demyelination and astrocytosis. The presence of a spectral peak at 3.8-3.9 ppm can be seen due to the accumulation of macromolecules like oligosaccharides and glycolipids in fucosidosis.⁴

There is no complete cure for fucosidosis. Hematopoietic stem cell transplantation (HSCT) in the early stage of the disease may be useful and in advanced cases, symptomatic and supportive treatment is needed.⁵ This case demonstrates that a high index of suspicion is needed for diagnosis of fucosidosis and it should be suspected in presence of dysmorphological and radiological signs.

Conflict of Interests

The authors declare no conflict of interest in this study.

Acknowledgments

None.

References

1. Malatt C, Koning JL, Naheedy J. Skeletal and brain abnormalities in fucosidosis, a rare lysosomal storage disorder. *J Radiol Case Rep* 2015; 9(5): 30-8.
2. Provenzale JM, Barboriak DP, Sims K. Neuroradiologic findings in fucosidosis, a rare lysosomal storage disease. *AJNR Am J Neuroradiol* 1995; 16(4 Suppl): 809-13.
3. Wang L, Yang M, Hong S, Tang T, Zhuang J, Huang H. Fucosidosis in a Chinese boy: A case report and literature review. *J Int Med Res* 2020; 48(4): 300060520911269.
4. Oner AY, Cansu A, Akpek S, Serdaroglu A. Fucosidosis: MRI and MRS findings. *Pediatr Radiol* 2007; 37(10): 1050-2.
5. Kaur A, Dhaliwal AS, Raynes H, Naidich TP, Kaufman DM. Diagnosis and supportive management of fucosidosis: A case report. *Cureus* 2019; 11(11): e6139.