



# Left ventricular pseudoaneurysm as a late complication of incomplete surgical stab wound repair, a case report

Ahmadali khalili<sup>1</sup>, Naser Safaei<sup>1</sup>, Razieh Parizad<sup>1</sup>  
Amir Faravan<sup>1</sup>, Mehran Rahimi<sup>1,\*</sup>

<sup>1</sup> Cardiovascular Research Center, Tabriz University of Medical Sciences, Tabriz, Iran

**\* Corresponding Author:**

**Address:** Tabriz-University Street-Tabriz University of Medical Sciences. Shahid Madani Hospital, Tabriz, Iran. **Postal code:** 5166615573;  
**Tel:** +98 9143134453; **Email:** rahimimehran95@gmail.com

**Article Information:**

Received: 09 Apr 2023; Revised: 06 Aug 2023; Accepted: 19 Aug 2023

DOI: 10.18502/cbj.v3i1.13466

## Abstract

**Objectives:** Left ventricular pseudoaneurysm (LVP) is a rare but life-threatening condition caused by rupture of the free wall of the ventricle. The ventricular wall is surrounded by adherent pericardium and scar tissue, lacking myocardial tissue. In this case study, an 18-year-old man, experiencing syncope, shortness of breath, dizziness, and pleuritic chest pain (CP) was admitted to the emergency department. Five months earlier, he had a penetrating chest trauma that damaged the pericardium and ventricular wall and underwent a left thoracotomy. Transthoracic echocardiography (TTE) identified a large 10\*10 cm pseudoaneurysm in the apicolateral region of the ventricle. Considering the confirmed diagnosis of delayed left ventricular pseudo aneurysm, surgical intervention was deemed necessary. The patient went under general anesthesia, and cannulation of the artery and femoral vein and cardiopulmonary bypass (CPB) were performed. Open heart surgery was then performed through a midline sternotomy to excise the LVP and repair the ventricles. After transfer to the intensive care unit and subsequent extubation, the patient was transferred to the surgical ward and discharged in good condition.

**Conclusions:** This case report highlights the importance of timely diagnosis and appropriate treatment to save the lives of patients given the rapid spread observed in LVP cases.

**Keywords:** Left ventricular, Pseudoaneurysm, Penetrating trauma

## Introduction

Left ventricular pseudoaneurysm (LVP) refers to a rupture in the ventricular wall, which is enveloped by the pericardium (1). Clinical manifestations of LVP are non-specific and include chest pain (CP), dyspnea, congestive heart failure (CHF), and arrhythmias, which can delay diagnosis (2). LVPs have a strong tendency to grow rapidly, which increases the risks of rupture and acute fatal pericardial tamponade (3). Timely diagnosis and early surgical intervention are recommended for LVPs management. LVPs often occur after myocardial infarction (MI), heart

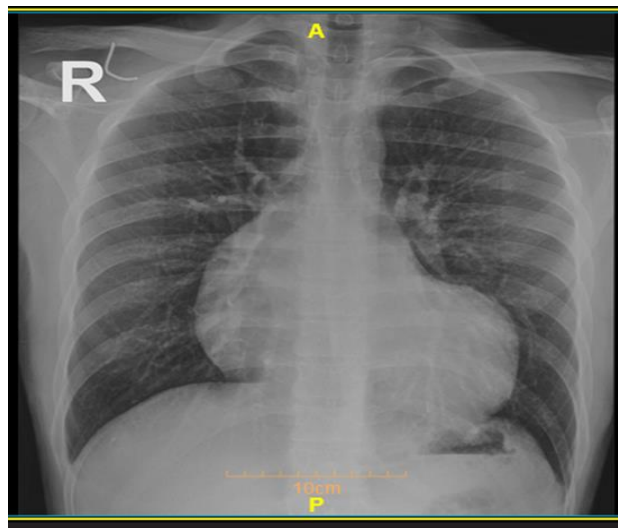
surgery, trauma, and endocarditis (3,4). In this study, we reported a case of delayed LVP following penetrating chest trauma.

## Case Report

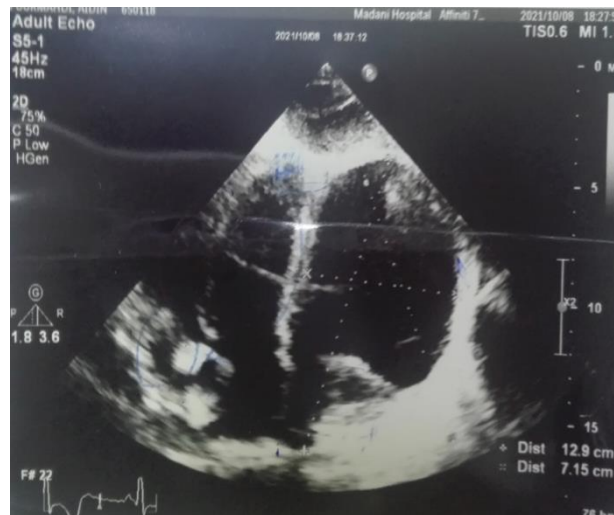In 2020, an 18-year-old man was admitted to the emergency department of Shahid Madani Cardiovascular, Medical and Research Center due to experiencing syncope, shortness of breath, dizziness, and pleuritic chest pain. He also reported a previous episode of syncope that had occurred approximately three months prior. Five months

earlier, he had suffered from penetrating chest trauma, resulting in damage to the pericardium and ventricular wall, which was subsequently treated via a left thoracotomy. During the examination, his blood pressure was measured at 116/69, heart rate (HR) at 80 beats per minute, respiratory rate (RR) at 22 breaths per minute, and temperature at 37.4 C. There were no significant differences in blood pressure between the two arms. The patient exhibited an oxygen saturation level of 94 percent while breathing ambient air. A cardiac physical

examination revealed a to-and-fro murmur and a palpable thrill, while other parts of the physical examination were unremarkable. Chest X-Ray indicated bulging or space-occupying lesion lateral to the left ventricle as shown in Figure 1. Transthoracic echocardiography (TTE) identified a large cavity (10 cm x 10 cm) in the left ventricular apicolateral wall, communicating with the left ventricle, along with a 25% left ventricular ejection fraction (LVEF) Figure 2.



**Figure1:** Bulging or space-occupying lesion lateral to the left ventricle



**Figure2:** Large a pseudoaneurysm in the left ventricular apicolateral region and low ejection fraction in echocardiography

After confirming the diagnosis of delayed-type LVP, we evaluated indications for surgical treatment. Considering the severe chest pain and

the risk of pseudoaneurysm rupture, no diagnostic tests such as Magnetic Resonance Imaging (MRI) or angiography were performed. The patient was

placed under general anesthesia in the operating room. Cardiopulmonary bypass (CPB) was successfully established by cannulating the right femoral artery and right femoral vein. Complete CPB was achieved, and a medial sternotomy was performed with inferior vena cava (IVC) and superior vena cava (SVC) cannulation. The pericardium and cardiac adhesions were opened, and myocardial protection was achieved through normothermic Custodial cardioplegia.

A 10 cm × 10 cm pseudoaneurysm was excised from the pericardium Figure 3. Upon opening the pseudoaneurysm, a clot was found inside a portion of it Figure 4. The pseudoaneurysm had a neck size of 4 cm x 4 cm which was attached to the left ventricle. Figure5. The aneurysm was excised, and the neck was repaired using pledget-supported interrupted 2-0 Ticron horizontal mattress sutures.

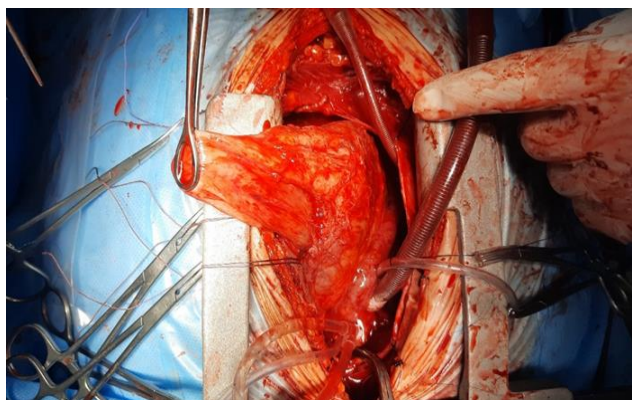
The patient was transferred to the intensive care unit (ICU) in stable condition, extubated after 24

hours, and then transferred to the ward within 72 hours. Prior to discharge, a trans-thoracic echocardiography showed a LVEF of 55 percent, confirming the correction of the aneurysm. Postoperative chest X-Ray Figure 6, also confirmed the successful aneurysm correction. The patient was discharged in good condition.

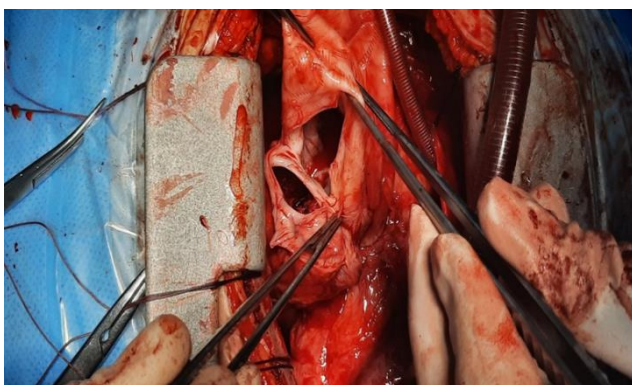
#### Follow-up

The patient was discharged in good health. After one month, the patient underwent a follow-up examination and was found to be in generally good condition.

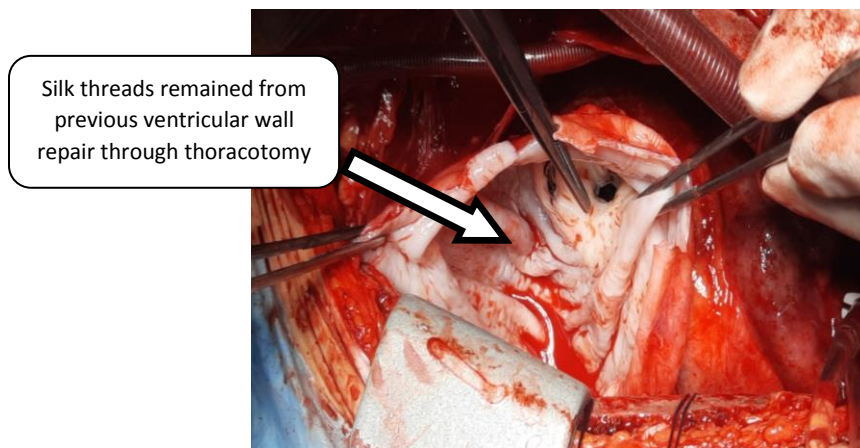
This study complied fully with the principles of the Declaration of Helsinki and the code of ethics of the National Medical Ethics Committee of the Tabriz Medical University (Tabriz, Iran) (IR.TBZMED.REC.1401.782). The information was recorded confidentially and at no additional cost to the patient.



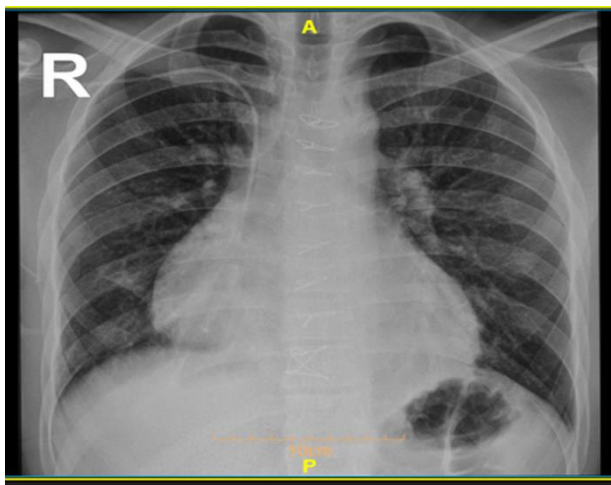
**Figure3:** Separation of pseudoaneurysm from the pericardium



**Figure4:** The pseudoaneurysm opened, part of which contained a clot



**Figure5:** Neck of the pseudoaneurysm associated with the left ventricle



**Figure6:** Correction of the aneurysm in a post- operative chest X-ray

### Discussion

The patient featured in this case report had penetrating cardiac trauma 5 months before developing a delayed pseudoaneurysm. He had undergone surgery for left ventricle repair. During his second admission, a large pseudoaneurysm was diagnosed, leading to a second cardiac surgery within six months. This case report serves as a reminder of the importance of careful and ongoing follow-up sessions for patients undergoing cardiothoracic surgery.

Studies have reported the incidence of 1 penetrating cardiac injury per 100,000 men yearly. The majority of penetrating heart injuries are attributed to accidents or violent actions, and a significant proportion of these cases result in fatality, with death rates ranging from 80% to 90% (5,6). However, patients who present at the hospital with normal vital signs and receive appropriate medical and surgical care have a

considerable chance of survival (7). The location of the heart within the thorax determines the extent and severity of damage caused by penetrating traumas. The ventricles, comprising the majority of the heart's structure, are commonly affected in approximately 80% of cases. Injury to the right atrium occurs in 24% of cases, while the left atrium is affected in only 3% of cases. Penetrating injuries have the potential to damage valves or papillary muscles, leading to complications such as shunts and lacerations of the coronary arteries. The rapid development of tamponade resulting from heart rupture often proves fatal (5,6).

With prompt surgical intervention, patients with severe penetrating heart injuries who present at the hospital with detectable vital signs can be saved. Penetration of the chest by low-velocity items, such as knives, is generally associated with a better prognosis than high-velocity weapons like

gunshots, which tend to cause more extensive damage. The resulting damage is due to a splaying effect, leading to severe tissue damage not only in the affected area but also in the surrounding tissues (8, 9). The majority of patients who present with unrecognized vital signs and undergo elective surgery survive the perioperative period. However, it is important to remember that neglected injury can lead to late complications postoperatively. Some of these conditions include atrial and ventricular septal defects, valvular lacerations, coronary vascular damage, and the development of ventricular pseudoaneurysms (10,11).

Ruptures, particularly in the posterior or lateral walls of the myocardium, can lead to the formation of a pseudoaneurysm (12). Unlike true left ventricular aneurysms, which involve the full thickness of the heart wall, left ventricular pseudoaneurysms occur when the free ventricular wall ruptures. This region is surrounded by adherent pericardium, scar tissue, or a clot, lacking myocardial tissue (13). Surgery is the definitive treatment for pseudoaneurysms, as leaving them untreated can lead to complications such as congestive heart failure, embolic events, or ventricular arrhythmias (14). The most concerning complication is the high risk of pseudoaneurysm rupture in these patients. While the risk of rupture in untreated pseudoaneurysms ranges from 31% to 45%, the mortality rate for patients undergoing surgery is 23%. Therefore, the surgical approach is crucial in preventing the progressive spread and rupture of pseudoaneurysms (7, 15).

Myocardial infarction accounts for more than 50% of pseudoaneurysm cases and is therefore the leading cause. The second most common cause is cardiothoracic surgeries (8). Additionally, trauma is responsible for approximately 7% of cases. While pseudoaneurysms often remain asymptomatic, patients commonly report symptoms such as chest pain, dyspnea, and hypotension (7). Pericardial frictions and cardiac murmurs are important signs that may be present during the examination. Some patients may exhibit sinus bradycardia or junctional rhythm on an electrocardiogram (9). Transthoracic echocardiography reveals a larger cavity diameter in pseudoaneurysms, along with turbulent flow by pulse Doppler at the neck or cavity, and increased signal intensity in the pericardial space on MRI

(15). MRI is a non-invasive method with 100% sensitivity and 83% specificity for distinguishing left ventricular pseudoaneurysms from true aneurysms (16). Echocardiography is the primary diagnostic modality, although other methods such as chest X-ray, computed tomography angiography, coronary angiography, or MRI are sometimes used. However, echocardiography remains the most common and accessible tool for diagnosing posterior left ventricular pseudoaneurysms (3). In this case, supplementary diagnostic tests such as MRI and angiography were not performed due to the severe chest pain and the potential risk of rupture.

### **Conclusion**

In conclusion, LVP in this case is a complication of incomplete heart repair. For cardiac stab wounds, a single stitch is done using felt or pledge support. In this case, the stitch should go almost through the entire thickness of the LV. Otherwise, the high pressure in the LV and multiple pulses will cause the wound to open from the endocardium and myocardium, leaking into the epicardium, and forming a pseudoaneurysm. In our patient, the incomplete repair of the ventricular incision caused a false aneurysm.

### **Informed consent**

The informed consent was obtained from the patient. A copy of the written consent is available for review by the Editor-in-Chief of this journal.

### **Data Availability Statement**

Data that support the findings of this study is available from the corresponding author upon reasonable request.

### **Funding**

The authors received no financial support for the research and/or authorship of this article.

### **Conflicts of Interest**

None declared.

### **Acknowledgments**

We would like to thank the patient for her cooperation in the study.

## References

1. Ashraf H, Sadatnaseri A, Aminorroaya A, et al. Left ventricular pseudoaneurysm as a complication of myocardial infarction; a case series and review of the literature. *Frontiers in Emergency Medicine*. 2021;5(3):e30.
2. Ho HH, Sinaga DA, Lee E, et al. Left ventricular pseudoaneurysm. *J Geriatr Cardiol*. 2017;14(1):78-80.
3. Meng X, Yang Y-K, Yang K-Q, et al. Clinical characteristics and outcomes of left ventricular pseudoaneurysm: A retrospective study in a single-center of China. *Medicine (Baltimore)*. 2017;96(18) :e6793.
4. Faustino M, Ranchordás S, Abecasis J, et al. Left ventricular pseudoaneurysm—a challenging diagnosis. *Rev Port Cardiol*. 2016;35(6):373.e1-6.
5. Tran H-V, Charles M, Garrett RC, et al. Ten-year trends in traumatic cardiac injury and outcomes: a trauma registry analysis. *Ann Thorac Surg*. 2020;110(3):844-848.
6. Hromalik Jr LR, Wall Jr MJ, Mattox KL, et al. Penetrating cardiac injury: a narrative review. *Mediastinum*. 2023;7:15.
7. Inayat F, Ghani AR, Riaz I, et al. Left Ventricular Pseudoaneurysm: An Overview of Diagnosis and Management. *J Investig Med High Impact Case Rep*. 2018;6:2324709618792025.
8. Frances C, Romero A, Grady D. Left ventricular pseudoaneurysm. *J Am Coll Cardiol*. 1998;32(3):557-61.
9. Bisoyi S, Dash AK, Nayak D, et al. Left ventricular pseudoaneurysm versus aneurysm a diagnosis dilemma. *Ann Card Anaesth*. 2016;19(1):169-72.
10. Makaryus AN, Manetta F, Goldner B, et al. Large left ventricular pseudoaneurysm presenting 25 years after penetrating chest trauma. *J Interv Cardiol*. 2005;18(3):193-200.
11. Tang AL, Inaba K, Branco BC, et al. Postdischarge complications after penetrating cardiac injury: a survivable injury with a high postdischarge complication rate. *Arch Surg*. 2011;146(9):1061-6.
12. Brown SL, Gropler RJ, Harris KM. Distinguishing left ventricular aneurysm from pseudoaneurysm: a review of the literature. *Chest*. 1997;111(5):1403-9.
13. Alapati L, Chitwood WR, Cahill J, et al. Left ventricular pseudoaneurysm: A case report and review of the literature. *World J Clin Cases*. 2014;2(4):90-3.
14. Toufan M, Khezerlou-Aghdam N, Masoumi S, et al. Batrial myxoma with a shared stalk: A case report. *J Tehran Heart Cent*. 2021;16(4):174-7.
15. Caldeira A, Albuquerque D, Coelho M, et al. Left Ventricular Pseudoaneurysm: Imagiologic and Intraoperative Images. *Circ Cardiovasc Imaging*. 2019;12(12):e009500.
16. Atik FA, Navia JL, Vega PR, et al. Surgical treatment of postinfarction left ventricular pseudoaneurysm. *Ann Thorac Surg*. 2007;83(2):526-31.